

**Are your MRI contrast agents cost-effective?**

Learn more about generic Gadolinium-Based Contrast Agents.



**FRESENIUS  
KABI**

caring for life

**AJNR**

**Neurometabolism of active neuropsychiatric  
lupus determined with proton MR  
spectroscopy.**

W L Sibbitt, Jr, L J Haseler, R R Griffey, S D Friedman and  
W M Brooks

This information is current as  
of April 17, 2024.

*AJNR Am J Neuroradiol* 1997, 18 (7) 1271-1277  
<http://www.ajnr.org/content/18/7/1271>

# Neurometabolism of Active Neuropsychiatric Lupus Determined with Proton MR Spectroscopy

Wilmer L. Sibbitt, Jr, Luke J. Haseler, Richard R. Griffey, Seth D. Friedman, and William M. Brooks

**PURPOSE:** To determine the neurometabolism of patients with active neuropsychiatric systemic lupus erythematosus (NPSLE) by using proton MR spectroscopy. **METHODS:** Thirty-six patients with SLE and eight control subjects were studied with proton MR spectroscopy to measure brain metabolites. Peaks from *N*-acetylaspartate (NAA), creatine (Cr), choline (Cho), and at 1.3 parts per million (ppm) lipid, macromolecules, and lactate were measured. Patients were classified as having major NPSLE (seizures, psychosis, major cognitive dysfunction, delirium, stroke, or coma) ( $n = 15$ ) or minor NPSLE (headache, minor affective disorder, or minor cognitive disorder) ( $n = 21$ ). Patients with major NPSLE were severely ill and hospitalized. **RESULTS:** SLE patients had lower NAA and increased metabolites at 1.3 ppm than did control subjects ( $\text{NAA/Cr}_{\text{SLE}} = 1.90 \pm 0.35$ ,  $\text{NAA/Cr}_{\text{Control}} = 2.16 \pm 0.26$ ;  $1.3 \text{ ppm/Cr}_{\text{SLE}} = 0.49 \pm 0.41$ ,  $1.3 \text{ ppm/Cr}_{\text{Control}} = 0.27 \pm 0.05$ ). NAA/Cr in patients with current or prior major NPSLE was lower than in patients without major NPSLE. Increased peaks at 1.3 ppm were present in all SLE subgroups, but particularly in patients with major NPSLE. These resonances were not evident at an echo time of 136, indicating that these signals were not lactate. **CONCLUSION:** Major NPSLE, past or present, is associated with decreased levels of NAA. Elevated peaks around 1.3 ppm do not represent lactate even in severely ill patients, indicating that global ischemia is not characteristic of NPSLE. Neurochemical markers determined by MR spectroscopy may be useful for determining activity and degree of brain injury in NPSLE.

**Index terms:** Lupus erythematosus; Magnetic resonance, spectroscopy

*AJNR Am J Neuroradiol* 18:1271–1277, August 1997

Neuropsychiatric systemic lupus erythematosus (NPSLE) is a complex disorder characterized by unpredictable and variable neurologic presentations, including stroke, psychiatric disturbances, affective disorders, cognitive dysfunction, headache, cranial neuropathies, pseudotumor cerebri, transverse myelitis, movement disorders, seizures, aseptic meningitis, and lupoid sclerosis (1–5). Short-term neu-

rologic dysfunction is common in NPSLE, although it is unclear whether this reversibility of function is due to disturbances in biochemical, neurotransmitter, or physiologic processes or is caused by severe, irreversible brain injury in which the acute functional disturbance diminishes as the focus of injury matures (6–13).

In proton magnetic resonance (MR) spectroscopic studies, normal-appearing brain tissue in patients with minor NPSLE is characterized by the loss of the neuronal marker *N*-acetylaspartate (NAA) and the presence of cerebral atrophy, findings suggestive of diffuse neuronal loss due to a potent neurotoxic process (14, 15). Normal-appearing tissues in major NPSLE often show subclinical evidence of acute injury that is not apparent on conventional MR images, such as reversible increases in the measured T2 signal of gray or white matter during acute neuropsychiatric episodes (14, 16). We hypothesized that neurochemical markers of acute brain in-

---

Received October 18, 1996; accepted after revision February 10, 1997.  
Supported by the State of New Mexico through a grant to the Center for Non-Invasive Diagnosis and by the Lupus Foundation of America.

From the Center for Non-Invasive Diagnosis (W.L.S., L.J.H., R.R.G., S.D.F., W.M.B.) and the Department of Internal Medicine (W.L.S., L.J.H.), University of New Mexico School of Medicine, Albuquerque.

Address reprint requests to Wilmer L. Sibbitt, Jr, MD, Department of Internal Medicine, Division of Rheumatology, University of New Mexico School of Medicine, Albuquerque, NM 87131.

*AJNR* 18:1271–1277, Aug 1997 0195-6108/97/1807–1271

© American Society of Neuroradiology

jury would be characteristic of major NPSLE. We also hypothesized that if ischemia were the major cause of NPSLE, markers of anaerobic metabolism (the presence of lactate) would be observed in these patients. We tested these hypotheses by studying patients during episodes of major NPSLE, including severely ill patients who had never before been examined with MR spectroscopy.

## Subjects and Methods

### *Patient Population*

Thirty-six patients with SLE and eight healthy control subjects were studied. All patients fulfilled the American College of Rheumatology criteria for SLE (17). Global SLE activity was assessed using the SLE disease activity index (18, 19). Current prednisone dose was recorded for all patients. NPSLE symptoms at the time of the MR study were classified by using a modification of the method of Carbotte and Denburg (5, 20, 21). Patients with acute stroke, neuropathy, movement disorder, transverse myelitis, seizure, meningitis, dementia, delirium, major cognitive defect, atypical psychosis, or major affective disorder were said to have active, or major, NPSLE. Patients with headaches, anxiety, mood swings, or minor cognitive complaints, such as difficulties in concentration, memory, and word finding, were identified as having inactive, or minor, NPSLE. Fifteen patients had major NPSLE (eight with seizures, five with major cognitive defects, and two with atypical psychosis) and 21 had minor NPSLE (12 with headaches and nine with minor cognitive complaints). In a secondary analysis, a chart review revealed that certain of the patients with minor NPSLE had suffered previous episodes of major NPSLE. Thus, the final classification included 13 patients with minor NPSLE who had had no prior episodes of major NPSLE, eight patients with minor NPSLE who had had prior episodes of major NPSLE, and 15 patients with major NPSLE. Patients with major NPSLE were severely ill, had very high SLE disease activity index scores, and were hospitalized. The research protocol was approved by our Human Research Review Committee, and all subjects or their legal representatives provided written consent. No patient received drugs for sedation.

### *MR Imaging*

All MR studies were obtained with a 1.5-T clinical imaging unit. The imaging protocol included a T1-weighted sagittal series and either a T1-weighted coronal series (500/16 [repetition time/echo time], 256 × 192 matrix, 4-mm-thick sections) or a T2-weighted axial series (2800/100,30, 256 × 192 matrix, 4-mm-thick sections) for localization of the spectroscopic acquisitions.

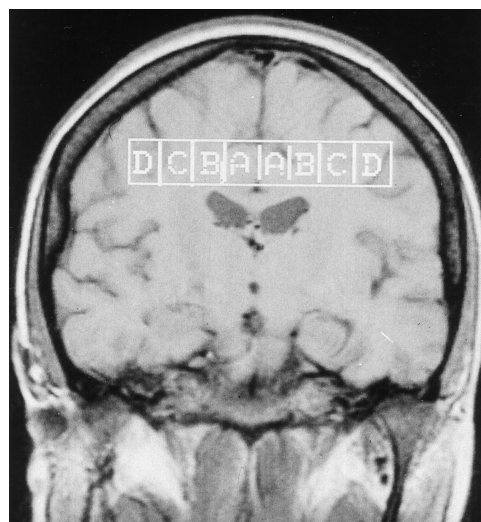


Fig 1. Prescription of spectroscopic imaging acquisition from a coronal image. Box shows location of the column of tissue voxels. Voxels marked B and C were used for analysis of white matter.

### *MR Spectroscopy*

In the first experiment, 23 patients with SLE and eight healthy control subjects were studied using a one-dimensional spectroscopic imaging sequence (stimulated-echo acquisition mode [STEAM], 1500/19, 512 scans) (22). A 2 × 2-cm axial column extending through both hemispheres superior to the ventricles was prescribed from the coronal localizing MR images (Fig 1). Phase-encoding gradient increments resulted in 2 × 2 × 1-cm<sup>3</sup> voxels and improved spatial resolution, owing to decreased phase-encoding artifacts. Water suppression was obtained by three chemical-shift selective saturation (CHESS) pulses. Lesions were excluded by locating the spectroscopic imaging column in normal-appearing tissue. Peak assignments were made using literature values for chemical shifts; however, time restraints prohibited changes in the echo time for lactate editing (22–24). Consequently, the presence of lactate could not be proved in this experiment.

In the second series of experiments, patients with major and minor NPSLE were studied using single-voxel spectroscopy. The rapid acquisition time afforded by this technique permitted study of extremely ill patients, and variable echo times provided a technique to probe the makeup of the peak at 1.3 ppm. This broad peak represents lipid and other macromolecules as well as lactate, a relatively narrow doublet, which resonates at 1.33 ppm. The spectroscopic protocol obtained spectra from 8-cm<sup>3</sup> voxels in normal-appearing deep white matter of the parietal lobe. A single-voxel, water-suppressed spin-echo sequence (PRESS: repetition time, 2000; 128 scans) was prescribed from the T2-weighted axial images (23). Two spectra with different echo times (26 or 136 milliseconds) were obtained consecutively from the same tissue voxel. In this sequence, all the likely contributions to the broad resonance at 1.3 ppm will be in phase at short echo times (26

milliseconds). However, at long echo times (136 milliseconds), lactate will be inverted because of spin-spin coupling. Moreover, contributions from molecules with short T2 (lipids and other macromolecules) will be negligible because of rapid spin-spin relaxation.

In each experiment, the unsuppressed water signal from the spectroscopic voxel was used to optimize the field homogeneity for spectroscopy by manually shimming the linear gradients.

#### Quantification of Neurometabolite Ratios and Statistical Methods

Spectroscopic data were downloaded to a Sunsparcstation 10 (Sun Microsystems Inc, Mountain View, Calif) and processed using SAGE/IDL (GE Medical Systems, Waukesha, Wis). Spectroscopic imaging was processed using 1-Hz exponential broadening, multiplied by a sine bell window in the spatial dimension, Fourier transformed, and phase corrected. Baseline was simulated by using a linear approximation based on points defined by the bases of the choline (Cho), creatine (Cr), NAA, and absolute baseline point at 0 ppm. Spectra were integrated to determine the peak area for NAA (1.9 to 2.1 ppm), Cr (2.9 to 3.1), Cho (3.1 to 3.3), and lipid-macromolecule-lactate (1.2 to 1.4) peaks. Results were expressed as the ratios NAA/Cr, Cho/Cr, and Lip-Mac/Cr. Spectroscopic data were analyzed by a two-tailed rank order *t* test and analysis of variance (ANOVA) using ICS Version 1.1 (PWS Publishers, Boston, Mass). Fisher's least significant difference test was used to establish difference rankings between means at statistically significant levels ( $P < .05$ ).

Single-voxel data were analyzed using SAGE/IDL. Each spectrum was processed with 1-Hz exponential broadening, zero-filled, Fourier transformed, phase corrected, and metabolite peak areas determined by fitting lorentzian line shapes. Data were expressed as ratios of NAA/Cr and Cho/Cr. We also recorded the presence or absence of a peak at 1.3 ppm. Unpaired *t* tests and a Mann-Whitney nonparametric test were performed in Statview (Abacus Concepts, Berkeley, Calif).

## Results

For the spectroscopic imaging experiment, we used *t* tests to compare SLE patients with healthy control subjects (Table 1). During the course of the experiment, patients with major NPSLE were receiving an average of  $67 \pm 23$  mg of prednisone and those with minor NPSLE were receiving  $13 \pm 13$  mg of prednisone ( $P < .05$ ). SLE patients were characterized as having increased disease activity index ratings ( $P < .01$ ), decreased NAA/Cr ( $P = .04$ ), and increased resonance at 1.3 ppm ( $P < .02$ ). In addition to the above abnormalities, 17% of

**TABLE 1: Neurometabolites in patients with systemic lupus erythematosus and healthy control subjects**

	Control subjects (n = 8)	Patients with SLE (n = 23)	P
Age	40.1 (12.0)	37.0 (10.9)	.53
SLEDAI	0.00 (0)	19.0 (6.9)	<.01*
NAA/Cr	2.16 (0.26)	1.90 (0.35)	<.05*
Cho/Cr	0.79 (0.06)	0.80 (0.21)	.83
1.3 ppm/Cr	0.27 (0.05)	0.49 (0.41)	<.02*

Note.—SLE indicates systemic lupus erythematosus; SLEDAI, SLE disease activity index; NAA, *N*-acetylaspartate; Cr, total creatinine; and Cho, choline-containing compounds.

\* Significant differences by the two-tailed *t* test. Results are expressed as mean (standard deviation).

NPSLE patients had increased Cho (Cho/Cr). After separating patients into three groups—major NPSLE, minor NPSLE with prior major episodes of NPSLE, and minor NPSLE with no prior major episodes of NPSLE—we found that the change in NAA was confined to those patients who had suffered a major NPSLE episode (either current or previously) ( $P < .03$ ) (Table 2). Subgroup analysis showed greater elevation of the peak at 1.3 ppm in patients with major NPSLE as compared with the minor subgroups ( $P < .02$ ). No significant association between the presence of focal lesions and increased peak at 1.3 ppm was demonstrated ( $r^2 = .047$ ,  $P = .29$ ).

In the second experiment, we used single-voxel MR spectroscopy to determine the origin of the peak at 1.3 ppm in patients with major or minor NPSLE. As in the spectroscopic imaging experiment, patients with major NPSLE had decreased NAA/Cr compared with that in patients with minor disease ( $P < .05$ ) (Table 3, Fig 2). Differing echo times in single-voxel MR spectroscopy were used to determine the existence of lactate at 1.33 ppm. Of the severely ill patients with major NPSLE studied, eight of nine had distinct peaks at 1.3 ppm at short echo times. Four of these patients were able to endure prolonged scanning and also underwent a long-echo spectroscopic study. In patients with minor NPSLE, four of five displayed elevated peaks at 1.3 ppm, and three of these patients completed the long-echo-time examination. No peak inversion was noted at 136 milliseconds, indicating the absence of significant lactate in patients with both major and minor NPSLE. Figure 3 shows spectra at different echo times from a patient with major NPSLE. At long echo times, the peak at 1.3 ppm is absent, indicating a short

TABLE 2: Neurometabolites in subgroups of patients with neuropsychiatric systemic lupus erythematosus by spectroscopic imaging

	Minor NPSLE (No Prior Major Episode) (n = 8)	Minor NPSLE (Prior Major Episode) (n = 8)	Major NPSLE (n = 7)	P
Age	35.3 (14.5)	39.3 (8.8)	36.7 (8.5)	>.05
SLEDAI	15.6 (2.8)	16.7 (4.8)	25.6 (8.1)*	<.01*
NAA/Cr	2.22 (0.32)*	1.68 (0.27)	1.78 (0.22)	<.05*
Cho/Cr	0.81 (0.21)	0.78 (0.15)	0.83 (0.17)	>.05
1.3 ppm/Cr	0.37 (0.28)	0.45 (0.54)	0.67 (0.38)*	<.05*

Note.—NPSLE indicates neuropsychiatric systemic lupus erythematosus; SLEDAI, systemic lupus erythematosus disease activity index; NAA, *N*-acetylaspartate; Cr, total creatine; Cho, choline-containing compounds; and Cre, total creatine.

\* Significant differences between value and other groups by Fisher's least significant difference rankings. Results are expressed as mean (standard deviation).

TABLE 3: Neurometabolites in patients with NPSLE by single-voxel proton MR spectroscopy

	Minor NPSLE (No Prior Major Episode) (n = 5)	Major NPSLE (Prior Major Episode) (n = 8)	P
Age	37.8 (14.8)	27.0 (5.8)	.2
SLEDAI	16.0 (3.7)	30.1 (12.6)	<.01*
NAA/Cr (26 ms)	2.06 (0.38)	1.60 (0.33)	<.05*
NAA/Cr (136 ms)	1.95 (0.06)	1.59 (0.30)	<.05*
Cho/Cr (26 ms)	0.95 (0.17)	0.98 (0.20)	.70
Cho/Cr (136 ms)	1.22 (0.11)	1.13 (0.07)	.12
1.3 ppm (26 ms)†	5/6 present	8/9 present	
1.3 ppm (136 ms)	0/3	0/4	

Note.—NPSLE indicates neuropsychiatric systemic lupus erythematosus; SLEDAI, SLE disease activity index; NAA, *N*-acetylaspartate; Cr, total creatine; Cho, choline-containing compounds; 1.3 ppm, the broad peak resonating at about 1.3 ppm (this peak includes contributions from lipid and protein macromolecules and lactate).

\* Significant differences by the two-tailed *t* test. Results are expressed as mean (standard deviation).

† 26 ms indicates data from TE = 26 ms; (136 ms), TE = 136 ms.

T2 signal, typical of lipid macromolecules rather than lactate.

## Discussion

NAA is the major peak in a water-suppressed normal proton MR brain spectrum, and in the adult brain it is a chemical marker for mature neurons and axons (24–29). Decreased NAA has been associated with injury and neuronal death in both animal and human studies (27, 28, 30–33). NAA is typically reduced in chronic neurologic diseases characterized by cognitive decline, including Alzheimer disease, dementia, stroke, multiple sclerosis, and schizophrenia (31, 33–39). NAA is decreased in normal-appearing brain tissues in patients with a history of NPSLE (W. M. Brooks, unpublished data,

1997). and in SLE patients with cerebral atrophy, indicating a substantial loss of neuronal mass and density (15). The current investigation was designed to determine the neurochemical effects of minor and major NPSLE on brain tissue.

Our results show that decreased NAA is closely associated with episodes of major NPSLE. Major NPSLE was also distinguished from minor NPSLE by greater systemic disease activity (SLE disease activity index), increased corticosteroid doses, and increased lipid-macromolecule resonances. These findings indicate that major NPSLE represents a severe cerebral insult, resulting in significant neuronal injury. The cause of the neuronal injury is not clear, although systemic effects of SLE are likely. The potential neurotoxic effects of corticosteroids cannot be completely excluded, particularly since major NPSLE is almost always treated with corticosteroids. Our experiments have not determined whether the neuronal damage in SLE is permanent or whether there is a reversible component, as has been observed in multiple sclerosis (34, 40). Determining the reversibility of NAA decline and the effects of corticosteroids will require prolonged, repeated observations. Even if NAA levels were to be recoverable to some extent, our data are most consistent with severe neurotoxicity (27, 33) associated with episodes of major NPSLE rather than a slow, progressive decrease in NAA, as in degenerative neurologic diseases (31, 32, 41).

If ischemia were the primary mechanism of neuronal injury and NAA decline in NPSLE, increased lactate would be likely in brain tissues (33, 42, 43). Indeed, strokes (1, 44), ischemic microinfarcts (45), and reversible ischemia have been implicated in NPSLE (46, 47). Lactate is observable in ischemic tissue, particu-

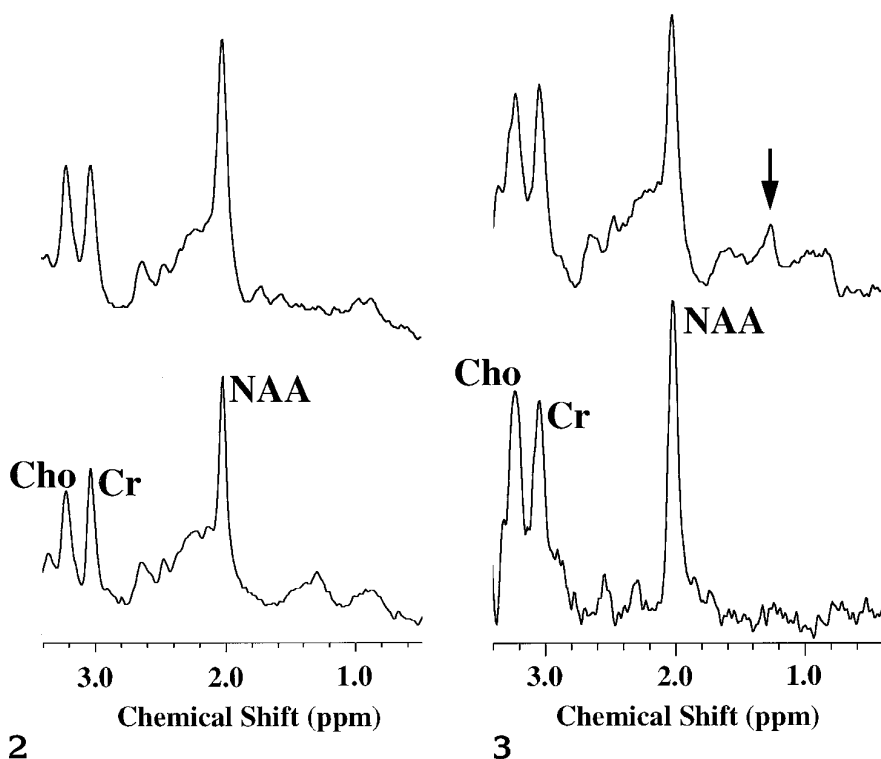


Fig 2. Proton MR spectra from patients with minor (*top*) and major (*bottom*) NPSLE. Bottom spectrum shows decreased NAA and a peak at 1.3 ppm.

Fig 3. Brain metabolites in major NPSLE.

*Top*, A short-echo-time spectrum (26 milliseconds) with elevated peaks in the chemical shift range 0.9 to 1.6 ppm (*arrow*).

*Bottom*, A long-echo-time (136 milliseconds) spectrum in which peaks from metabolites with short spin-spin relaxation times are absent. No inverted doublet from lactate is observable.

larly during and after stroke when lactate is abnormally elevated as a result of anaerobic metabolism (48). Brain lactate levels may also be elevated in the subacute stages of ischemic infarction due to anaerobic metabolism associated with macrophage infiltration in necrotic or inflamed tissue (33, 49).

Our studies reveal elevated upfield peaks from 0.9 to 1.6 ppm, including a peak in the lactate region, that have a close association with disease activity in patients with NPSLE. Although the identity of these peaks is unclear, similar upfield peaks consistent with membrane degradation, activation, or demyelination have been noted in acute multiple sclerosis (34). In that study, elevation of the lipid region, initially noted during disease exacerbations, returned to normal more slowly than did the clinical symptoms, suggesting slowly recovering injury. In our studies, long-echo, single-voxel MR spectroscopy revealed minimal underlying signal at 1.3 ppm with no perceptible signal inversion, which would be expected from the lactate doublet. Thus, although ischemia has been implicated in NPSLE, we were unable to demonstrate lactate even in severely ill patients with major NPSLE, suggesting that extensive, anaerobic metabolism is not a fundamental characteristic of NPSLE.

There are several potential reasons for the absence of observable lactate in brain tissues of patients with NPSLE. The obvious explanation is that NPSLE may be a disease of cerebral vascular injury, disturbed fluid dynamics, and neurotoxin release, rather than a primarily ischemic disease. On the other hand, the foci of ischemia might be microscopic, resulting in small loci of injury with increased lactate that produce very little MR signal compared with the large mass of surrounding normal tissues. Such volume-averaging artifacts, which diminish the signal from lesions of small volume, are major limitations of MR spectroscopy and can only be overcome by using voxels approximating the size of the lesion. The use of microscopic voxels, currently beyond MR technology available for clinical studies, is required to examine pathologic conditions of this nature. However, the large volume of brain tissue affected by reversible flow and the metabolic defects noted previously by positron emission tomography and single-photon emission computed tomography (46, 47), as well as the extensive diffuse cerebral edema reported previously (16), can be studied easily with MR spectroscopy. Despite these large areas of decreased flow and cerebral edema reported in the literature, lactate was not detected in the current series.

Our study suggests that diffuse ischemia is not the primary mechanism of NPSLE; rather, NPSLE may be a neurotoxic process associated with episodes of major NPSLE. The loss of NAA may occur acutely and be sustained chronically, but demonstration of the long-term irreversibility of NAA loss will require further longitudinal studies. The absence of lactate does not support the presence of global ischemia in our series of patients, although ischemia could occur in other SLE subgroups that have not yet been studied. The increased lipid-macromolecule peaks at 1.3 ppm, which may be an indicator of disease activity, probably indicate a host response to injury, perhaps inflammatory cell infiltration, membrane activation, degradation, or demyelination. Further MR spectroscopic studies relating neurometabolites to more conventional measures of NPSLE, including cerebral perfusion studies, formal neurocognitive testing, antineuronal antibodies, and histopathologic specimens obtained at autopsy, will be required to define these complex relationships.

## Acknowledgments

We thank Blaine Hart for screening the localizing images and Nicholas Matwiyoff for reviewing the manuscript.

## References

- Johnson RT, Richardson EP. The neurological manifestations of systemic lupus erythematosus: a clinical-pathological study of 24 cases and review of the literature. *Medicine* 1968;47:337-369
- Ellis SG, Verity MA. Central nervous system involvement in systemic lupus erythematosus: a review of neuropathological findings in 57 cases, 1955-1957. *Semin Arthritis Rheum* 1979;8:212-221
- Bluestein HG. The central nervous system in systemic lupus erythematosus. In: Lahita RG, ed. *Systemic Lupus Erythematosus*. 2nd ed. New York, NY: Churchill Livingstone; 1992:639-655
- West SG. Neuropsychiatric lupus. *Rheum Dis Clin North Am* 1994;20:129-158
- Carbotte RM, Denburg SD, Denburg JA. Cognitive dysfunction and systemic lupus erythematosus. In: Lahita RG, ed. *Systemic Lupus Erythematosus*. New York, NY: Churchill Livingstone; 1992:865-881
- Denburg S, Carbotte RM, Denburg JA. Corticosteroids and neuropsychological functioning in patients with systemic lupus erythematosus. *Arthritis Rheum* 1994;37:1311-1320
- Adelman DC, Saltiel E, Klinenberg JR. The neuropsychiatric manifestations of systemic lupus erythematosus: an overview. *Semin Arthritis Rheum* 1986;15:185-193
- Bluestein HG. Nervous system in systemic lupus erythematosus. *Immunol Allergy Clin North Am* 1988;8:315-323
- Burnstein SL, Janoff L, McCormick K. Neuropsychiatric involvement in systemic lupus erythematosus: case report and review of the literature. *J Am Osteopath Assoc* 1987;87:626-631
- Gibson T, Myers AR. Nervous system involvement in systemic lupus erythematosus. *Ann Rheum Dis* 1976;35:398-406
- Ginzler EM, Schorn K. Outcome and prognosis in systemic lupus erythematosus. *Rheum Dis Clin North Am* 1988;14:67-78
- van Dam AP. Diagnosis and pathogenesis of CNS lupus. *Rheumatol Int* 1991;11:1-11
- McCune WJ, MacGuire A, Aisen A, Gebarski S. Identification of brain lesions in neuropsychiatric systemic lupus erythematosus by magnetic resonance scanning. *Arthritis Rheum* 1988;31:159-166
- Sibbitt WL Jr, Sibbitt RR. Magnetic resonance spectroscopy and positron emission tomography scanning in neuropsychiatric systemic lupus erythematosus. *Rheum Dis Clin North Am* 1993;19:851-868
- Sibbitt WL Jr, Haseler LH, Griffey RH, Hart BL, Sibbitt RR, Matwiyoff NA. Analysis of cerebral structural changes in systemic lupus erythematosus by proton magnetic resonance spectroscopy. *AJNR Am J Neuroradiol* 1994;45:923-928
- Sibbitt WL Jr, Brooks WM, Haseler LJ, et al. Spin-spin relaxation of brain tissues in systemic lupus erythematosus. *Arthritis Rheum* 1995;38:810-818
- Tan EM, Cohen AS, Fries JF, et al. 1982 revised criteria for the classification of systemic lupus erythematosus. *Arthritis Rheum* 1982;25:1271-1277
- Bombardier C, Gladman DD, Urowitz MB, Caron D, Chang CH, and the Committee on Prognosis Studies in SLE. Derivation of the SLEDAI: a disease activity index for lupus patients. *Arthritis Rheum* 1992;35:630-640
- Hawker G, Gabriel S, Bombardier C, Goldsmith C, Caron D, Gladman D. A reliability study of SLEDAI: a disease activity index for systemic lupus erythematosus. *J Rheumatol* 1993;20:657-660
- Carbotte RM, Denburg JA. Prevalence of cognitive impairment in systemic lupus erythematosus. *J Nerv Ment Dis* 1986;174:357-364
- Denburg JA, Carbotte RM, Denburg SD. Neuronal antibodies and cognitive dysfunction in systemic lupus erythematosus. *Neurology* 1987;37:464-467
- Griffey RH, Flamig DP. VAPOR for solvent-suppressed, short echo, volume localized proton spectroscopy. *J Magn Reson* 1990;88:161-166
- Bottomley PA. Spatial localization in NMR spectroscopy in vivo. *Ann N Y Acad Sci* 1987;508:333-348
- Hanstock CC, Rothman DL, Pritchard JW, Jue T, Shulman RG. Spatially localized <sup>1</sup>H NMR spectra of metabolites in the human brain. *Proc Natl Acad Sci U S A* 1988;85:1821-1825
- van Zijl P, Moonen CT, Alger JR, Cohen J, Chesnick SA. High field localized proton spectroscopy in small volumes: greatly improved localized and shimming using shielded strong gradients. *Magn Reson Med* 1989;10:256-265
- Luyten PR, den Hollander JA. Observation of metabolites in the human brain by MR spectroscopy. *Radiology* 1986;161:795-798
- Koller KJ, Zaczek R, Coyle JT. N-acetyl-aspartyl-glutamate: region levels in rat brain and the effects of brain lesions as determined by a new HPLC method. *J Neurochem* 1984;43:1136-1142
- Michaelis T, Merboldt K-D, Haenicke W, Gyngell ML, Bruhn H, Frahm J. On the identification of cerebral metabolites in localized <sup>1</sup>H NMR spectra of human brain in vivo. *NMR Biomed* 1991;4:90-98
- Urenjak J, Williams SR, Gadian DG, Noble M. Specific expression of N-acetylaspartate in neurons, oligodendrocyte-type-2 astro-

- cyte progenitors and immature oligodendrocytes in vitro. *J Neurochem* 1992;59:55-61
30. Barker PB, Breiter SN, Soher BJ, et al. Quantitative proton spectroscopy of canine brain: in vivo and in vitro correlations. *Magn Reson Med* 1994;32:157-163
  31. Meyerhoff DJ, MacKay S, Poole N, Dillon WP, Weiner MW, Fein G. N-acetylaspartate reductions measured by <sup>1</sup>H MRS in cognitively impaired HIV-seropositive individuals. *Magn Reson Imaging* 1994;12:653-659
  32. Moats RA, Ernst T, Shonk TK, Ross BD. Abnormal cerebral metabolite concentrations in patients with probable Alzheimer disease. *Magn Reson Med* 1994;32:110-115
  33. Sappey-Marini D, Calabrese G, Hetherington HP, et al. Proton magnetic resonance spectroscopy of human brain: application to normal white matter, chronic infarction, and MRI white matter signal hyperintensities. *Magn Reson Med* 1992;26:313-327
  34. Davie CA, Hawkins CP, Barker GJ, et al. Serial proton magnetic resonance spectroscopy in acute multiple sclerosis lesions. *Brain* 1994;117:49-58
  35. Olson JE, Katz-Stein A, Reo NV, Jolesz FA. Evaluation of acute brain edema using quantitative magnetic resonance imaging: effects of pretreatment with dexamethasone. *Magn Reson Med* 1992;24:64-74
  36. Shiino A, Matsuda M, Morikawa S, et al. Proton magnetic resonance spectroscopy with dementia. *Surg Neurol* 1993;39:143-147
  37. Ford CC, Griffey RH, Matwyloff NA, Rosenberg GA. Multivoxel <sup>1</sup>H-MRS of stroke. *Neurology* 1992;42:1408-1412
  38. Narayana PA, Wolinsky JS, Jackson EF, et al. Proton MR spectroscopy of gadolinium-enhanced multiple sclerosis plaques. *J Magn Reson Imaging* 1992;2:263-270
  39. Sharma R, Venkatasubramanian PN, Barany M, Davis JM. Proton magnetic resonance spectroscopy of the brain in schizophrenic and affective patients. *Schizophr Res* 1992;8:43-49
  40. de Stefano N, Matthews PM, Arnold DL. Reversible decreases in N-acetylaspartate after acute brain injury. *Magn Reson Med* 1995;34:721-727
  41. Miller BL, Moats RA, Shonk T, Ernst T, Woolley S, Ross BD. Alzheimer disease: depiction of increased cerebral myoinositol with proton MR spectroscopy. *Radiology* 1993;187:433-437
  42. Crockard HA, Gadian DG, Frackowiak RS, et al. Acute cerebral ischemia: concurrent changes in cerebral blood flow, energy metabolism, pH, and lactate measured with hydrogen clearance and <sup>31</sup>P and <sup>1</sup>H nuclear magnetic resonance spectroscopy. II: changes during ischemia. *J Cereb Blood Flow Metab* 1987;7:394-402
  43. Mathews VP, Barker PB, Blackband SJ, Chatham JC, Bryan RN. Cerebral metabolites in patients with acute and subacute strokes: concentrations determined by quantitative proton MR spectroscopy. *AJR Am J Roentgenol* 1995;165:633-638
  44. Fields RA, Sibbitt WL, Toubbeh H, Bankhurst AD. Neuropsychiatric lupus erythematosus, cerebral infarctions, and anticardiolipin antibodies. *Ann Rheum Dis* 1990;49:114-117
  45. Hanly JG, Walsh NM, Sangalang V. Brain pathology in systemic lupus erythematosus. *J Rheumatol* 1992;19:732-741
  46. Pinching AJ, Travers RL, Hughes GR, Jones T, Moss S. Oxygen-15 brain scanning for detection of cerebral involvement in systemic lupus erythematosus. *Lancet* 1978;1:898-900
  47. Meyer GJ, Schober O, Stoppe G, Wildhagen K, Seidel JW, Hundeshagen H. Cerebral involvement in systemic lupus erythematosus (SLE): comparison of positron emission tomography (PET) with other imaging methods. *Psychiatry Res* 1989;29:367-368
  48. Barker PB, Gillard JH, van Zijl PCM, et al. Acute stroke: evaluation with serial proton magnetic resonance spectroscopic imaging. *Radiology* 1992;192:723-732
  49. Petroff OAC, Graham GD, Blamire AM, et al. Spectroscopic imaging of stroke in humans: histopathology correlates of spectral changes. *Neurology* 1992;42:1349-1359