

Are your **MRI contrast agents** cost-effective?

Learn more about generic **Gadolinium-Based Contrast Agents**.



**FRESENIUS
KABI**

caring for life

AJNR

**Persistent hyperplastic primary vitreous
involving the anterior eye.**

M Castillo, D K Wallace and S K Mukherji

AJNR Am J Neuroradiol 1997, 18 (8) 1526-1528

<http://www.ajnr.org/content/18/8/1526>

This information is current as
of April 19, 2024.

Persistent Hyperplastic Primary Vitreous Involving the Anterior Eye

Mauricio Castillo, David K. Wallace, and Suresh K. Mukherji

Summary: The imaging features of persistent hyperplastic primary vitreous (PHPV) affecting the posterior eye are well known. We recently encountered a patient with the anterior variant of PHPV who had MR imaging of the orbits. We present the clinical and imaging findings of this unusual entity and discuss the therapeutic options available for its management.

Index terms: Eyes, vitreous; Eyes, magnetic resonance; Infants, eyes and orbits

Persistent hyperplastic primary vitreous (PHPV) is a pathologic entity resulting from abnormal hypertrophy of the fetal fibrovascular primitive stroma (hyaloid system) of the eye (1). The primary vitreous forms around the seventh week of life and begins involuting by 20 weeks (2). Nearly always, it completely disappears by the time of birth. Persistence and hypertrophy of these vessels can result in PHPV in the anterior and/or posterior chambers (1). Prognosis and therapeutic strategies for the management of posterior and anterior PHPV differ considerably. We present the imaging findings in a patient with PHPV of the anterior chamber.

Case Report

A 4-month-old boy with a cloudy left eye was brought in for treatment by his parents, who had noticed preferential use of the right eye. There was no family history of cataracts in childhood and the patient was developing normally and otherwise in good health. On physical examination, there was no response to light by the left eye, the left iris was slightly hypopigmented, and a dense cataract prevented retinal examination. The lens containing the cataract was dislocated temporally and anteriorly, resulting in a shallow anterior chamber. Elongated ciliary processes were attached to the nasal aspect of the posterior lens (Fig 1A). The left cornea appeared smaller than the right one. Horizontal jerk nystagmus was also present.

B-mode sonography showed a flat retina and normal-appearing vitreous. The right eye was normal. Magnetic resonance (MR) imaging was performed with noncontrast

T1-weighted sequences (500/15/4 [repetition time/echo time/excitations]), axial T2-weighted sequences (4000/90/2), and axial contrast-enhanced fat-suppressed T1-weighted sequences (605/15/3) (Fig 1B and C). MR images showed a normal-appearing vitreous chamber and overall normal size of the left globe. The lens was of normal signal intensity, but thin. The anteroposterior dimension of the aqueous chamber was decreased. After contrast administration, the region of the ciliary body and lens enhanced. The right eye was normal. Cataract extraction, primary posterior capsulotomy, and anterior vitrectomy were performed. After removal of the lens, a dense, white, retrolenticular membrane with extensive vascularization was identified. Prominent feeder vessels supplying this membrane were present on the anterior surface of the iris. The membrane was dissected to clear the central visual axis. Examination of the left fundus revealed a normal retina and a thin translucent stalk extending from the optic disk through the vitreous, presumed to represent a remnant of Cloquet's canal.

Discussion

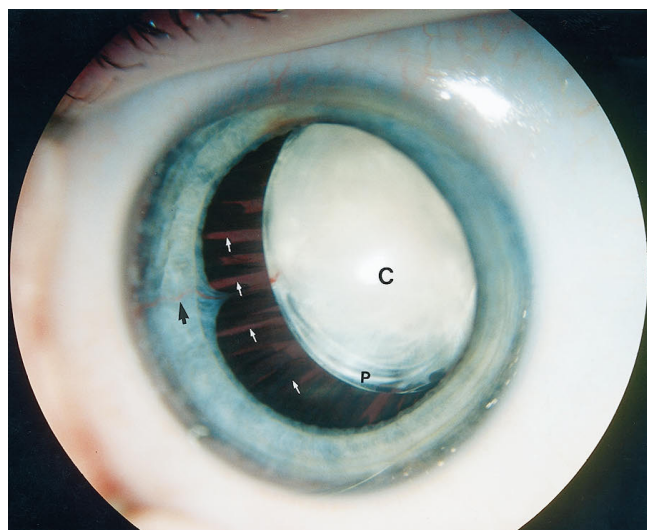
In the fetus, the primitive lens and vitreous receive their blood supply mainly via the hyaloid system. The hyaloid artery, which is a branch of the ophthalmic artery, is the main blood vessel of this system. The hyaloid artery gains entry to the developing eye via the choroidal fissure (2). Intrinsically, the fetal eye is irrigated by a meager layer of small vascular channels (hyaloid system) stemming from three sources: the hyaloid artery (supplying mainly the central primary vitreous), the vasa hyaloidea propria (supplying the peripheral portions of the primary vitreous), and the anterior ciliary vessels (supplying the iris and lens) (1). The anterior portion of this arterial system involutes at 8 months of life and is usually present in premature infants. The posterior portion of the arterial system normally regresses by 7 months of life, but is also occasionally present

Received September 5, 1996; accepted after revision January 10, 1997.

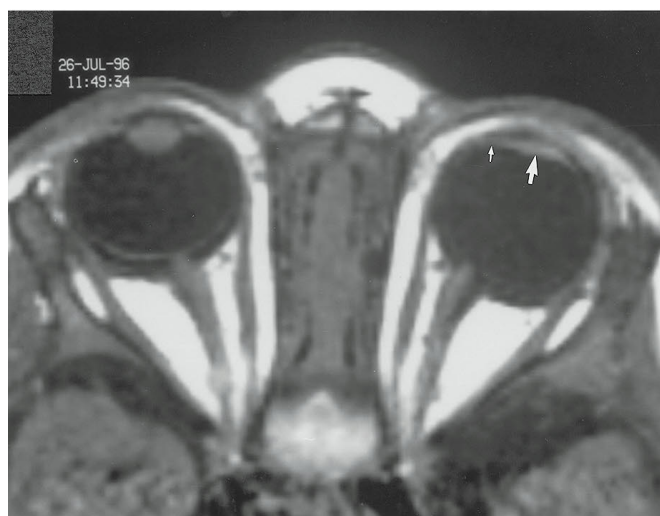
From the Departments of Radiology (M.C., S.K.M.) and Ophthalmology and Pediatrics (D.K.W.), University of North Carolina School of Medicine, Chapel Hill.

Address reprint requests to M. Castillo, MD, Department of Radiology, CB 7510, University of North Carolina School of Medicine, Chapel Hill, NC 27599.

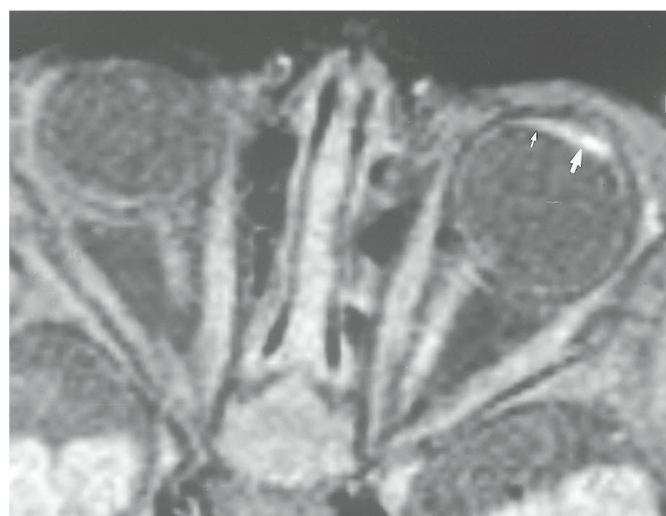AJNR 18:1526-1528, Sep 1997 0195-6108/97/1808-1526 © American Society of Neuroradiology



A



B



C

Fig 1. A 4-month-old boy with PHPV involving the anterior chamber of the eye.

A, Intraoperative photograph shows dense, total cataract (C) dislocated temporally and anteriorly. There is a prominent anterior iris feeding vessel (*black arrow*) and elongated ciliary processes (*white arrows*) contiguous with the nasal aspect of the posterior lens and retrolenticular plaque (P).

B, Axial T1-weighted MR image shows a small left anterior chamber (compare with normal right side). The left lens is flat (*large arrow*). The medial region of the ciliary body (*small arrow*) is thick. The vitreous is normal. Compare with normal right eye.

C, Axial contrast-enhanced fat-suppressed T1-weighted MR image at similar level shows enhancement in region of the lens (*large arrow*) and medial ciliary body (*small arrow*) related to the presence of hypervascular tissues. The contralateral lens and ciliary body did not enhance. The left vitreous is normal. On T2-weighted images (not shown), the vitreous also appeared normal.

in premature infants. In the absence of hypertrophy, the primitive blood vessels of the hyaloid system regress completely. The anterior and posterior hyaloid vascular systems may persist independently or together. The pathogenesis of hypertrophy of any portion of the primary vitreous is unknown (3).

Most patients with PHPV have a combination of both anterior and posterior types. In one large series, 28 of 48 patients had both types (in the remaining patients, 12 had the anterior type and eight had the purely posterior type) (4). Clinically, leukokoria, strabismus, and a small eye may be present in all types. In posterior PHPV, findings include vitreous membranes, a stalk extending from the optic nerve to the posterior lens (a remnant of Cloquet's canal that carries

the hyaloid artery), dysplasia of the optic disk, an indistinct macula that may be hypopigmented, retinal folds, and a clear lens. In anterior PHPV, findings include a shallow anterior chamber, elongated ciliary processes, enlarged iris vessels, infantile or juvenile-onset glaucoma, cataract, intralenticular hemorrhage, and a retrolental fibrovascular membrane. A persistent hyaloid artery may also be present in some cases of anterior PHPV. Surgical management of PHPV depends on its type (1, 4). In patients with anteroposterior PHPV in which vision is unsalvageable, a lensectomy may be done. In posterior PHPV, when rehabilitation of the eye is deemed possible, a vitrectomy may be performed. In cases of purely anterior PHPV, a lensectomy-membranectomy and anterior vit-

rectomy are done. The goal of surgery is to salvage useful vision (in concert with aggressive amblyopia therapy) and/or to prevent or alleviate glaucoma and to correct amblyopia. Prognosis depends on the type of PHPV. Treatment of posterior and combined anteroposterior PHPV has a less favorable outcome, with most patients attaining perception only of motion or light. Conversely, in purely anterior PHPV, a good visual outcome is achieved when aphakic correction (contact lenses) and amblyopia therapy are successful.

From an imaging standpoint, only the features of posterior PHPV are well known (5). In posterior PHPV, the globe is small and contains retinal detachments that are hyperdense by CT and of increased signal intensity on T1- and T2-weighted MR images. A fine linear structure extending from the head of the optic nerve to the posterior surface of the lens represents Cloquet's canal, and, when seen, is considered typical of PHPV. After contrast administration, the vitreal abnormalities may enhance, which is believed to reflect a persistent hypervascular vitreous. We found three previous articles that mentioned that in cases of PHPV the anterior chamber can be shallow and the lens can be small and irregular (6–8), but no detailed description of the anterior variant of PHPV was offered in those publications. The diagnosis of anterior PHPV is usually obvious clinically, and

therefore these patients are not routinely imaged. Actually, anterior PHPV is not an uncommon cause of cataract in very young children. Our patient was imaged to rule out a central pathogenesis for his nystagmus. In our case of anterior PHPV, the anterior chamber was shallow, the lens was thin and dysplastic, and there was enhancement in the region of the ciliary body and lens, reflecting hypervascular tissues at these levels. The vitreous chamber was normal. Both clinically and by imaging, the main differential diagnosis is infantile cataracts.

References

1. Reese AB. Persistent hyperplastic primary vitreous. *Am J Ophthalmol* 1955;40:317–331
2. Larsen WJ. Development of the eyes. In: *Human Embryology*. New York, NY: Churchill Livingstone; 1993:341–351
3. Pruett RC. The pleomorphism and complications of posterior hyperplastic primary vitreous. *Am J Ophthalmol* 1975;80:625–629
4. Pollard ZF. Results of treatment of persistent hyperplastic primary vitreous. *Ophthalmic Surg* 1991;22:48–52
5. Mafee MF, Goldberg MF. Persistent hyperplastic primary vitreous (PHPV): role of computed tomography and magnetic resonance. *Radiol Clin North Am* 1987;25:683–692
6. Kaste SC, Jenkins JJ, Meyer D, Fontanesi J, Pratt CB. Persistent hyperplastic primary vitreous of the eye: imaging findings with pathologic correlation. *AJR Am J Roentgenol* 1994;162:437–440
7. Mafee MF, Goldberg MF, Valvassori GE, Capek V. Computed tomography in the evaluation of patients with persistent hyperplastic primary vitreous (PHPV). *Radiology* 1982;145:713–717
8. Mafee MF, Ainbinder D, Afshani E, Mafee RF. The eye. *Neuroimaging Clin North Am* 1996;6:29–59