

Are your MRI contrast agents cost-effective?

Learn more about generic Gadolinium-Based Contrast Agents.



**FRESENIUS
KABI**

caring for life

AJNR

The use of early postoperative MR in detecting residual juvenile cerebellar pilocytic astrocytoma.

N K Rollins, P Nisen and K N Shapiro

AJNR Am J Neuroradiol 1998, 19 (1) 151-156

<http://www.ajnr.org/content/19/1/151>

This information is current as of April 20, 2024.

The Use of Early Postoperative MR in Detecting Residual Juvenile Cerebellar Pilocytic Astrocytoma

Nancy K. Rollins, Perry Nisen, and Kenneth N. Shapiro

PURPOSE: We compared visibility of residual juvenile cerebellar pilocytic astrocytomas (JPAs) on early postoperative and follow-up MR studies to determine whether early postoperative MR imaging has a valid role as a baseline study.

METHODS: We reviewed the MR images of 21 consecutive children who had undergone resection of cerebellar JPA. The diagnosis of residual tumor was made on the basis of nodular enhancement that corresponded to enhancing tumor on the preoperative MR studies and/or nonenhancing nodular T2 signal that corresponded to nonenhancing tumor. Because no patient received chemotherapy or radiation therapy, abnormal T2 signal or enhancement on the early postoperative study that resolved on the follow-up study was presumed to be due to peritumoral edema and/or surgical manipulation. Nodular T2 signal and/or enhancement in the tumor bed not seen on the initial postoperative MR study but present on the subsequent MR study and unchanged on serial follow-up MR studies was presumed to represent residual tumor rather than tumor that had recurred.

RESULTS: Compared with follow-up studies, the initial postoperative MR images were true-positive for residual tumor in six patients, false-positive in five, equivocal for residual tumor in four, true-negative in five, and false-negative in one. Residual tumor did not consistently enhance, and peritumoral edema and changes resulting from surgical manipulation tended to mask or simulate residual tumor.

CONCLUSION: Early postoperative MR imaging is not accurate in differentiating residual JPA from postoperative changes, and the role of early postoperative MR imaging as a baseline study for comparison with further studies is questionable.

Juvenile pilocytic astrocytomas (JPAs) are among the most common brain tumors of childhood. Although histologically similar to JPAs arising from other parts of the brain, JPAs that arise from the cerebellum act biologically more benign than those that arise in other locations (1, 2). Cerebellar JPAs have the best long-term prognosis when total resection is achieved (1). Magnetic resonance (MR) imaging has, for the most part, replaced computed tomography (CT) in the radiologic evaluation of posterior fossa tumors, such as JPAs. The optimal timing for postoperative MR imaging to detect residual tumor is controversial (3, 4). The literature recommends CT as

soon as possible after surgery, preferably within 24 hours before nonneoplastic contrast enhancement resulting from surgical manipulation becomes radiologically apparent (3, 4). Although CT and MR imaging differ considerably in sensitivity to abnormal tissue on precontrast and postcontrast studies (5), clinical recommendations based on the CT literature have been applied to MR imaging, as in our institution, where cranial MR studies have traditionally been obtained as soon as possible after surgical resection of low-grade cerebellar astrocytomas. We examined the role of early postoperative MR studies as a baseline for comparison with subsequent studies; specifically, to determine how accurate the early postoperative MR studies are in differentiating residual tumor from nonneoplastic edema and changes resulting from surgical manipulation.

Received February 26, 1997; accepted after revision June 30.

From the Departments of Radiology (N.K.R.) and Pediatrics (P.N.), Divisions of Pediatric Radiology and Hematology and Oncology, University of Texas Southwestern Medical Center and Neurosurgeons for Children (K.N.S.), Dallas.

Address reprint requests to Nancy Rollins, MD, Department of Radiology, Children's Medical Center of Dallas, 1935 Motor St, Dallas, TX 75235.

Methods

From January 1991 through November 1996, 43 children with de novo intracranial neoplasms histologically confirmed as JPA were seen at our institution. In 24 of these patients, the

TABLE 1: Comparison of perioperative and follow-up MR studies

Case	Age, y/ Sex	Follow-up, mo	Time to Initial MR, d	Early Postoperative MR Findings	Follow-up MR Findings
1	7/F*	54	6	Residual	Residual
2	12/M	38	3	Residual	No tumor
3	6/F	52	5	Residual	Residual
4	5/F†	62	3	Residual	Residual
5	3/F	44	5	Residual	No tumor
6	2/M	29	2	Residual	No tumor
7	4/M‡	46	4	Residual	No tumor
8	7/F	16	3	Residual	Residual
9	3/F	29	4	Residual	Residual
10	5/M	14	1	Residual	No tumor
11	15/F	29	2	Residual	Residual
12	5/F	29	1	? Residual	No tumor
13	7/M	28	2	? Residual	No tumor
14	4/F	40	5	? Residual	Residual
15	8/F	14	3	? Residual	No tumor
16	4/M	34	1	No tumor	No tumor
17	4/F	48	5	No tumor	Residual
18	5/F	58	6	No tumor	No tumor
19	5/F	38	2	No tumor	No tumor
20	4/M	8	3	No tumor	No tumor
21	7/M	57	3	No tumor	No tumor

* Figure 3.

† Figure 1.

‡ Figure 2.

tumors arose from the cerebellar hemisphere or vermis. Our study group consisted of 21 of these 24 consecutive children, ages 3 to 16 years, who had undergone posterior fossa craniectomy or craniotomy at our institution over this time interval. Criteria for inclusion in the study were as follows: availability of preoperative contrast-enhanced MR images ($n = 20$) or CT scans ($n = 1$), postoperative MR images obtained within 7 days of surgery, follow-up MR studies from this ($n = 17$) or an outside ($n = 4$) institution, and no chemotherapy or radiation therapy. After the posterior fossa tumors were identified radiologically, the patients had been started on high-dose dexamethasone, which was tapered postoperatively. At the time of follow-up, therefore, no patient was receiving exogenous steroids.

MR imaging was done on a 0.5-T superconducting unit in 13 patients and on a 1.5-T unit in eight. Precontrast and postcontrast T1-weighted (525/20/2 [repetition time/echo time/excitations]) spin-echo sequences were obtained in the sagittal and axial planes, and proton density- and heavily T2-weighted (3258–3500/35,90/1) conventional spin-echo sequences were obtained in the axial plane.

The early postoperative and all subsequent follow-up MR images were assessed for abnormal contrast enhancement and T2 changes. The diagnosis of residual tumor was made on the basis of nodular enhancement that corresponded to enhancing tumor and/or nonenhancing nodular T2 signal that corresponded to nonenhancing tumor on the preoperative MR study. Findings on the initial postoperative MR study were compared with those on follow-up MR studies. Because no patient received chemotherapy or radiation therapy, abnormal T2 signal or enhancement observed on the early postoperative study that resolved on follow-up studies was presumed to be due to peritumoral edema and/or surgical manipulation. Nodular T2 signal and/or enhancement in the tumor bed not seen on the initial postoperative MR study but present on the subsequent MR images and unchanged on serial follow-up MR studies was presumed to represent residual tumor rather than tumor that had recurred.

Results

Early postoperative MR images were obtained a mean of 3 days after surgery (range, 1 to 6 days) (Table 1). Thirteen patients were imaged within 72 hours of surgery, including one at 16 hours and one at 24 hours after surgery. Three patients were restudied 5 weeks after surgery, and eight patients at 12 weeks after surgery for a variety of clinical indications, including nonspecific neurologic symptoms ($n = 3$), possible hydrocephalus ($n = 3$), and suspicion of residual tumor ($n = 5$). The remaining 10 patients underwent follow-up MR imaging 6 months after surgery as per in-house protocol. The total duration of neuroradiologic follow-up was 8 to 62 months (mean, 37 months), during which time MR studies were obtained at 6-month intervals.

The early postoperative MR images showed confluent increased T2 signal around the tumor bed in 16 patients. Eleven of the 14 patients with abnormal T2 signal around the tumor bed also had areas of abnormal enhancement. Eight patients had curvilinear or punctate enhancement while in three patients the enhancement was nodular. Five patients had no areas of abnormal T2 signal and no abnormal enhancement at the tumor bed. Overall, the early postoperative MR studies were interpreted as showing no residual tumor in six patients, equivocal for tumor in four patients, and positive for residual tumor in 11 patients. One patient was reexamined 3 days later; residual tumor was found but incompletely resected.

Eight patients had evidence of residual tumor on follow-up MR images; in six, tumor was correctly identified on the initial postoperative MR study while

in two patients the tumor was missed (Table 2). Compared with the follow-up MR studies, the initial postoperative MR study was true-positive for residual tumor in six patients (Fig 1), false-positive in five (Fig 2), suspicious for residual tumor where none was

TABLE 2: Sensitivity and specificity of early postoperative MR

	Residual Tumor at Follow-up	No Residual Tumor	Total
Residual tumor on early MR	6	5	11
No residual tumor	1	5	6
Questionable tumor	1	3	4
Total	8	13	21

Sensitivity: $TP/TP + FN = 6/7 = 0.857$

Specificity: $TN/TN + FP = 5/10 = 0.500$

Positive predictive value: $TP/TP + FP = 6/11 = 0.545$

Negative predictive value: $TN/TN + FN = 5/6 = 0.833$

Note.—TN indicates true negative; TP, true positive; FP, false positive; and FN, false negative.

present at follow-up in three, suspicious for residual tumor confirmed at follow-up in one, true-negative in five, and false-negative in one (Fig 3).

In eight patients, the enhancement seen on the initial postoperative MR study had resolved on subsequent MR studies and was presumably nonneoplastic. Nonneoplastic enhancement was either curvilinear or curvilinear with punctate nodules and was seen as early as 16 hours after surgery. Neoplastic enhancement was curvilinear in one patient.

Discussion

On the basis of this study, we conclude that early postoperative MR imaging is not accurate in differentiating residual JPA from postoperative changes and suggest that early postoperative MR imaging should not be used as a baseline examination. Residual tumor does not consistently enhance and peritumoral edema and changes resulting from surgical manipulation may mask or simulate residual tumor.

Documentation of residual cerebellar JPA in the

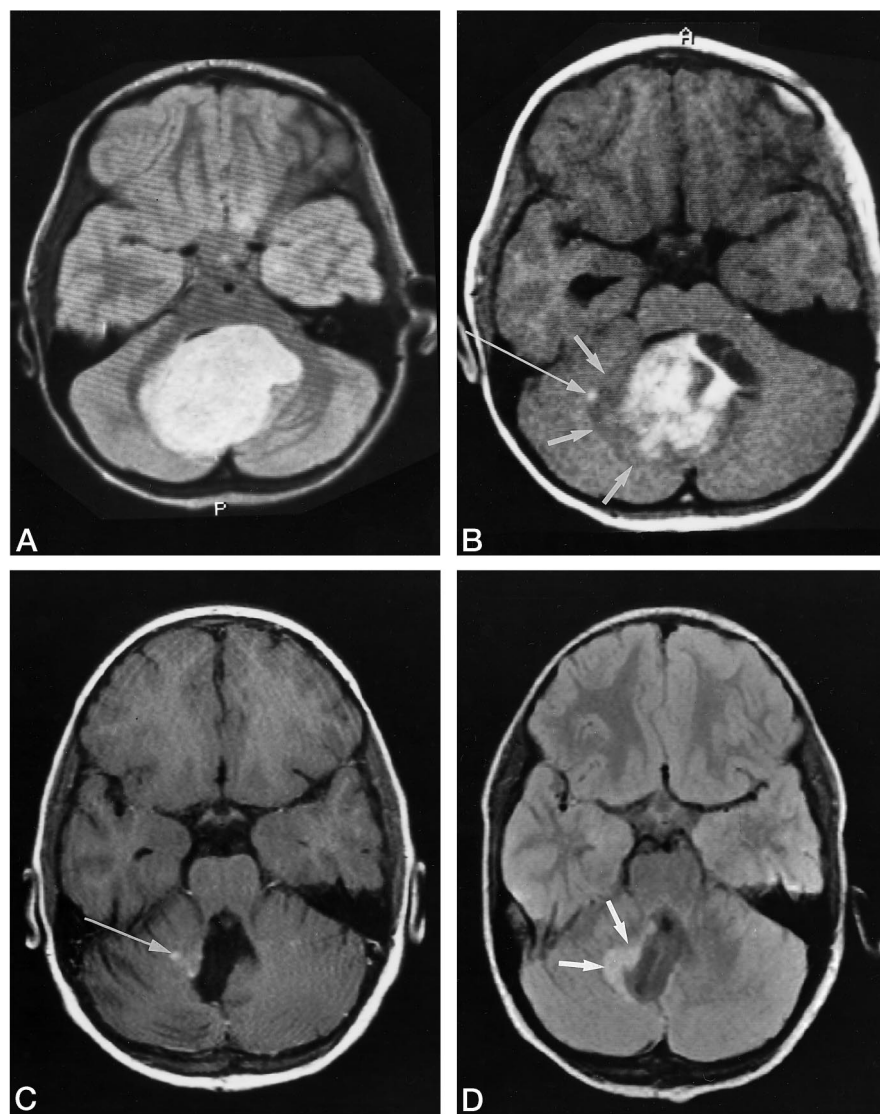


FIG 1. A 6-year-old girl with JPA arising from the cerebellar vermis. This case illustrates the importance of T2-weighted MR sequences in the detection of residual JPA, as residual tumor may not enhance.

A, Preoperative proton density-weighted image (3250/35/1) shows well-defined hyperintense tumor with no peritumoral edema.

B, Preoperative contrast-enhanced T1-weighted image shows predominantly solid tumor mass with areas of cystic change. Notice that the periphery of the tumor mass has minimal enhancement (*short arrows*). *Long arrow* indicates enhancing nodule surrounded by nonenhancing tumor.

C, Contrast-enhanced T1-weighted image 72 hours after surgery shows minimal residual enhancing tumor (*arrow*).

D, Postoperative proton density-weighted image shows more tumor (*arrows*) than is identifiable on the contrast-enhanced images.

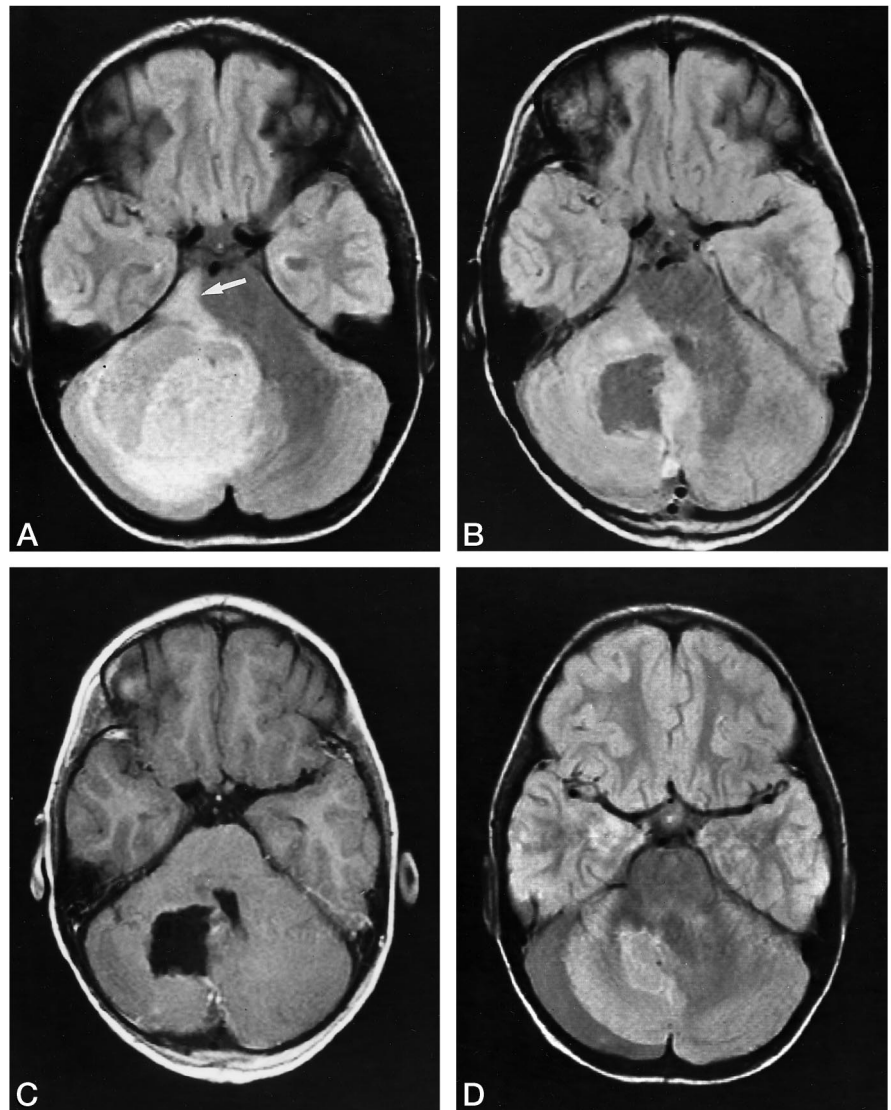
FIG 2. A 4-year-old boy with right cerebellar JPA in whom abnormal T2 signal mimicked residual tumor on perioperative MR images. In this case, absence of significant enhancement on the postoperative MR study was an accurate indication of total tumor resection.

A, Preoperative proton density-weighted image shows large hyperintense mass with extensive peritumoral edema extending into brain stem (arrow).

B, Proton density-weighted image 72 hours after craniectomy shows considerable abnormal signal within the right cerebellum, suggestive of residual tumor.

C, Contrast-enhanced T1-weighted image shows minimal enhancement around the periphery of the tumor bed.

D, Proton density-weighted image 3 months later shows complete resolution of abnormal T2 signal. Patient was tumor-free 46 months later.



immediate postoperative period does not influence clinical management (1, 2). The tumor is not usually treated with irradiation, the role of adjuvant chemotherapy in this setting is controversial, and in the absence of bulky residual disease most neurosurgeons will defer reexploration. Nonetheless, it is a common clinical practice to obtain MR images as soon as possible after surgery. In fact, patient enrollment into the Children's Cancer Group (CCG) and Pediatric Oncology Group (POG) protocols 9891 and 9130, respectively, which studied the natural history of newly diagnosed low-grade astrocytomas in children receiving radical surgical resection as the sole treatment, stipulated imaging, preferably MR, within 72 hours of surgery (Study Committee Progress Report CCG-9891/POG-9130).

The rationale for early postoperative imaging after resection of cerebellar JPA is based on reports that nonneoplastic postsurgical changes do not enhance by CT before 5 days, whereas residual neoplastic disease shows enhancement immediately after surgery (3, 6–8). Steinbok et al (6) studied 21 children with a variety

of benign and malignant tumors in different locations, eight of whom had cerebellar astrocytomas. All the patients in this study had undergone contrast-enhanced CT within 72 hours of tumor resection. Enhancement was seen within the tumor bed in three of the eight patients with cerebellar astrocytomas, although none had evidence of tumor on subsequent follow-up CT studies. One patient had biopsy-proved residual cerebellar astrocytoma that did not enhance on the CT study done early in the postoperative period. The authors concluded that the presence of contrast enhancement on the immediate postoperative CT scan does not distinguish residual tumor from changes due to surgical manipulation. The editor's brief commentary, which followed, suggested that the patients were not imaged early enough and stressed the need for CT within 12 to 24 hours after surgery (6).

Nonneoplastic enhancement within the tumor bed is detectable much earlier with MR imaging than with CT because of the superior sensitivity of MR imaging to small amounts of extravascular contrast material

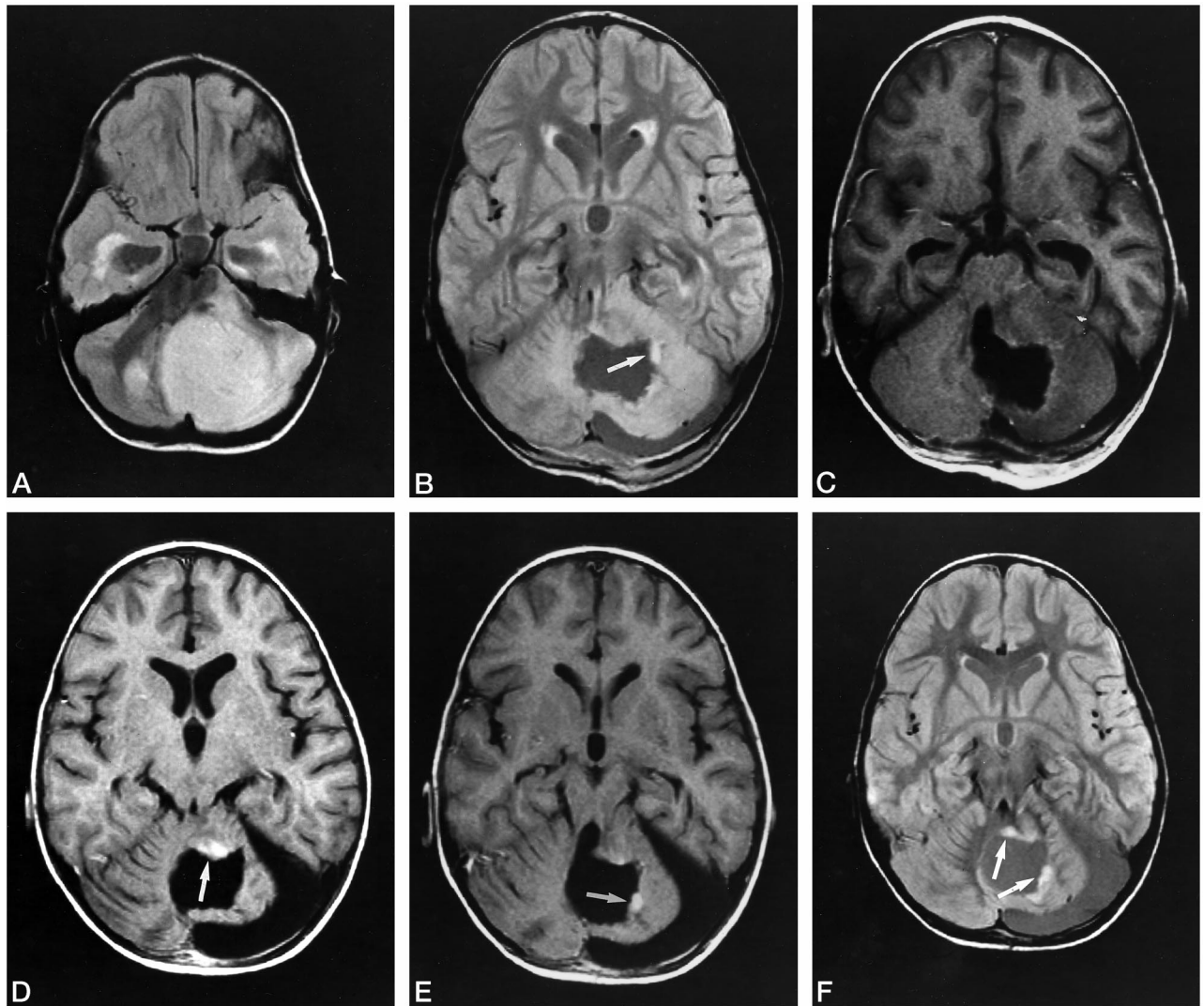


FIG 3. A 5-year-old girl with left cerebellar JPA. Residual tumor failed to enhance on the perioperative MR study, presumably because of exogenous steroids.

A, Preoperative proton density-weighted image shows extensive peritumoral edema involving left middle cerebellar peduncle.

B, Proton density-weighted image 3 days after craniectomy shows considerable residual edema. Arrow indicates nodule, suggestive of residual tumor.

C, Contrast-enhanced MR image 3 days after surgery shows minimal enhancement in the tumor bed.

D, Contrast-enhanced MR image 5 weeks later shows interval development of an enhancing nodule along the ventral aspect of the tumor bed (arrow).

E, Another enhancing nodule is seen studing the lateral aspect of the tumor bed (arrow).

F, Proton density-weighted image 5 weeks after surgery shows the peritumoral edema has resolved, revealing two nodules (arrows), corresponding to the abnormal enhancement seen on the contrast-enhanced MR study but differing in location from the apparent tumor nodule seen on the proton density-weighted image from the early postoperative MR study. Presumably, the residual tumor was masked on the perioperative MR study by edema. The tumor has remained stable over the ensuing 60 months.

(5). Nonneoplastic enhancement may be seen on MR images within 24 hours of surgery (5). We frequently observed contrast enhancement at the tumor bed on the initial postoperative MR study; enhancement was seen in nine of the 12 patients imaged within 72 hours of surgery and as early as 16 hours after surgery. We found that nonneoplastic enhancement was usually but not invariably curvilinear and/or punctate while neoplastic enhancement was nodular, but that the absence of nodular enhancement did not always correlate with absence of tumor. Of the eight patients with residual tumor, three had minimal or no enhancement on the early postoperative MR studies

despite the fact that the tumor had enhanced on the preoperative study and showed enhancement on follow-up studies. Lack of neoplastic enhancement on the initial postoperative MR study that was clearly visible at follow-up may have been due to the effects of the high-dose exogenous steroids routinely given in the perioperative period.

Increased T2 signal at the surgical site may be due to edema, surgical manipulation, or residual tumor (4, 9). The use of contrast material increases the sensitivity of MR imaging but does not necessarily differentiate abnormal T2 signal due to tumor from that due to surgical manipulation (10-12). Moreover,

areas of abnormal enhancement may not correlate with tumor margins; nonenhancing tumor may be visible only on the T2-weighted images (11, 12). While abnormal T2 signal due to neoplastic disease should persist on sequential MR studies, abnormal T2 signal due to surgical manipulation or peritumoral edema should resolve. We found that nonneoplastic edema was maximal on the initial postoperative MR study but resolved by 4 to 6 weeks. However, in the absence of abnormal enhancement, nodular T2 signal due to tumor cannot reliably be differentiated from gliosis.

In our study, the neurosurgeons reported gross total resection of tumor in 17 of 21 patients and were correct in 12 of the 17. There were no cases in which the surgeon thought tumor was left but none was found by MR imaging. We agree with Schneider et al (2), who stated that surgeons tend to overestimate the extent of resection; a conclusion that underscores the need for postoperative imaging. However, because findings on immediate postoperative MR images may be false-positive or false-negative for tumor, we defer MR imaging until 4 to 6 weeks after surgery in this clinical setting.

Although gross total resection of cerebellar JPA is associated with the best clinical outcome, even patients with subtotally resected tumor tend to have long event-free survivals. Schneider et al (2) followed up 23 patients with JPA over 5 years, during which time no patient had CT evidence of tumor progression. The follow-up period for the eight patients with residual tumor in our study was 8 to 62 months, during which time no patient had demonstrable tumor growth, underwent reexploration, or required chemotherapy or radiation therapy. However, as small nodules of residual JPA may grow and require further therapy, radiologic surveillance to detect clinically asymptomatic tumor growth is indicated. The duration and frequency of neuroradiologic surveillance may vary depending on the appearance of the tumor bed on baseline MR studies. Patients with no abnormal T2 signal or enhancement at the tumor bed

are probably at less risk for recurrence than those with equivocal MR findings. Surveillance protocols should evaluate the cost of sequential MR studies and the benefits obtained from early detection of recurrence, and recommendations or guidelines should be revised accordingly.

Acknowledgments

We thank Kathryn Fletcher for manuscript preparation, Alison Russell for photography, and Naomi Winick for manuscript review.

References

1. Undjian S, Marinov M, Georgiev K. **Long-term follow-up after surgical treatment of cerebellar astrocytomas in 100 children.** *Childs Nerv Syst* 1989;5:99-101
2. Schneider JH, Raffel C, McComb JG. **Benign cerebellar astrocytomas of childhood.** *Neurosurgery* 1992;30:58-63
3. Cairncross JG, Pexman JHW, Rathbone MP, DelMaestro RF. **Postoperative contrast enhancement in patients with brain tumor.** *Ann Neurol* 1985;17:570-572
4. Dickman CA, Rekatte HL, Bird CR, Drayer BP, Medina M. **Non-enhanced and gadolinium-DTPA-enhanced MR imaging in postoperative evaluation in pediatric brain tumors.** *J Neurosurg* 1989;71:49-53
5. Elster AD, DiPersio DA. **Cranial postoperative site: assessment with contrast-enhanced MR imaging.** *Radiology* 1990;174:93-98
6. Steinbok P, Poskitt K, Cochrane DD, Flodmark OO. **Early computed tomographic scanning after resection of brain tumors in children.** *Childs Nerv Syst* 1991;7:16-20
7. Rao CVGK, Kishore PRS, Bartlett J, Brennan TG. **Computed tomography in the postoperative patient.** *Neuroradiology* 1980;19:257-263
8. Jeffries BF, Kishore PRS, Singh KS, Ghatak NR, Krempa J. **Contrast enhancement in the postoperative brain.** *Radiology* 1981;139:409-413
9. Bird CR, Drayer BP, Medina J, Rekatte HL, Flom RA, Hodak JA. **Gd-DTPA enhanced MR imaging in pediatric patients after brain tumor resection.** *Radiology* 1988;169:123-126
10. Atlas SW. **Intraaxial brain tumors.** In: Atlas SW, ed. *Magnetic Resonance Imaging of the Brain and Spine.* New York, NY: Raven Press; 1991;223-326
11. Brant-Zawadzki M, Norman D, Newton T, et al. **Magnetic resonance of the brain: the optimal screening technique.** *Radiology* 1984;152:71-77
12. Felix R, Scherner W, Laniado M, et al. **Brain tumors: MR imaging with gadolinium-DTPA.** *Radiology* 1985;156:681-688