

Are your **MRI contrast agents** cost-effective?

Learn more about generic **Gadolinium-Based Contrast Agents**.



**FRESENIUS
KABI**

caring for life

AJNR

Hirayama disease: MR diagnosis.

C J Chen, C M Chen, C L Wu, L S Ro, S T Chen and T H Lee

AJNR Am J Neuroradiol 1998, 19 (2) 365-368

<http://www.ajnr.org/content/19/2/365>

This information is current as
of April 16, 2024.

Hirayama Disease: MR Diagnosis

Chi-Jen Chen, Chiung-Mei Chen, Chia-Lun Wu, Long-Sun Ro, Sien-Tsong Chen, and Tsong-Hai Lee

Summary: We report the MR findings in two cases of Hirayama disease, a kind of cervical myelopathy related to flexion movements of the neck. In flexion MR studies, we can see the striking and pathognomonic picture of anterior shifting of posterior dura at the lower cervical spinal canal. In nonflexion studies, we find that asymmetric cord atrophy, especially at the lower cervical cord, though subtle, is highly suggestive of Hirayama disease. When it is seen, a flexion MR study is warranted to prove this diagnosis.

Hirayama disease, also termed *nonprogressive juvenile spinal muscular atrophy of the distal upper limbs*, is a kind of cervical myelopathy related to flexion movements of the neck (1-6). The pathogenetic mechanism of this disease is attributed to forward displacement of the posterior wall of the lower cervical dural canal when the neck is in flexion, which causes marked, often asymmetric, flattening of the lower cervical cord (1, 6-9). We report two cases of Hirayama disease and describe the pathognomonic findings at flexion magnetic resonance (MR) imaging. We also discuss the mechanism behind this characteristic appearance and describe findings suggestive of Hirayama disease on routine nonflexion MR studies.

Case Reports

Case 1

A 17-year-old boy had a 3-year history of slowly progressive weakness of the left hand and forearm that worsened in cold weather. More recently, he noted aggravated weakness of the left hand when he flexed his neck. His medical history was noncontributory; none of his family had the same symptoms.

Neurologic examination revealed atrophic changes in the thenar, hypothenar, and interosseous muscles of the left hand and in the muscles of the left forearm, except the brachioradialis. Fine, irregular, and nonsynchronous tremulous movements in the left fingers were noted. The deep tendon reflexes were symmetrically normal without Babinski sign. Sensation to pin-prick, vibration, and joint position was intact. No extrapyramidal signs, Horner sign, or abnormalities in sweating and urination were noted. Electromyography showed fibrillation and increased polyphasic waves of large amplitude and long duration in the left first dorsal interosseus, abductor pollicis brevis, extensor indicis pollicis, and flexor digitorum profundus, suggestive of an active denervation change. Motor nerve conduction velocities of the median and ulnar nerves were normal. These findings were compatible with an anterior horn cell disorder involving the C7-8 and T-1 levels of the cord. The plain cervical spine radiographs showed no definite abnormality. Nonflexion cervical sagittal MR images (1.5 T) revealed

cord atrophy at the C6-7 vertebral level (Fig 1A). Axial T1-weighted and gradient-echo T2-weighted images showed evidence of cord atrophy, more obvious on the left anterior aspect (Fig 1B). Because the clinical presentation was reminiscent of Hirayama disease, a flexion cervical MR study was obtained. Sagittal and axial T1- and T2-weighted images showed anterior displacement of the posterior wall of the cervical dural canal below C-3, causing marked flattening of the cord (Fig 1C and D). An epidural mass, isointense with the cord on T1-weighted images and hyperintense on T2-weighted images, was noted at the posterior aspect of the lower cervical canal with some small flow void signals inside it (Fig 1C and D). After injection of contrast material, the epidural mass displayed strong and homogeneous enhancement (Fig 1E). This mass disappeared after the patient returned to a nonflexion position, and it was considered to be engorged venous plexus due to dural shifting.

The clinical presentation and the characteristic findings on flexion MR images led to the diagnosis of Hirayama disease. A neck collar was placed to prevent neck flexion, and the patient was doing well, with no further progression of symptoms, at the 3-month follow-up study.

Case 2

A 16-year-old boy reported a 2-year history of slowly progressive weakness and atrophy of both hands, especially on the left, that was more pronounced in cold weather. His medical history was noncontributory; none of his family had the same symptoms.

A neurologic examination revealed localized atrophy and weakness of the left hand with asynchronous, irregular, and fine tremors of the fingers in an extended posture. The right hand presented a similar picture, but the signs and symptoms were less severe than on the left side. The deep tendon reflexes were normal with flexor plantar responses on both sides. No ataxia, sensory disturbances, extrapyramidal signs, or abnormalities in sweating and urination were noted. Electromyography showed actively denervated and reinnervated patterns in the left extensor digitorum communis, left abductor pollicis, bilateral adductor digiti minimus, and bilateral sternal part of the pectoralis major. Motor nerve conduction velocities of the median and ulnar nerves were normal. These findings suggested a possible anterior horn cell disorder involving the C7-8 and T-1 segments of the cord.

Plain cervical spine radiographs revealed no abnormalities except straight alignment. Nonflexion sagittal T1- and T2-weighted cervical MR images (1.5 T) showed equivocal cord atrophy in the lower cervical region without obvious canal stenosis (Fig 2A). The dura mater was in close contact with the wall of the spinal canal. Axial T1-weighted and gradient-echo T2-weighted images showed left anterior cord atrophy from the C-5 to C-7 vertebral levels (Fig 2B).

Received August 19, 1996; accepted after revision January 8, 1997.

From the Departments of Diagnostic Radiology (C-J.C.) and Neurology (C-M.C., C-L.W., L-S.R., S-T.C., T-H.L.), Chang Gung Memorial Hospital and Medical College, Taipei, Taiwan, Republic of China.

Address reprint requests to Chi-Jen Chen, MD, Department of Diagnostic Radiology, Chang Gung Memorial Hospital, 199 Tung Hwa North Road, Taipei, Taiwan, Republic of China.

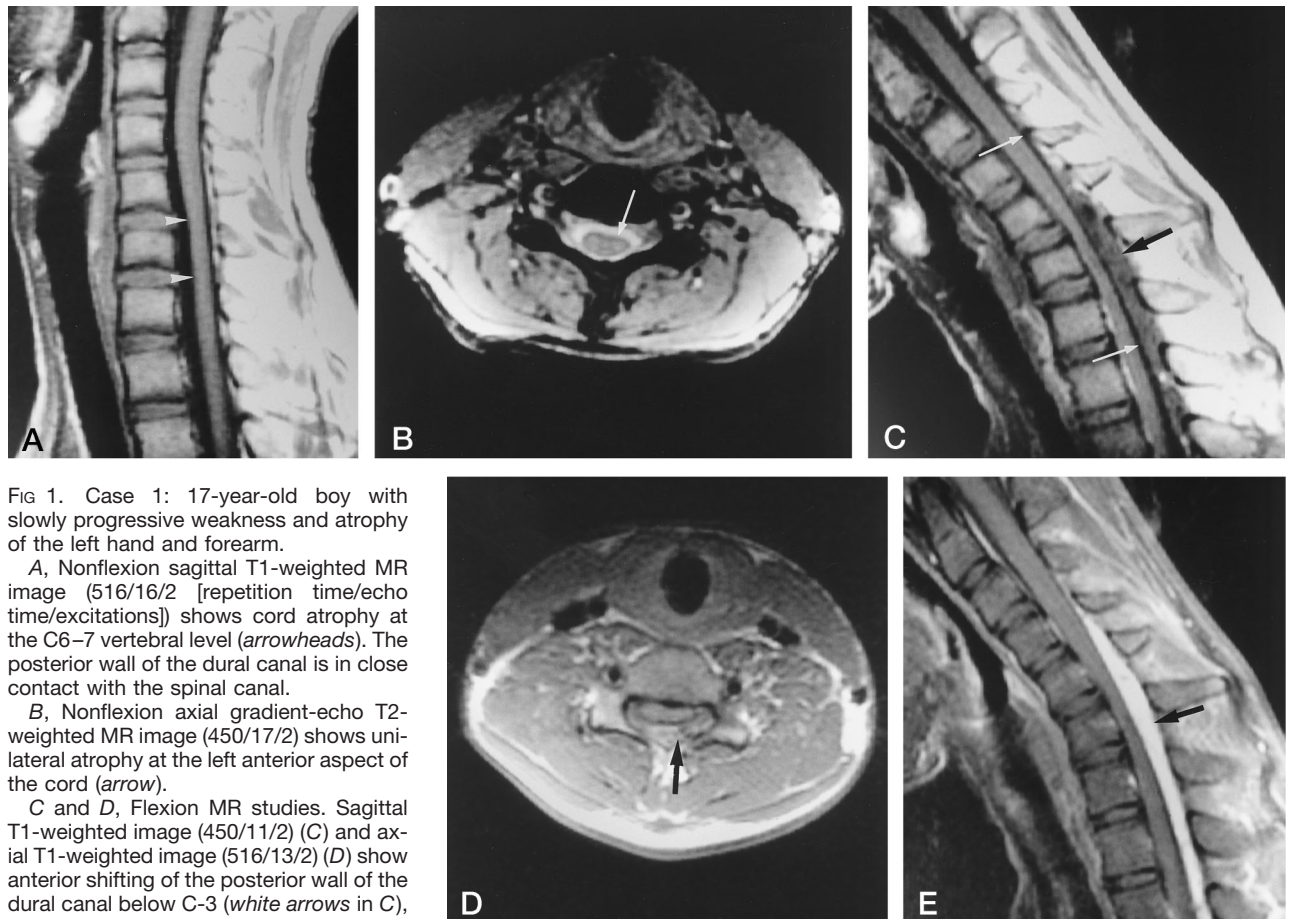


FIG 1. Case 1: 17-year-old boy with slowly progressive weakness and atrophy of the left hand and forearm.

A, Nonflexion sagittal T1-weighted MR image (516/16/2 [repetition time/echo time/excitations]) shows cord atrophy at the C6–7 vertebral level (arrowheads). The posterior wall of the dural canal is in close contact with the spinal canal.

B, Nonflexion axial gradient-echo T2-weighted MR image (450/17/2) shows unilateral atrophy at the left anterior aspect of the cord (arrow).

C and D, Flexion MR studies. Sagittal T1-weighted image (450/11/2) (C) and axial T1-weighted image (516/13/2) (D) show anterior shifting of the posterior wall of the dural canal below C-3 (white arrows in C), which causes marked flattening of the lower cervical cord. An epidural mass (black arrow in C and D) posterior to the shifting dura mater is noted, with small flow void signals inside it.

E, Contrast-enhanced flexion sagittal T1-weighted MR image (450/11/2) shows strong and homogeneous enhancement of the epidural mass (arrow).

Assuming a diagnosis of Hirayama disease, we performed flexion cervical MR imaging. Sagittal T1- and T2-weighted images showed anterior shifting of the posterior wall of the cervical dural canal below C-2, which compressed the cord from the C-4 to the C-7 vertebral levels (Fig 2C). An epidural mass, isointense on T1-weighted images and hyperintense on T2-weighted images, was noted at the posterior spinal canal, with some curvilinear flow void signals inside it (Fig 2C). The mass displayed strong, homogeneous enhancement on contrast-enhanced T1-weighted images (Fig 2D), and disappeared when the neck was returned to a neutral position (Fig 2E). The diagnosis of Hirayama disease was confirmed. The patient was fitted with a neck collar, and no further progression was noted at the 2-month follow-up study.

Discussion

Hirayama disease is a benign disorder with a stationary stage after a progressive course. It occurs mainly in young males between the ages of 15 and 25 years. The clinical features include insidious onset, predominantly unilateral upper extremity weakness and atrophy, cold paresis, and no sensory or pyramidal tract involvement (1–5). Although Hirayama et al first reported this disease in 1959 (2), pathologic study was not possible until 1982 (4), because of its benign course. At pathologic examination, these authors found the lesions only in the anterior horns of the spinal cord from C-5 to T-1, particularly marked at C-7 and C-8 (4). However, they were not able to

ascertain from this pathologic specimen the underlying pathogenesis of the disease.

Current neuroradiologic techniques are able to show forward displacement of the posterior wall of the lower cervical dural canal in neck flexion, which is presumed to be a primary pathogenetic mechanism of Hirayama disease (6–9). The mechanism of this anteriorly displaced dural canal has been explained by Kikuchi et al (6) as a tight dural canal in flexion, caused by a disproportional length between the vertebrae and the dural canal. The imaging findings in our cases were consistent with this hypothesis. We explain this phenomenon as follows. The spinal dura mater is a loose sheath that is anchored in the vertebral canal by the nerve roots and by attachment to the periosteum in two places: one at the foramen magnum and the dorsal surfaces of C-2 and C-3, and the other at the coccyx (10). The remainder of the dura mater is only suspended and cushioned in the spinal canal by the epidural fat, venous plexus, and loose connective tissues (10). In neck extension, the dura mater of the cervical spine is slack and thrown into accordionlike transverse folds (11). In neck flexion, the dura becomes tighter, because the length of the cervical canal increases as the neck moves from extension to flexion. The difference in length between extension and flexion from T-1 to the top of the atlas is 1.5 cm at the anterior wall and 5 cm at the posterior wall (11). Normally, the slack of the dura can compensate for the increased length in flexion; therefore, although it smoothes out, the dura can still be in close contact with the walls of the spinal canal without anterior displace-

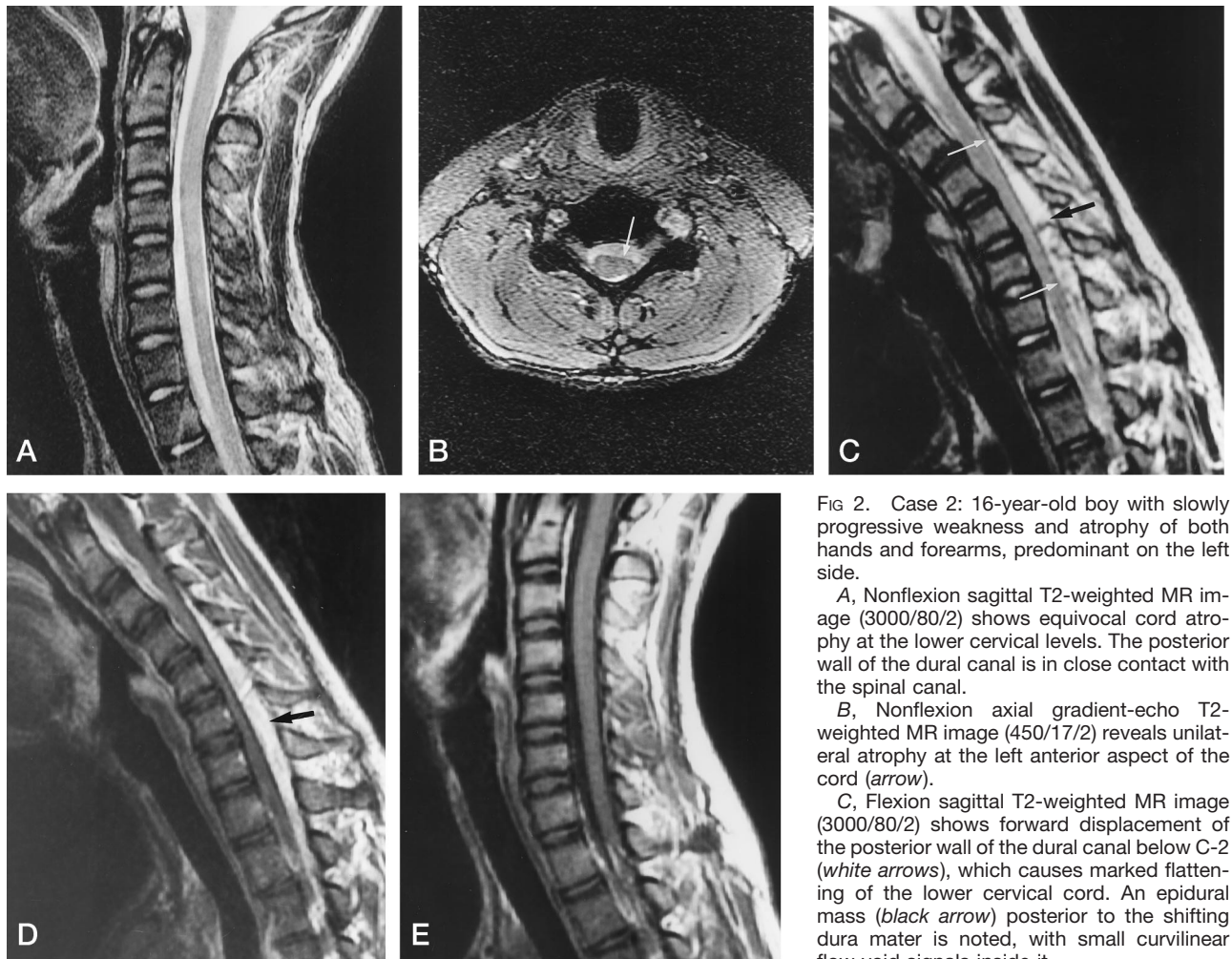


FIG 2. Case 2: 16-year-old boy with slowly progressive weakness and atrophy of both hands and forearms, predominant on the left side.

A, Nonflexion sagittal T2-weighted MR image (3000/80/2) shows equivocal cord atrophy at the lower cervical levels. The posterior wall of the dural canal is in close contact with the spinal canal.

B, Nonflexion axial gradient-echo T2-weighted MR image (450/17/2) reveals unilateral atrophy at the left anterior aspect of the cord (arrow).

C, Flexion sagittal T2-weighted MR image (3000/80/2) shows forward displacement of the posterior wall of the dural canal below C-2 (white arrows), which causes marked flattening of the lower cervical cord. An epidural mass (black arrow) posterior to the shifting dura mater is noted, with small curvilinear flow void signals inside it.

D, Contrast-enhanced flexion sagittal T1-weighted MR image (450/11/2) shows strong and homogeneous enhancement of this epidural mass (arrow).

E, Contrast-enhanced nonflexion sagittal T1-weighted MR image (450/11/2), which was obtained after D, shows that the posterior epidural mass has disappeared and the shifting dura mater has returned to its normal position.

ment. In Hirayama disease, the dural canal is no longer slack in extension, because of an imbalance in growth of the vertebrae and the dura mater. Therefore, a tight dural canal is formed, which cannot compensate for the increased length of the posterior wall during flexion. This causes an anterior shifting of the posterior dural wall, with consequent compression of the cord. This compression may cause microcirculatory disturbances in the territory of the anterior spinal artery or in the anterior portion of the spinal cord. The chronic circulatory disturbance resulting from repeated or sustained flexion of the neck may produce necrosis of the anterior horns, which are most vulnerable to ischemia (1).

In patients with Hirayama disease, conventional radiographic studies of the cervical spine usually show no specific abnormalities except straight alignment or scoliosis (9). Myelography can show the forward movement of the posterior dural wall when the neck is flexed (9); however, this examination is difficult to perform, because it is not easy to retain the contrast medium in the cervical subarachnoid space when the neck is flexed, regardless of whether the patient is in a prone, supine, or decubitus position. MR studies in neck flexion, which are easy to obtain, can show not only the anterior displacement of the posterior wall but also a well-enhanced crescent-shaped mass in the posterior epidural space of the lower cervical canal (8). This mass is thought to represent congestion of the posterior internal vertebral venous plexus

rather than vascular malformations or tumors, because it vanishes once the neck returns to a neutral position (6).

Some pathophysiological factors are responsible for this venous engorgement. First, the negative pressure in the posterior spinal canal resulting from anterior shifting of the dural canal increases the flow to the posterior internal vertebral venous plexus (8). Second, in our opinion, the compressed anterior internal vertebral venous plexus caused by anterior displacement of the dural canal increases the burden of the posterior internal vertebral venous plexus. And, third, the posture of neck flexion decreases the venous drainage of the jugular veins, impeding the venous return of internal vertebral venous plexus (8). In combination, these factors cause the formation of an engorged posterior internal vertebral venous plexus, which, in imaging, becomes a striking and specific characteristic of this disease.

Though Hirayama disease is self-limiting, early diagnosis is still necessary, because placement of a cervical collar will prevent neck flexion, which has been shown to stop disease progression (12). While a diagnosis of Hirayama disease is straightforward at flexion MR imaging, the challenge for neuroradiologists is how to identify this condition on routine nonflexion MR studies. From our cases, we found that asymmetry is one of the most characteristic findings of this disease, both clinically and radiologically. Thus, in cases of adolescent onset of distal upper limb weakness, the finding of asymmetric cord

atrophy on routine nonflexion MR studies (Figs 1B and 2B), especially at the lower cervical cord, should raise the suspicion of Hirayama disease. When this sign is seen, a flexion MR study should be performed to confirm the diagnosis.

References

1. Hirayama K. **Non-progressive juvenile spinal muscular atrophy of the distal upper limb (Hirayama's disease)**. In: De Jong JMBV, ed. *Handbook of Clinical Neurology*. Amsterdam, the Netherlands: Elsevier; 1991;15:107-120
2. Hirayama K, Toyokura Y, Tsubaki T. **Juvenile muscular atrophy of unilateral upper extremity: a new clinical entity**. *Psychiatr Neurol Jpn* 1959;61:2190-2197
3. Hirayama K. **Juvenile non-progressive muscular atrophy localized in hand and forearm: observation in 38 cases**. *Clin Neurol (Tokyo)* 1972;12:313-324
4. Hirayama K, Tomonaga M, Kitano K, Yamada T, Kojima S, Arai K. **Focal cervical poliopathy causing juvenile muscular atrophy of distal upper extremity: a pathological study**. *J Neurol Neurosurg Psychiatry* 1987;50:285-290
5. Sobue I, Saito N, Iida M, Ando K. **Juvenile type of distal and segmental muscular atrophy of upper extremities**. *Ann Neurol* 1978;3:429-432
6. Kikuchi S, Tashiro K, Kitagawa K, Iwasaki Y, Abe H. **A mechanism of juvenile muscular atrophy localized in the hand and forearm (Hirayama's disease): flexion myelopathy with tight dural canal in flexion [in Japanese]**. *Clin Neurol (Tokyo)* 1987;27:412-419
7. Tokumaru Y, Hirayama K. **Anterior shift of posterior lower cervical dura mater in patients with juvenile muscular atrophy of unilateral upper extremity**. *Clin Neurol (Tokyo)* 1989;29:1237-1243
8. Mukai E, Matsuo T, Muto T, Takahashi A, Sobue I. **Magnetic resonance imaging of juvenile-type distal and segmental muscular atrophy of upper extremities**. *Clin Neurol (Tokyo)* 1987;27:99-107
9. Mukai E, Sobue I, Muto T, Takahashi A, Goto S. **Abnormal radiological findings on juvenile-type distal and segmental muscular atrophy of upper extremities**. *Clin Neurol (Tokyo)* 1985;25:620-626
10. Williams PL, Warwick R, Dyson M, Bannister LH. *Gray's Anatomy*, 37th ed. London, England: Churchill Livingstone; 1989:1086-1092
11. Bland JH. **Basic anatomy**. In: Bland JH, ed. *Disorders of the Cervical Spine: Diagnosis and Medical Management*. 2nd ed. Philadelphia, Pa: Saunders; 1994:41-70
12. Tokumaru Y, Hirayama K. **A cervical collar therapy for non-progressive juvenile spinal muscular atrophy of the distal upper limb (Hirayama's disease)**. *Clin Neurol (Tokyo)* 1992;32:1102-1106