

Are your **MRI contrast agents** cost-effective?

Learn more about generic **Gadolinium-Based Contrast Agents**.



**FRESENIUS  
KABI**

caring for life

**AJNR**

**Three-dimensional contrast-enhanced MR angiography of the extracranial carotid arteries: two techniques.**

R A Levy and J H Maki

*AJNR Am J Neuroradiol* 1998, 19 (4) 688-690

<http://www.ajnr.org/content/19/4/688>

This information is current as of April 17, 2024.

## Three-dimensional Contrast-Enhanced MR Angiography of the Extracranial Carotid Arteries: Two Techniques

Richard A. Levy and Jeffrey H. Maki

**Summary:** Two methods of contrast-enhanced dynamic 3-D MR angiography of the head and neck are demonstrated. In the first, arterial and arteriovenous phases are temporally resolved by timing contrast injection such that maximum arteriovenous signal intensity difference is matched to acquisition of central k-space. A second, faster sequence allows for temporal resolution of arterial, early arteriovenous, late arteriovenous, and washout arteriovenous phases without a need for precise injection timing.

With the evolution of MR scanners and software capabilities and the concomitant ability to acquire faster three-dimensional spoiled gradient-echo pulse sequences, dynamic contrast-enhanced 3-D MR angiography has become a widely practiced technique. Its application to the head and neck has been facilitated by improvements in MR hardware and software that permit improved spatial and temporal resolution. These improvements include faster and stronger gradient capabilities, which in conjunction with the most recent software upgrades, allow for rapid dynamic acquisition of complete spatial frequency information, permitting very short sequential 3-D acquisitions.

At our institution, the use of contrast-enhanced dynamic 3-D MR angiography has supplanted catheter angiography in a significant number of head and neck cases, and is probably superior to other MR angiographic methods, such as two-dimensional time-of-flight (TOF) angiography (1). We present our experience with two methods of contrast-enhanced dynamic 3-D MR angiography in the head and neck.

### Methods

Two contrast injection timing protocols, in conjunction with MR scanner upgrades, were used to illustrate selective arterial and arteriovenous enhancement in dynamic 3-D MR angiography of the head and neck. Scanner upgrades included increased gradient strength (23 mT/m) and slew rates (115 T/m per second) suitable for echo-planar imaging as well as software capable of rapid sequential acquisition of complete k-space data for dynamic 3-D MR angiography. All MR angiography was performed on a GE 1.5-T Signa scanner. A head and

neck coil (MedRad, Pittsburgh, Pa) was used for all extracranial MR angiography, and a head coil (General Electric, Milwaukee, Wis) was used for all intracranial MR angiography. Placement of the imaging volume was based on a T1-weighted sagittal localizer series extending from the thoracic inlet through the brain for coronal extracranial sequences, on a T1-weighted coronal localizer series of the face and orbits for sagittal intracranial sequences, and on a sagittal T1-weighted localizer series of the brain for axial intracranial sequences.

The first method, in which the interval of maximum contrast-enhanced arteriovenous signal intensity difference was matched to the center of k-space in a sequentially phase-encoded fast 3-D spoiled gradient-echo sequence, predicted selective enhancement of the arterial phase (Fig 1). This technique takes advantage of fast (eg, echo-planar) gradient and postprocessing capabilities and is otherwise rendered fast (eg, 30-second imaging intervals) by the use of minimum TR (6.8 to 8.6), TE (1.4 to 2.5), and y-axis phase encodings ( $256 \times 128$  imaging matrix), without the use of flow compensation or fat saturation. Other imaging parameters included a flip angle of  $44^\circ$  to  $45^\circ$  for T1-weighted contrast-enhanced sequences, a field of view (FOV) of  $20 \times 20$  to  $26 \times 26$  cm, one excitation, and a bandwidth of 31.3 to 32 kHz. Twenty-eight to 32 sections, 1.5- to 2-mm thick, were produced during a 28- to 32-second interval. This technique may be used with either a single- or double-dose contrast bolus (0.1 to 0.2 mmol/kg), with the latter promising better vascular contrast. The injection methodology has been described previously and includes a 10-second bolus prior to the start of scanning, with peak arteriovenous signal difference beginning 20 seconds after initiation of the bolus and lasting approximately 10 seconds (2). With this injection scheme, the midpoint of the plateau of the maximum arteriovenous signal intensity difference occurs approximately 25 seconds after bolus initiation, and is timed to occur during the middle of the scan when the low-amplitude phase-encoding steps are acquired (sequential phase-encoding scheme).

The second method represented further improvement in temporal resolution by using sequential 16-section 3-D volumes. The use of half-excitation (half-Fourier transform) and three-quarter (rectangular) FOV options allowed sequential imaging of 3-D volumes having a 2-mm z-axis resolution, 6-second scan intervals, and a 1-second interscan delay. With this improved temporal resolution, it was no longer necessary to time the contrast injection to the center of k-space for selective arterial enhancement, and the bolus was administered at the beginning of the scan (Fig 2). Other imaging parameters were 6.2/2.2 (TR/TE), a flip angle of  $45^\circ$ , a bandwidth of 31.3 kHz, an FOV of  $32 \times 24$  cm, and a matrix of  $256 \times 128$ .

Received December 2, 1996; accepted after revision May 30, 1997.

From the Department of Radiology (R.A.L.) and the Division of Magnetic Resonance Imaging (J.H.M.), University of Michigan Hospitals, Ann Arbor.

Address reprint requests to Richard A. Levy, MD, 4310 Woodview E, Saginaw, MI 48603.

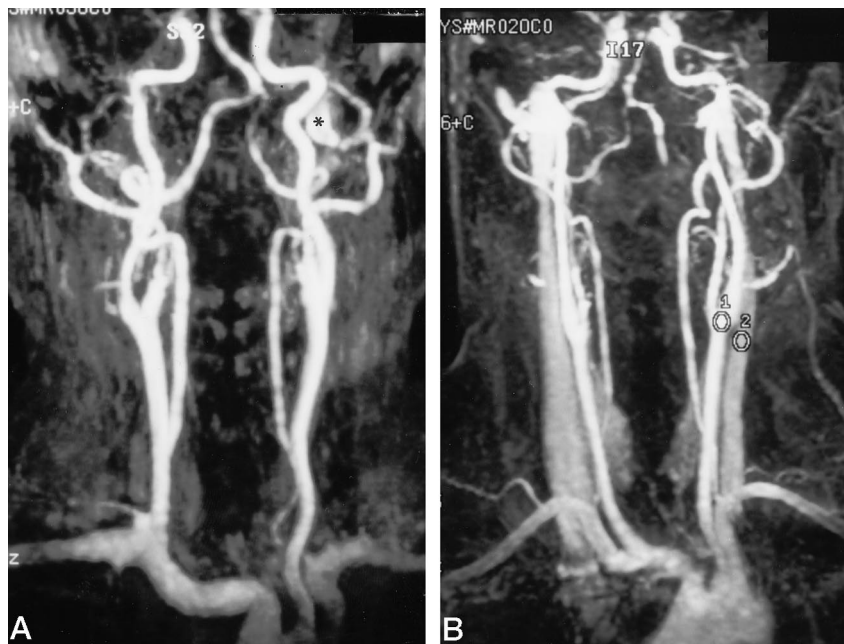


FIG 1. A, Double-dose (0.2 mmol/kg) contrast-enhanced dynamic coronal 3-D MR angiogram of the extracranial carotid and vertebral arteries shows selective arterial enhancement. Asterisk indicates flow-related enhancement in the left jugular bulb. Imaging parameters were 6.8/2.2/1 (TR/TE/excitations); flip angle, 44°; bandwidth, 31.3 kHz; FOV, 26 × 26 cm; matrix, 256 × 128; number of sections, 28; section thickness, 2 mm; acquisition time, 28 seconds; and maximum intensity projection (MIP) reconstruction.

B, Different patient with same injection-timing scheme as in A, in which we again attempted to match the arterial phase to low spatial frequency phase encodings, but with some venous enhancement, indicating suboptimal bolus timing relative to the center of k-space. Intraarterial signal is still greater than 2 SD from intravenous signal as measured at the carotid bifurcation. Imaging parameters were 7.2/2.1 (TR/TE); flip angle, 45°; bandwidth, 32 kHz; and acquisition time, 30 seconds; otherwise unchanged from those in A; and MIP reconstruction.

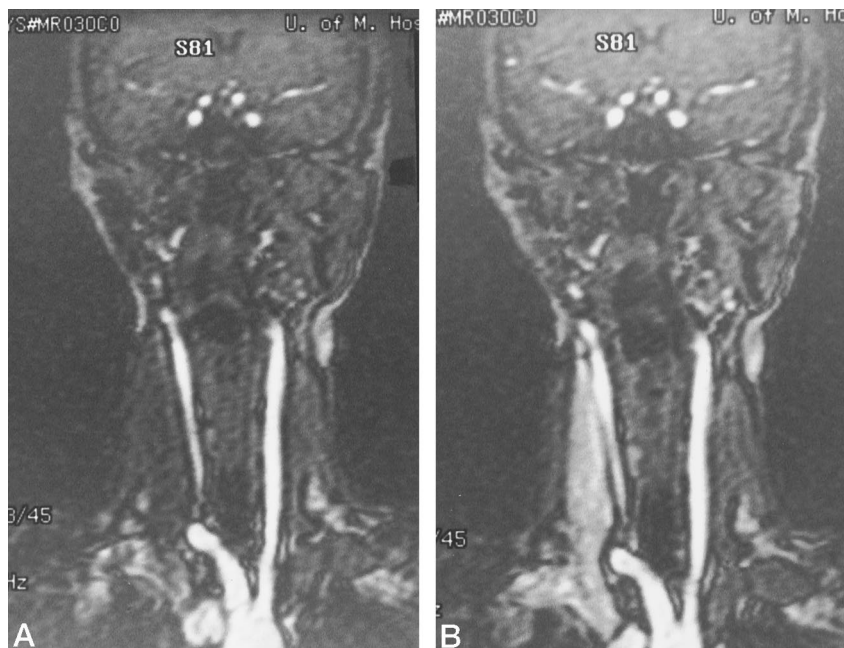


FIG 2. Single-dose (0.1 mmol/kg) dynamic coronal 3-D MR angiography of the extracranial carotid arteries. Corresponding 2-mm coronal source images from sequential 3-D MR angiographic sequences show arterial and arteriovenous enhancement from left (A) to right (B). In distinction to Figure 1, the contrast bolus begins at the start of scanning without precise timing of maximum arterial signal to the center of k-space. Imaging parameters were 6.2/2.2/0.5 (TR/TE/excitations); flip angle, 45°, bandwidth, 31.3 kHz; FOV, 32 × 24 cm; matrix, 256 × 128; number of sections, 16; section thickness, 2 mm; and 10 sequential imaging intervals of 6-second duration with a 1-second interscan delay.

## Results

As in prior investigations, selective arterial enhancement on the extracranial 3-D MR angiogram obtained by using the slower method of matching contrast bolus timing to the center of k-space was operator- and patient-dependent (2) (Fig 1). Intracranially, early and late arteriovenous phases could be demonstrated, as shown for a case of left internal carotid artery dissection in which progressive enhancement of the cavernous sinus and superior ophthalmic vein was observed. A potential pitfall of this method was observed during acquisition of a carotid 3-D MR angiogram in a child, in which a too-rapid

change in arterial contrast concentration during low spatial frequency phase encoding resulted in a ringing artifact (3, 4).

With the faster, thinner slab dynamic 3-D MR angiographic sequence, arterial, early arteriovenous, late arteriovenous, and washout arteriovenous phases for both the extra- and intracranial circulations could be demonstrated (Fig 2). This sequence enabled the contrast bolus to start at the beginning of scanning, eliminating the need for precise injection timing. A left occipital arteriovenous malformation exhibiting early and late arteriovenous enhancement was demonstrated. As expected, the 7-second temporal reso-

lution of this sequence did not resolve the arterial phase, consistent with a general cerebral arteriovenous circulation time of 2.5 to 6 seconds (5).

### Discussion

This study illustrates two methods of performing intra- and extracranial 3-D gradient-echo MR angiography with intravenous contrast enhancement. It must be emphasized that definitive correlation with other MR angiographic sequences has not yet been achieved, although our experience and that of others suggests that it is superior to 2-D TOF MR angiography in the extracranial circulation, especially in the evaluation of the aortic arch vessel origins (1). Its main advantage lies in the ability to image in the same plane as the vessels, yielding significant decreases in imaging time and saturation artifacts, as intravascular contrast is dependent on contrast-related T1 shortening rather than flow-related enhancement (2). Other flow-related artifacts, such as intravoxel spin dephasing in regions of turbulence, are also theoretically reduced by this technique, although this has not been rigorously proved. Contrast-enhanced dynamic 3-D MR angiography is thus advantageous over other MR angiographic techniques in reducing patient motion-related and flow-related artifacts, as well as in providing dynamic information regarding the arteriovenous circulation (ie, in the evaluation of arteriovenous fistulas). It can be rapidly performed before any study requiring contrast enhancement.

The operator dependence of the method has been demonstrated. While test-dose injection using a dynamic 2-D sequence would likely improve selective arterial enhancement by individualizing the time versus arteriovenous signal intensity difference profile, we have not routinely adopted this approach at our institution, mostly because of imaging time constraints (6).

The pitfalls of gradient-echo imaging are inherent in this form of MR angiography. These include TOF-related enhancement from inflow of unsaturated blood oblique or perpendicular to the imaging volume, and high signal methemoglobin from thromboses, particularly with arterial dissections. It remains to be seen if subtraction of pre-bolus 3-D volumes from the MR angiogram can solve these problems. Currently, visual inspection is relied upon. The fast dynamic 3-D MR angiographic sequence that allows 7-second temporal resolution removes the need for precise contrast injection timing. Ringing artifacts that can occur when central k-space data are acquired before peak arterial contrast concentration were not observed (3). This most likely relates to the rapidity with which low spatial frequency information is phase

encoded relative to the rate of change in contrast concentration. It must be emphasized that this dynamic 3-D MR angiographic sequence differs from others currently under investigation in that high and low spatial frequency information are sampled in a balanced fashion for each imaging interval. This is in distinction to current "keyhole" sequences, in which low spatial frequency information is sampled more frequently than high spatial frequency information (7), and in which significant postprocessing may be required.

The fast spoiled gradient-echo sequence is, itself, intrinsically limited in signal-to-noise ratio due to fractional radio frequency, fractional echo, and increased bandwidth considerations (8). The relatively small number of thin sections, the half-Fourier technique, and the rectangular FOV options used to achieve high spatial and temporal resolution in the faster method further decreased the signal-to-noise ratio. It is anticipated that double- or even triple-contrast doses will allow significantly greater intravascular signal to compensate for this.

### Acknowledgments

Appreciation is extended to Jane B. Mitchell and Diane Vanasupa for preparing the manuscript, to Bob Combs and Beth Doherty for photography, to Martin R. Prince and Thomas L. Chenevert for many helpful discussions, and to the entire MRI technical staff.

### References

1. Murphy KJ, Brunberg JA, Quint DJ, Cloft HJ, Prince MR. **Dynamic 3D gadolinium-enhanced MR angiography imaging of the origins of the innominate, carotid, and vertebral arteries compared with 2D TOF and catheter angiography.** *Proceedings of the 82nd Assembly and Annual Meeting of the Radiological Society of North America.* Oak Brook, Ill: Radiological Society of North America; 1996:134
2. Levy RA, Prince MR. **Arterial-phase three-dimensional contrast-enhanced MR angiography of the carotid arteries.** *AJR Am J Roentgenol* 1996;167:211-215
3. Maki JH, Prince MR, Londy FJ, Chenevert TL. **The effects of time varying intravascular signal intensity and k-space acquisition order on three-dimensional MR angiography image quality.** *J Magn Reson Imaging* 1996;6:642-651
4. Mistretta CA, Grist TM, Frayne R, Korosec FR. **Contrast and motion artifacts in 4D MR angiography.** *Proceedings of the 82nd Assembly and Annual Meeting of the Radiological Society of North America.* Oak Brook, Ill: Radiological Society of North America; 1996:328
5. Hilal SK. **Cerebral hemodynamics assessed by angiography.** In: Newton TH, Potts DG, eds. *Radiology of the Skull and Brain.* St Louis, Mo: Mosby; 1974:1057
6. Krinsky G, Rofsky N, Flyer M, et al. **Gadolinium-enhanced three-dimensional MR angiography of acquired arch vessel disease.** *AJR Am J Roentgenol* 1996;167:981-987
7. Korosec FR, Frayne R, Grist TM, Mistretta CA. **Time-resolved, contrast-enhanced 3D MR angiography.** *Magn Reson Med* 1996;36:345-351
8. Prorok RJ, Sawyer AM. *Signa Advantage Applications Guide.* Milwaukee, Wis: General Electric; 1992;4:20