

Are your **MRI contrast agents** cost-effective?

Learn more about generic **Gadolinium-Based Contrast Agents**.



**FRESENIUS
KABI**

caring for life

AJNR

Madelung disease: distribution of cervical fat and preoperative findings at sonography, MR, and CT.

A T Ahuja, A D King, E S Chan, J Kew, W W Lam, P M Sun, W King and C Metreweli

This information is current as of April 20, 2024.

AJNR Am J Neuroradiol 1998, 19 (4) 707-710
<http://www.ajnr.org/content/19/4/707>

Madelung Disease: Distribution of Cervical Fat and Preoperative Findings at Sonography, MR, and CT

A. T. Ahuja, A. D. King, E. S. Y. Chan, J. Kew, W. W. M. Lam, P. M. Sun, W. King, and C. Metreweli

PURPOSE: Our goal was to document the distribution of excess fat in the neck and to determine the preoperative role of sonography, CT, and MR imaging in patients with Madelung disease.

METHODS: Eight patients with Madelung disease were examined preoperatively with sonography, CT, and MR imaging of the neck, and the extent to which each technique provided answers to the surgeons' questions—such as distribution of fat, course of the major vessels within the fat, and presence of tracheal compression and nonlipomatous lesions—was studied.

RESULTS: Excess fat was seen predominantly in the posterior part of the neck (eight patients), under the trapezius (eight patients) and sternomastoid (six patients) muscles, in the supraclavicular fossa (five patients), between the paraspinal muscles (five patients), in the anterior part of the neck (suprahyoid in seven patients and infrahyoid in three patients), in the superior mediastinum (three patients), and in the prevertebral space (two patients). Excess fat deposition was also seen in the pretracheal space (one patient), extrapleural space (two patients), and over the cheeks (one patient), sites previously not described.

CONCLUSION: As a preoperative investigative tool for Madelung disease, both MR imaging and noncontrast CT provide the surgeon with adequate information; sonography is less helpful.

Madelung disease is characterized by the presence of multiple, symmetric, unencapsulated fatty accumulations diffusely involving the cervical and upper dorsal regions. The diagnosis is usually made on the basis of history and clinical appearance. Although successful medical treatment has been reported (1), in patients with disfigurement and tracheal narrowing the treatment of choice is surgery. Preoperative imaging plays an important role in defining the extent and distribution of fat, in locating the major head and neck vessels, in depicting tracheal narrowing and deformity, and in detecting incidental lesions in the neck.

Methods

Eight patients with Madelung disease were seen over a 2-year period. All the patients were men (age range, 46 to 68 years) with histories that included smoking (eight patients), alcoholic liver cirrhosis (seven patients), diabetes (three pa-

tients), hypotension (three patients), and gout (one patient). All patients had had multiple cervical lipomatosis for more than 3 years, and two had recurrent disease following previous liposuction. One patient reported shortness of breath and difficulty in swallowing.

All patients underwent imaging of the neck with sonography, CT, and MR imaging. Sonography was performed using an ATL HDI 3000 unit (Bothell, Wash) and a 10-MHz linear transducer. CT was performed on a GE High-Speed Advantage unit (Milwaukee, Wis), on which 10-mm contiguous sections were obtained with a 25- to 28-cm field of view (FOV), 120 kV, and 220 mAs. MR imaging was performed on a 1.5-T Phillips Gyroscan (Eindhoven, the Netherlands) using a neck coil to acquire T1-weighted spin-echo images in the coronal, axial, and sagittal planes with parameters of 500/20 (TR/TE), a 22-cm FOV, 5-mm section thickness with no intersection gap, and a 205 × 256 matrix.

All the sonographic examinations were performed by the same radiologist, whereas the CT and MR examinations were reviewed independently by two radiologists, who resolved disagreements by consensus. The regions evaluated for distribution of fat are listed in the Table. The extent to which each of the three techniques depicted the distribution of fat was divided into three categories: not defined, poorly defined, and well defined. *Well defined* indicated depiction of excess fat and its extent; *poorly defined* indicated depiction of excess fat but not its extent.

Results

Comparative findings of the demonstration and distribution of excess fat on sonographic, CT, and

Received August 27, 1997; accepted after revision November 21.
From the Departments of Diagnostic Radiology & Organ Imaging (A.T.A., A.D.K., J.K., W.W.M.L., P.M.S., C.M.) and Surgery (E.S.Y.C., W.K.), The Chinese University of Hong Kong, Prince of Wales Hospital.

Address reprint requests to Dr. Anil T. Ahuja, Department of Diagnostic Radiology & Organ Imaging, The Chinese University of Hong Kong, Prince of Wales Hospital, Shatin, NY, Hong Kong.

Demonstration and distribution of excess fat on sonographic, CT, and MR studies

Distribution of Fat	No. (%) of Patients with Excess Fat	Sonography	CT	MR Imaging
Deep to sternomastoid	6 (75)	Poorly defined	Well defined	Well defined
Deep to trapezius	8 (100)	Poorly defined	Well defined	Well defined
Subcutaneous tissues along posterior part of neck	8 (100)	Poorly defined	Well defined	Well defined
Between paraspinal muscles	5 (63)	Poorly defined	Well defined	Well defined
Subcutaneous tissues along anterior part of neck, suprahyoid	7 (88)	Well defined	Well defined	Well defined
Subcutaneous tissues along anterior part of neck, infrahyoid	3 (38)	Well defined	Well defined	Well defined
Supraclavicular fossa	5 (63)	Poorly defined	Well defined	Well defined
Sternal notch	5 (63)	Poorly defined	Well defined	Well defined
Cheeks	1 (13)	Poorly defined	Well defined	Well defined
Mediastinum	3 (38)	Poorly defined	Well defined	Well defined
Extrapleural	2 (25)	Not defined	Poorly defined	Well defined
Pretracheal	1 (13)	Poorly defined	Well defined	Well defined
Prevertebral	2 (25)	Not defined	Well defined	Well defined

Note.—None of the techniques showed excess fat in the skull base, tongue, parapharyngeal fat space, pre-epiglottic space, tracheoesophageal groove, or carotid sheath.

MR studies in various regions within the neck are described in the Table. Calcification or ossification within the lipomatous deposits was not seen. All three techniques showed a lack of vascular involvement in all the patients. Airway involvement was seen in two patients: in one, the trachea was displaced to the right by mediastinal fat, but there was no airway compromise; in the other, the airway was narrowed by a laryngeal carcinoma and not by excess fat. CT and MR imaging showed the airway involvement in both cases, whereas sonography missed the laryngeal carcinoma. All three techniques identified a branchial cyst that was present in one patient.

Discussion

Madelung disease usually occurs in middle-aged men of Mediterranean descent with a significant history of alcohol abuse. Although uncommon in Chinese populations, Asian patients with this disease have been reported (2, 3). Benign, symmetric lipomatosis was initially described in 1846 by Brodie (4). Madelung subsequently reported 33 patients with cervical lipomatosis (5), and Launois and Bensaude (6) further defined this syndrome as the presence of multiple, symmetric unencapsulated fatty accumulations diffusely involving the cervical and upper dorsal regions, the abdomen, and the groin. Radiologic manifestations of this disease include lipomatosis of the neck and mediastinum, calcification/ossification within lipomatous masses, tracheal narrowing and deformity, and venous stasis. Fatty deposition has not been shown to occur in the pericardium, abdomen, or pelvis (7). The lipomatous deposits are often large and cosmetically deforming, and the upper aerodigestive tract may be compressed, causing dyspnea and dysphagia. The cause of benign, symmetric lipomatosis is unknown, but it has been associated with alcoholism in 60% to 90% of patients. Hyperuricemia, gout, liver disease, polyneuropathy, diabetes mellitus,

glucose intolerance, peripheral insulin resistance, renal tubular acidosis, hypertension, hypothyroidism, and hyperlipidemia have occasionally been identified in patients with Madelung disease, some of whom have no history of alcoholism (3).

The surgical treatment of Madelung disease is either open lipectomy or liposuction. Both procedures are mainly palliative and carry a significant rate of recurrence. Liposuction can be performed with a small surgical incision only if the fatty mass is not closely adherent to the major vessels or compressing the airway. Preoperatively, the surgeon requires information that can only be obtained by imaging. Specifically, he or she needs to know the distribution of fat, the course of the major vessels within the fat, whether there is tracheal narrowing/deformity, and whether there are any other incidental lesions in the neck. Of these, the most important concern is the distribution of fat in the neck.

Distribution and Extent of Fat

Previous reports have described the gross distribution of fat in the neck in patients with Madelung disease, but they have not closely evaluated the distribution of infiltration (7). In our series, fat deposition was most predominant posteriorly in the subcutaneous tissues (100%) of the neck, and deep to the sternomastoid (75%) (Fig 1) and trapezius (100%) muscles. Fat was also commonly seen in the supraclavicular fossa (63%), around the paraspinal muscles (63%), in the anterior subcutaneous tissues of the neck (Fig 2) above (88%) and below (38%) the level of the hyoid, superior mediastinum (38%), and in the prevertebral space (25%). Although the fat was primarily distributed posteriorly, this was not always the site of maximum fat deposition (Fig 3). Fat was also detected in the pretracheal space (one patient), in the extrapleural space (two patients) (Fig 4), and over the cheeks (one patient), sites previously not described.

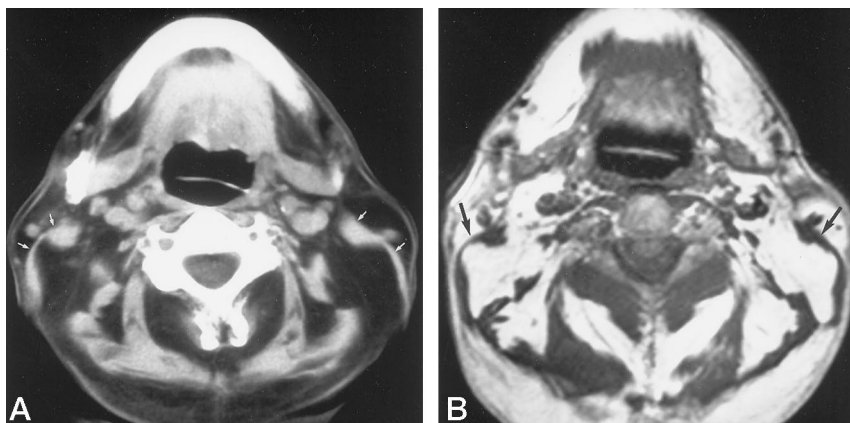


FIG 1. Axial noncontrast CT scan (A) and T1-weighted MR image (500/20) (B) show a thin sternomastoid muscle (arrows) with excess fat posteriorly. Also note the paraspinal distribution of the fat.

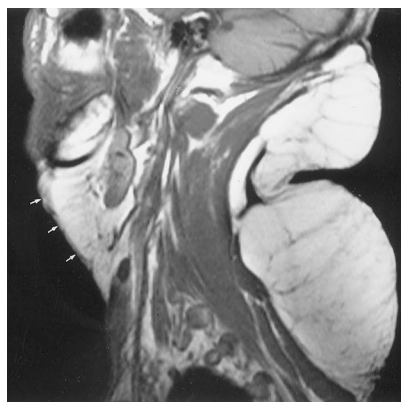


FIG 2. Sagittal T1-weighted MR image (500/20) shows excess fat in the neck posteriorly and in the submental, submandibular space anteriorly (arrows).

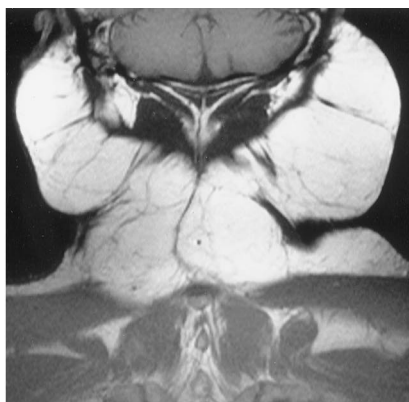


FIG 3. Coronal T1-weighted MR image (500/20) shows excess fat in the neck posteriorly and laterally. Although fat is present posteriorly, the site of maximum deposition is in the soft tissues laterally.

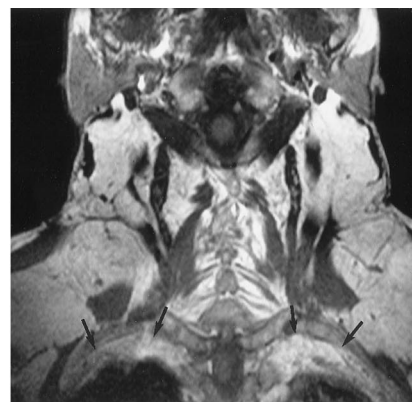


FIG 4. Coronal T1-weighted MR image (500/20) shows the presence of excess extrapleural fat bilaterally (arrows).

We did not detect any fat within the tracheoesophageal groove or within the carotid sheath.

We were also interested in whether abnormal amounts of fat were present in sites in which fat is normally located. None of our patients had abnormal amounts of fat in the tongue, parapharyngeal fat space, spinal canal, salivary glands, or preepiglottic space. Muscle infiltration was not seen, although compression was noticed particularly in the trapezius and sternocleidomastoid muscles.

Preoperatively, sonography detected the presence of fat in the neck, but as the fat is unencapsulated it was unable to define the degree of infiltration. Noncontrast CT and MR imaging both adequately demonstrated the distribution of fat in the neck, although MR appeared to be superior to CT in depicting the extent of involvement, particularly into the mediastinum and extrapleural region, which may be due to the different parameters used (10-mm contiguous sections and a 25- to 28-mm FOV for CT compared with a 5-mm section thickness and a 22-mm FOV for MR imaging).

Course of Major Vessels within the Fat

Sonography showed the major vessels in the neck, their course, and their relationship to lipomatous tis-

sue in the anterior part of the neck. However, posteriorly and in the superior mediastinum, sonography was inadequate in depicting the vessels. Noncontrast CT and MR imaging showed the relationship of fat to all the major vessels in the neck and mediastinum, but MR has the added advantage over CT of being able to show the entire course of the vessels in one plane.

Tracheal Narrowing and Deformity

CT and MR imaging were able to detect compression and deviation of the trachea and esophagus, which sonography could not. Once again, MR imaging had the added advantage over CT of being able to depict the entire larynx of the trachea in either the coronal or sagittal plane. Although direct involvement of the larynx by proliferating adipose tissue is rare, it has been demonstrated on CT studies (8).

Detection of Nonlipomatous Lesions in the Neck

Two patients in our study had nonlipomatous lesions in the neck. In the one symptomatic patient with dyspnea and dysphagia, both CT and MR imaging correctly identified the presence of a laryngeal carcinoma. The other patient had an asymptomatic branchial cyst, shown by all three imaging studies.

Sonography is inexpensive, readily available, and easily combined with fine-needle aspiration biopsy, but it does not provide surgeons with all the preoperative information they require, as do both CT and MR imaging. Although CT is quicker and cheaper than MR imaging, it may require contrast injection and scans may be available only in the axial plane. MR imaging, on the other hand, is multiplanar, but calcification or ossification, if present, are better seen with CT.

Conclusion

This study draws attention to the characteristic sites of fat distribution in the neck in patients with Madelung disease. As a preoperative investigation for Madelung disease, both MR imaging and noncontrast CT can provide the surgeon with adequate information.

References

1. Kohan D, Miller PJ, Rothstein SG, Kaufman D. **Madelung' disease: case reports and literature review.** *Otolaryngol Head Neck Surg* 1993;108:156-159
2. John DJ, Fung HK, Van Hasselt CA, King WW. **Multiple symmetrical lipomatosis in the neck.** *Eur Arch Otorhinolaryngol* 1992;249:277-278
3. Kitano H, Nakanishi Y, Takauchi F, Nagahora K. **Multiple symmetrical lipomatosis: no longer a Mediterranean disease.** *ORL J Otorhinolaryngol Relat Spec* 1994;56:177-180
4. Brodie BC. *Clinical Lectures on Surgery Delivered at St George's Hospital.* Philadelphia: Lea and Blanchard; 1846:201
5. Madelung OW. **Ueber Den Fetthals.** *Archi Fuer Klinische Chirurgie* 1888;37:106-130
6. Launois PE, Bensaude R. **L'Adenolipomatose symetrique.** *Bull Mem Soc Med Hosp Paris* 1898;1:298-318
7. Taybi H, Lachman RS. *Radiology of Syndromes, Metabolic Disorders and Skeletal Dysplasias*, 4th ed., Chicago: Yearbook Medical; 1996; 282-283
8. Borges A, Torrinha F, Lufkin RB, Abemayor E. **Laryngeal involvement in multiple symmetric lipomatosis: the role of computed tomography in diagnosis.** *Am J Otolaryngol* 1997;18:127-130