

Are your **MRI contrast agents** cost-effective?

Learn more about generic **Gadolinium-Based Contrast Agents**.



**FRESENIUS
KABI**

caring for life

AJNR

Sex and electroencephalographic synchronization after photic stimulation predict signal changes in the visual cortex on functional MR images.

P Hedera, D Wu, S Collins, J S Lewin, D Miller, A J Lerner, S Klein and R P Friedland

This information is current as of April 18, 2024.

AJNR Am J Neuroradiol 1998, 19 (5) 853-857
<http://www.ajnr.org/content/19/5/853>

Sex and Electroencephalographic Synchronization after Photic Stimulation Predict Signal Changes in the Visual Cortex on Functional MR Images

Peter Hedera, Dee Wu, Steve Collins, Jonathan S. Lewin, David Miller, Alan J. Lerner, Susan Klein, and Robert P. Friedland

PURPOSE: We evaluated factors that influence MR signal changes during photic stimulation of the visual cortex. We also tested the hypothesis that functional MR imaging response corresponds to electroencephalographic (EEG) synchronization after photic stimulation.

METHODS: Thirty-eight healthy subjects, 20 men and 18 women, underwent photic stimulation of the visual cortex. They were studied with a 1.5-T MR unit, and photic stimulation was induced via 8-Hz LED goggles. Seven subjects with and seven without detectable functional MR imaging response to photic stimulation underwent further studies with 16-channel EEG after 2- to 30-Hz stroboscopic stimulation.

RESULTS: Thirteen men and 18 women had a significant increase in MR signal in the visual cortex; seven men showed no visual cortex activation during more than two repeated studies. Six of seven volunteers with increased functional MR imaging signal after photic stimulation also showed signs of EEG synchronization when an 8-Hz stroboscopic flash was used; six of seven subjects with no functional MR imaging lacked EEG synchronization at 8-Hz stimulation.

CONCLUSIONS: Men were more likely than women to have undetectable MR signal changes after photic stimulation. This finding should be considered when interpreting results of functional MR imaging studies. EEG with stroboscopic examination is a good predictor of functional MR imaging sensitivity to changes in regional cerebral blood flow induced by sensory stimulation.

Functional magnetic resonance (MR) imaging with its ability to show activated brain regions noninvasively has become widely accepted as an effective tool in neuroimaging. Photic stimulation causes marked increase of MR signal in the occipital cortex, an area of the brain that has been studied extensively with functional MR imaging (1–8). Our group has also focused on the study of visual cortex activation using 1.5-T gradient-echo MR imaging (6, 9), and we have noticed that MR signal changes cannot be

detected in every healthy volunteer studied after photic stimulation.

Stroboscopic light has been widely used as an activation method during electroencephalographic (EEG) tracing (10). Although both EEG and regional cerebral blood flow (rCBF) have been linked to neuronal activity, their relationship remains uncertain; however, changes in the brain's metabolic activity have shown close correlation with changes in electrophysiological activity (11).

Functional MR imaging has significant potential for routine clinical use, and an understanding of MR signal variability under physiological conditions has become increasingly important. The goal of this study was to evaluate factors that influence MR signal changes during photic stimulation of the visual cortex. We also tested the hypothesis that functional MR imaging response corresponds to EEG synchronization after photic stimulation.

Methods

Thirty-eight healthy subjects who gave informed consent were included in the study. The group consisted of 20 men and

Received May 9, 1997; accepted after revision October 6.

Supported in part by National Institutes of Health grant AG 08012–05 and Philip Morris USA.

From the Departments of Neurology (Laboratory of Neurogeriatrics) (P.H., A.J.L., R.P.F.), Radiology (D.W., J.S.L., D.M.), Neurology (S.C.), and Psychology (S.K.) Case Western Reserve University/University Hospitals of Cleveland (Ohio); and the Department of Medicine, Division of Neurology, St Luke's Medical Center, Cleveland (A.J.L.).

Address reprint requests to Robert P. Friedland, MD, Department of Neurology, Case Western Reserve University, 11100 Euclid Ave, Cleveland, OH 44106. E-mail: rpf2@po.cwru.edu

18 women with an average age of 26 ± 6 years (range, 19 to 38 years; average age of men, 27 ± 5 years; average age of women, 25 ± 4 years). The subjects were studied at 1.5 T with a 5-inch circular surface coil. Anatomic images of the occipital cortex were collected in a sagittal plane using a T1-weighted three-dimensional radio frequency spoiled fast low-angle shot (FLASH) sequence with TR/TE of 17/6, a flip angle of 20° , a field of view of 256 mm, a matrix size of 192×256 , and 64 partitions, leading to contiguous 2-mm-thick sections. Functional MR images were obtained with a susceptibility-sensitized two-dimensional FLASH sequence. The sequence included first-order flow compensation in section-select and readout directions, a low bandwidth of 98 Hz per pixel to increase the signal-to-noise ratio, TR/TE of 67/40, a flip angle of 25° , a field of view of 256 mm, and a matrix size of 128×128 (12).

Every subject underwent binocular photic stimulation of the primary visual cortex with LED goggles (Grass Instruments, Quincy, Mass); the stimulus was a flashlight at a frequency of 8 Hz (13). The plane of the calcarine fissure was covered by a 4-mm section. Before photic stimulation we collected five resting images in complete darkness with the subjects' eyes closed. The subjects were then exposed to a stroboscopic light for 49 seconds, during which five functional images were collected. Preliminary assessment of visual cortex activation was made by subtracting the activated images from the resting images. When signal changes were detected on the subtracted images, the same cycle was repeated. If activation was reproduced, the subjects were included in studies of visual (6, 9, 14) or motor (12, 15) cortex activation and of cerebrovascular reactivity (16). All subjects with positive signal increases were involved in at least one more study protocol that entailed photic stimulation of the visual cortex.

Subjects who showed no signs of signal changes at the level of the calcarine fissure after the first photic stimulation and in whom the subtraction images revealed no significant movement were studied further. The whole occipital cortex was screened with 4-mm sections parallel to the calcarine fissure and the position was shifted 2 mm between each study. When this did not yield signal changes, the section angle was modified by 5° ; the whole cycle was repeated until we detected MR signal induced by photic stimulation or until the whole occipital cortex was covered from 180° to 90° . The possibility of gross head movement was evaluated by judging the degree of overlap of the subtracted images. The mean pixel intensity of activated images was subtracted from the mean pixel intensity of preactivated images. Movement artifacts were evidenced by increased or decreased signal creating complete or partial rings along the margins of the brain, ventricles, or skull (17). When gross head movement was detected, we repeated the scout scan of the occipital lobe in the parallel orientation and the whole protocol was restarted. Subjects without detectable response to photic stimulation were restudied in at least two more sessions, each at least 1 week apart. For three nonresponders, we made three more unsuccessful attempts to detect activation of the visual cortex. We decided to reduce the number of repeat studies to two in the rest of the nonresponders because of the consistent findings in first three volunteers. The protocol for identifying MR signal was unchanged.

All seven subjects without inducible MR signal increase and seven randomly chosen age-matched subjects with inducible MR signal increases underwent routine 16-channel EEG examination. This also included photic stimulation with stroboscopic light stimulation at 2, 5, 8, 10, 12, 15, and 20 Hz during longitudinal bipolar montage tracing; photic stimulation lasted 10 seconds, with a resting interval between frequencies of 20 seconds. Part of the photic stimulation was performed with LED goggles at a frequency of 8 Hz. EEG and MR imaging were performed within a 1-week period.

EEG recordings were interpreted by one of the investigators, who was blinded to the results of the functional MR imaging studies. A driving response was present when a time-

locked synchronous activity over parietooccipital regions was detected; we also required that EEG frequency be either equal to or harmonic with flash frequency.

Fox and Raichle (13) reported maximum change of rCBF with 8-Hz photic stimulation; the second peak was seen with a 15-Hz stimulus. Three subjects from each group (nonresponders and responders) were also stimulated with flashing light at the frequency of 15 Hz to determine whether a change in frequency influences detectability of MR response. These subjects were selected because they had synchronous EEG activity during photic stimulation with a 15-Hz stroboscopic light.

MR images were processed using a SunSparc station 2 (Sun Microsystems, Mountain View, Calif). Accepted images without gross head movements (see above) were corrected by a motion registration algorithm for possible rotational and translational motion within the imaging plane (17). A region of interest including the visual cortex and excluding the cerebral venous sinuses was drawn for each subject. Student's *t* test was applied on a pixel-by-pixel basis on the original activated images. The standard deviation used for the *t* test was determined from variation of the baseline signal. Pixels with signal changes at the level of significance ($\alpha = .01$ and higher) were considered activated by photic stimulation. Moreover, a minimum of seven contiguous pixels was required for confirmation of the visual cortex activation (18).

Activation of the visual cortex was first dichotomized as absent or present and in this way subjects were considered to be responders or nonresponders. The average percentage value of signal changes from the baseline was calculated from all activated pixels in responders; pixels corresponding to cerebral venous sinuses were excluded. Both groups were compared using Fisher's Exact Test and Student's *t* test. Subjects with EEG studies were also divided into two subgroups: those with and those without a driving response at different flashing frequencies. We also analyzed the relationship between EEG synchronization and MR activation by Fisher's Exact Test.

Results

Photic stimulation induced a significant MR signal increase in 31 of 38 subjects (13/20 men and 18/18 women; average age, 28 ± 6 years) (Fig 1). Of the 31

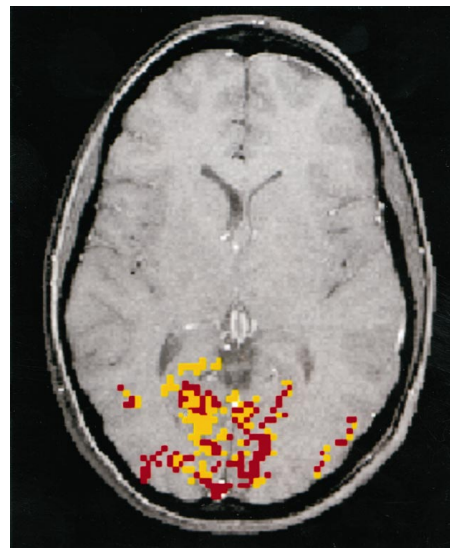


FIG 1. Overlay of activated areas of the visual cortex on T1-weighted MR image shows a typical pattern of activation in the occipital lobe after photic stimulation. Functional data are color coded for $P \leq .01$ (yellow) and $P \leq .001$ (red).

signal changes at tissue boundaries, which were indicative of significant head movement (17). Therefore, it is unlikely that the absence of signal in the male volunteers was simply the result of technical artifacts due to head movements or poor motivation. More likely, the lack of signal increase after photic stimulation was caused by small rCBF increases that were below the detectability threshold of the 1.5-T field strength of functional MR imaging. The average percentage of signal increase to photic stimulation was also higher in women. Although women generally have higher values of resting rCBF, including occipital rCBF (21–23), functional MR imaging is relatively independent of the absolute values of rCBF. Functional MR imaging can mainly assess the difference in fractional blood oxygenation, which reflects the relative increase of deoxyhemoglobin, between active and resting states (1, 2). Even though gender differences are least prominent after activation of the primary cortices (21, 22), our results suggest that women may have slightly higher increases of occipital rCBF during processing of simple visual stimuli.

One study compared functional MR imaging response to photic stimulation in similar groups of eight men and women and found higher signal changes in male subjects (24). Average activation in men was $5.0 \pm 1.4\%$ (average for our group of male volunteers was $3.11 \pm 1.35\%$); average activation in women was $3.1 \pm 1.4\%$ (average for our group of female volunteers was $4.64 \pm 1.86\%$). Levin and coworkers used the same mode of photic stimulation; however, in contrast to our method, they used echo-planar imaging at a field strength of 1.5 T. The reason for the differences in results between that study and ours is unclear, although differences in imaging techniques may be partially responsible. Further studies are needed to confirm gender differences in activation of the primary visual cortex. Nevertheless, the existence of different thresholds in detectability of MR signal between men and women must be taken into consideration in any clinical interpretation of studies obtained with 1.5-T gradient-echo functional MR imaging.

The other principal finding of this study is the association between EEG synchronization of background activity with an 8-Hz flashing light and detectability of MR signal changes induced by the same frequency of stimulation. Although any relationship between scalp EEG (ie, a summation of excitatory and inhibitory postsynaptic potentials) and rCBF remains speculative, both parameters reflect brain metabolism, and several studies have reported a connection between them (25). Hyperventilation resulting in hypocapnia is known to cause generalized EEG slowing in healthy subjects, and lower values of rCBF have been demonstrated during decreased arterial carbon dioxide tension (26–28), suggesting that slowing of EEG frequencies may be a result of reduced rCBF. Coupling of EEG and rCBF has also been demonstrated in focal epilepsy during ictal and interictal periods (29–31), and changes of occipital rCBF positively correlate with occipitoparietal synchronization on EEG recordings (32). Our results showing a pos-

itive correlation between EEG synchronization and detectability of signal changes on functional MR images after photic stimulation at 8 Hz suggest that an increase of rCBF in the visual cortex is lower when the same frequency of stroboscopic light does not induce occipitoparietal synchronization on EEGs. However, studies of three nonresponders who had signs of a driving response on EEG with 15-Hz photic stimulation did not yield a positive MR signal after the same frequency was used for visual cortex activation. Fox and Raichle (13) have shown that changes of occipital rCBF varied with the stimulation frequency and that the maximum change was observed at 7.8 Hz, with the second highest increase present at 15 Hz of intermittent light stimulation. We also found a tendency toward lower MR signal increase with 15-Hz stimulation as compared with 8-Hz stimulation in our responders, consistent with previous studies using PET (13) and functional MR imaging (2). The absence of detectable MR signal in men with EEG synchronization at 15 Hz may be due to an insufficient increase of rCBF, which is below the detection threshold of the 1.5-T magnetic field. Use of a stronger magnetic field will be necessary to confirm whether stimulation with 15 Hz induces greater signal changes when it coincides with EEG synchronization.

Conclusion

Our results, despite two limitations (ie, qualitative estimation of rCBF changes only and inability to obtain EEG recordings during the MR study), suggest that intermittent light stimulation causes a greater increase of rCBF in the visual cortex when it is associated with occipitoparietal EEG synchronization. EEG with stroboscopic examination is a good predictor of functional MR imaging sensitivity to rCBF changes induced by sensory stimulation. We also found that detectability of MR response in men was significantly lower than that in women. The possibility of a higher threshold for detection of brain activation in men must be taken into account when interpreting functional MR images obtained at a field strength of 1.5 T.

References

- Ogawa S, Tank DW, Menon R, et al. **Intrinsic signal changes accompanying sensory stimulation: functional brain mapping with magnetic resonance imaging.** *Proc Natl Acad Sci U S A* 1992;89:5951–5955
- Kwong KK, Belliveau JW, Chestler DA, et al. **Dynamic magnetic resonance imaging of human brain activity during primary sensory stimulation.** *Proc Natl Acad Sci U S A* 1992;89:5675–5679
- Frahm J, Bruhn H, Merboldt K-D, Hänicke W. **Dynamic MR imaging of human brain oxygenation during rest and photic stimulation.** *J Magn Reson Imaging* 1992;2:501–505
- Schneider W, Noll DC, Cohen JD. **Functional topographic mapping of the cortical ribbon in human vision with conventional scanners.** *Nature* 1993;365:150–153
- Le Bihan D, Turner R, Zeffiro TA, Cuenod CA, Jezzard P, Bonnerot V. **Activation of human primary visual cortex during visual recall: a magnetic resonance imaging study.** *Proc Natl Acad Sci U S A* 1993;90:11802–11805
- Hedera P, Lai S, Haacke EM, et al. **Abnormal connectivity of the visual pathways in human albinos demonstrated by susceptibility**

- sensitized magnetic resonance imaging. *Neurology* 1994;44:1992–1926
7. Sereno MI, Dale AM, Reppas JB, et al. **Borders of multiple visual areas in humans revealed by functional magnetic resonance imaging.** *Science* 1995;268:889–893
 8. Tootell RB, Reppas JB, Kwong KK, et al. **Functional analysis of human MT and related visual cortical areas using magnetic resonance imaging.** *J Neurosci* 1995;15:3215–3230
 9. Hedera P, Wu D, Lewin JS, Miller D, Lerner AJ, Friedland RP. **Temporal patterns of uncoupling between oxidative metabolism and regional cerebral blood flow demonstrated by functional magnetic resonance imaging.** *Invest Radiol* 1995;30:625–633
 10. Coull BM, Pedley TA. **Intermittent photic stimulation: clinical usefulness of non-convulsive response.** *Electroencephalogr Clin Neurophysiol* 1978;44:353–363
 11. Paulson OB, Sharrbough FW. **Physiologic and pathophysiologic relationship between the electroencephalogram and the regional cerebral blood flow.** *Acta Neurol Scand* 1974;50:194–220
 12. Lai S, Hopkins AL, Haacke EM, et al. **Identification of vascular structures as a major source of signal contrast in high resolution 2D and 3D functional activation imaging of the motor cortex at 1.5 T: preliminary results.** *Magn Reson Med* 1993;30:387–392
 13. Fox PT, Raichle ME. **Stimulus rate dependence of regional cerebral blood flow in human striate cortex, demonstrated by positron emission tomography.** *J Neurophysiol* 1984;51:1109–1120
 14. Hedera P, Lai S, Haacke EM, Hopkins AL, Friedland RP, Friedman L. **High-resolution GRE functional imaging of visual cortex.** Presented at the annual meeting of the Radiological Society of North America, Chicago, Ill, September 1993
 15. Haacke EM, Hopkins A, Lai S, et al. **2D and 3D high resolution gradient echo functional imaging of the brain: venous contributions to signal in motor cortex study.** *NMR Biomed* 1994;6:54–62
 16. Hedera P, Lai S, Lewin JS, et al. **Assessment of cerebral blood flow reserve using functional magnetic resonance imaging.** *J Magn Reson Imaging* 1996;6:718–725
 17. Lewin JS, Friedman L, Wu D, et al. **Cortical localization of human sustained attention: detection with functional MR using a visual vigilance paradigm.** *J Comput Assist Tomogr* 1996;20:695–701
 18. Wu D, Lewin JS. **Nonparametric measures and data clustering for functional MR data.** Presented at the annual meeting of the Society for Magnetic Resonance, San Francisco, Calif, August 1994
 19. Fox PT, Mintun MA, Raichle ME, Miezin FM, Allman JM, Van Essen DC. **Mapping human visual cortex with positron emission tomography.** *Nature* 1986;323:806–809
 20. Fox PT, Miezin FM, Allman JM, Van Essen DC, Raichle ME. **Retinotopic organization of human visual cortex mapped with positron emission tomography.** *J Neurosci* 1987;7:913–922
 21. Gur RC, Gur RE, Obrist WD, Skolnick BE, Reivich M. **Age and regional cerebral blood flow at rest and during cognitive activity.** *Arch Gen Psychiatry* 1987;44:617–621
 22. Gur RC, Gur RE, Obrist WD, et al. **Sex and handedness differences in cerebral blood flow during rest and cognitive activity.** *Science* 1982;217:659–661
 23. Esposito G, Weinberger DR, Van Horn JD, Ostrem JL, Berman KF. **Do women have more active brains than men? a PET study during cognitive activation.** Presented at the annual meeting of the Society Neuroscience, Washington, DC, November 1993
 24. Levin JM, Ross MH, Mendelson JH, Mello NK, Cohen BM, Renshaw PF. **Gender differences in BOLD response to photic stimulation.** Presented at the annual meeting of the Society for Magnetic Resonance, Nice, France, August 1995
 25. Paulson OB, Sharrbough FW. **Physiologic and pathophysiologic relationship between the electroencephalogram and the regional cerebral blood flow.** *Acta Neurol Scand* 1974;50:194–220
 26. Olesen J, Paulson OB, Lassen NA. **Regional cerebral blood flow in man determined by the initial slope of the clearance of intrarterially injected ^{133}Xe .** *Stroke* 1971;2:519–540
 27. Greenberg J, Alavi A, Reivich M, Kuhl D, Uzzell B. **Local cerebral blood volume response to carbon dioxide in man.** *Circ Res* 1978;43:324–331
 28. Ellingsen I, Hauge A, Nicolaysen G, Thoresen M, Walloe I. **Changes in human cerebral blood flow due to step changes in $\text{P}_{\text{A}}\text{O}_2$ and $\text{P}_{\text{A}}\text{CO}_2$.** *Acta Physiol Scand* 1987;129:157–163
 29. Hougaard K, Oikawa T, Sveinsdottir E, Skonhoj E, Ingvar DH, Lassen A. **Regional cerebral blood flow in focal cortical epilepsy.** *Arch Neurol* 1976;33:527–535
 30. Sakai F, Meyer JS, Naritomi H, Hsu MC. **Regional cerebral blood flow and EEG in patients with epilepsy.** *Arch Neurol* 1978;35:648–657
 31. Valmier J, Touchon J, Baldy-Moulinier M. **Interictal regional cerebral blood flow during non specific activation test in partial epilepsy.** *J Neurol Neurosurg Psychiatry* 1989;52:364–371
 32. Naquet R, Menini C, Cepada C. **Mechanism of appearance of paroxysmal responses induced by intermittent light stimulation.** In: Akimoto H, Kazamatsuri H, Seino M, Ward AA, eds. *Advances in Epileptology (XIIIth Symposium)* 1982;249–254

Please see the Editorial on page 991 in this issue.