

Are your **MRI contrast agents** cost-effective?

Learn more about generic **Gadolinium-Based Contrast Agents**.



**FRESENIUS  
KABI**

caring for life

**AJNR**

**Colloid cyst of the third ventricle: sometimes more conspicuous on CT than MR.**

A C Mamourian, L D Cromwell and R E Harbaugh

*AJNR Am J Neuroradiol* 1998, 19 (5) 875-878

<http://www.ajnr.org/content/19/5/875>

This information is current as of April 19, 2024.

## Colloid Cyst of the Third Ventricle: Sometimes More Conspicuous on CT than MR

Alexander C. Mamourian, Laurence D. Cromwell, and Robert E. Harbaugh

**Summary:** We present two cases of surgically proved colloid cysts that were more apparent on CT scans than on MR images. These cysts, while hyperdense on CT scans, were nearly isointense with brain on multiple MR sequences. This relative lack of visibility represents a potential pitfall when imaging a patient with headache.

Colloid cysts, while uncommon, are important to identify correctly because of their association with sudden death. They are relatively rare and account for less than 1% of all brain tumors in adults. Their name reflects the typical contents of the cyst, from the Greek word *kollodes* (resembling glue). They are histologically benign, but their midline location may lead to obstruction of the foramen of Monro and to hydrocephalus. While MR imaging has replaced CT for many if not most indications in CNS disease, we encountered two colloid cysts that were quite evident on CT scans but less apparent on MR images. Both were proved at surgery.

### Case Reports

#### Case 1

A 36-year-old man had a 10-year history of headaches that had increased in intensity during the month prior to admission and that had become associated with flashing lights in all visual fields. Physical examination was unremarkable except for a mild facial droop at rest. CT scans showed a high-attenuation lesion in the anterior third ventricle, consistent with a colloid cyst (Fig 1). MR imaging was performed, but the tumor was difficult to detect, even with additional sequences, which included intermediate and T2-weighted axial and coronal studies. Imaging parameters were 2000/30,85/0.5 (TR/TE/excitations) and 650/25/2 for conventional spin-echo sequences and 3000/108/2 and 3000/36/2 for fast spin-echo sequences with a 256 × 192 matrix. Coronal T2-weighted and intermediate fast spin-echo sequences were also acquired at parameters of 3000/34 and 3000/102. Section thickness on the T2-weighted, intermediate, and T1-weighted axial images was 8 mm with a 2-mm gap. Sagittal images (400/24) were obtained with a section thickness of 5 mm and a 2-mm gap. Coronal and axial images (650/25) had a section thickness of 8 mm with a 2-mm gap. Contrast-enhanced images were also obtained.

Surgery, via a transcallosal approach, confirmed a third ventricular colloid cyst, which was excised.

#### Case 2

A 34-year-old woman had severe headaches, which occurred daily, frequently causing her to awaken from sleep. They were usually associated with nausea and vomiting. A CT study revealed a high-attenuation colloid cyst in the usual third ventricular location (Fig 2). MR imaging was also performed, but the tumor was less evident, as the cyst was isodense with brain on both T1- and T2-weighted studies. MR sequences included sagittal images (633/11/1) with a section thickness of 5 mm and a 2-mm gap, axial images (2500/17/1) with a section thickness of 6 mm and a 3-mm gap, axial images (3000/108/1) with a section thickness of 6 mm and a 3-mm gap, and axial images (416/26/1) with a section thickness of 6 mm and a 3-mm gap. Contrast-enhanced images were obtained in the axial plane (416/26/1.5) with a section thickness of 6 mm and a 3-mm gap, in the coronal plane (620/26/1) with a section thickness of 6 mm and a 3-mm gap, and in the sagittal plane (500/12/1) with a section thickness of 4 mm and a 1-mm gap. Although no enhancement of the cyst was evident, it was more conspicuous on the axial and sagittal contrast-enhanced images.

The patient responded briefly to conservative therapy; however, surgery was recommended after a recurrence of symptoms. A transcallosal microsurgical approach was recommended, and the tumor was resected. Pathologic findings were consistent with a colloid cyst.

### Discussion

Colloid cysts are potentially dangerous tumors, because they often generate nonlocalizing symptoms but are associated with sudden death, even in children (1, 2). With the availability and widespread use of MR imaging and CT, colloid cysts are being identified more frequently, often without evidence of hydrocephalus on imaging studies. In one series reported by Camacho et al (3) of 84 patients with colloid cysts identified on CT scans, surgery was not recommended in 24 cases. In each of these cases the cysts were small and without associated hydrocephalus. However, since even small colloid cysts have been associated with sudden death, the precise criteria that differentiate cysts that require surgery from those that do not are uncertain at this time. Ryder et al (1) specifically looked at size as a predictor of outcome in 55 cases of benign third ventricular tumors (52 colloid cysts) that led to sudden death and found a size range

Received November 1, 1996; accepted after revision September 22, 1997.

From the Departments of Radiology (A.C.M., L.D.C.) and Neurosurgery (R.E.H.), Dartmouth-Hitchcock Medical Center, Lebanon, NH. Address reprint requests to Alex Mamourian, MD, Department of Radiology, Dartmouth-Hitchcock Medical Center, One Medical Center Dr, Lebanon, NH 03756.

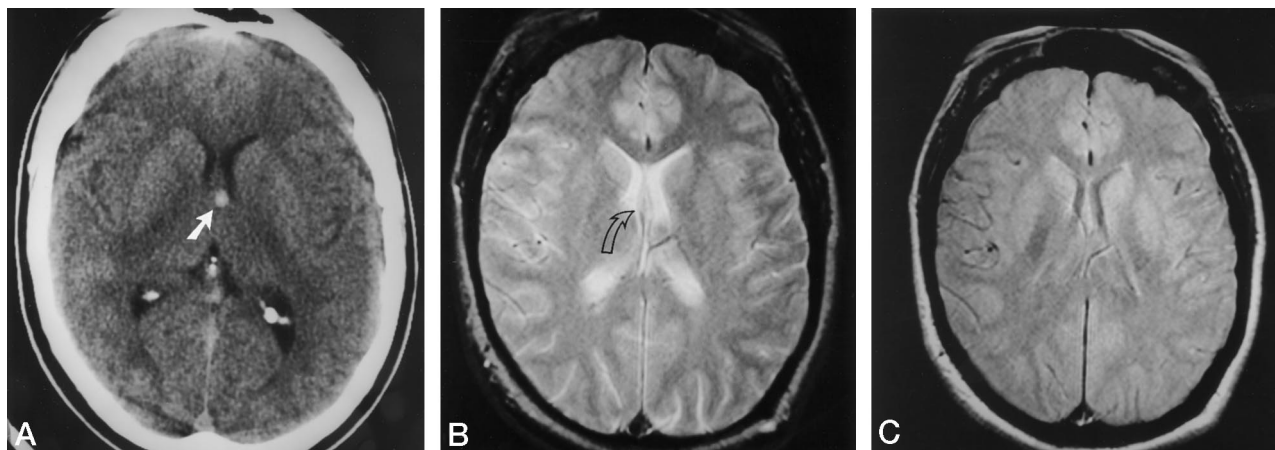


FIG 1. 36-year-old man with 10-year history of headaches, increasing in intensity during month prior to admission.

A, Axial unenhanced CT scan shows a typical high-attenuation colloid cyst (arrow).

B, Axial MR image (2000/85) at the level of the superior third ventricle shows only thickening at the posterior septum (arrow) but no evidence of abnormal signal intensity.

C, Axial MR image (2000/35) also shows no definite abnormality in the region of the anterosuperior third ventricle.

D, Coronal contrast-enhanced MR image (650/25) shows only mild thickening of the septum in the region of the tumor (arrow).

E, Sagittal MR image (600/15) shows the colloid cyst (arrow).

of 1 to 8 cm, leading them to conclude that ventricular size is not a reliable predictor of outcome.

The most common presenting symptom of colloid cyst is intermittent headache, frequently associated with other symptoms, such as visual changes (4). Treatment options include surgery and stereotactic cyst aspiration (5, 6). The attenuation of the cyst on CT scans appears to predict the feasibility of cyst aspiration. Isodense or hypodense cysts on CT are more prone to successful needle aspiration (5). Kondziolka and Lunsford (5) suggested that low CT attenuation of the cystic contents correlates with lower viscosity, which allows successful aspiration. Surgery is usually via a transcallosal approach using microsurgical techniques that allow sparing of important anterior third ventricular structures, specifically the fornix. There is a low prevalence of recurrence with both procedures. In a recent review of 12 years' experience with both procedures in 37 patients, Mathiesen et al (7) reported better long- and short-term results with transcallosal surgery as compared with aspiration.

The predictable anterior third ventricular location of colloid cysts suggests a unifying pathogenesis, but their origin remains obscure. For some time it had been thought that they originated from the parapneuroepithelium, a primitive neuroepithelium. On the basis of findings reported by Shuangshoti et al (8), some authors

had classified them along with other neuroepithelial cysts, such as choroid plexus and pineal cysts. However, more recent immunohistochemical studies suggest a different cellular origin for colloid cysts, specifically endoderm (9–11). Their unusual MR imaging characteristics also support a different origin, as colloid cysts have a remarkably variable range of signal intensities while choroid plexus and pineal cysts usually resemble CSF (12).

Several theories have been proposed to explain the range of appearances of the cyst on CT and MR studies. One hyperdense colloid cyst, studied with atomic emission spectrometry, had elevated levels of sodium, magnesium, and calcium ions, which were thought to explain the high attenuation (13). There was so little iron found that hemorrhage was considered an unlikely cause of its CT appearance. Another study, which compared the MR appearance with chemical analysis, found that the high signal intensity on T1-weighted MR images seemed to roughly follow the concentration of cholesterol within the cyst (14). On T2-weighted images, colloid cysts can range in appearance from hypointense to hyperintense, and they may be homogeneous or heterogeneous (15). While this had been thought to reflect high concentrations of paramagnetic ions, this now seems unlikely, owing to an analysis of eight colloid cysts in

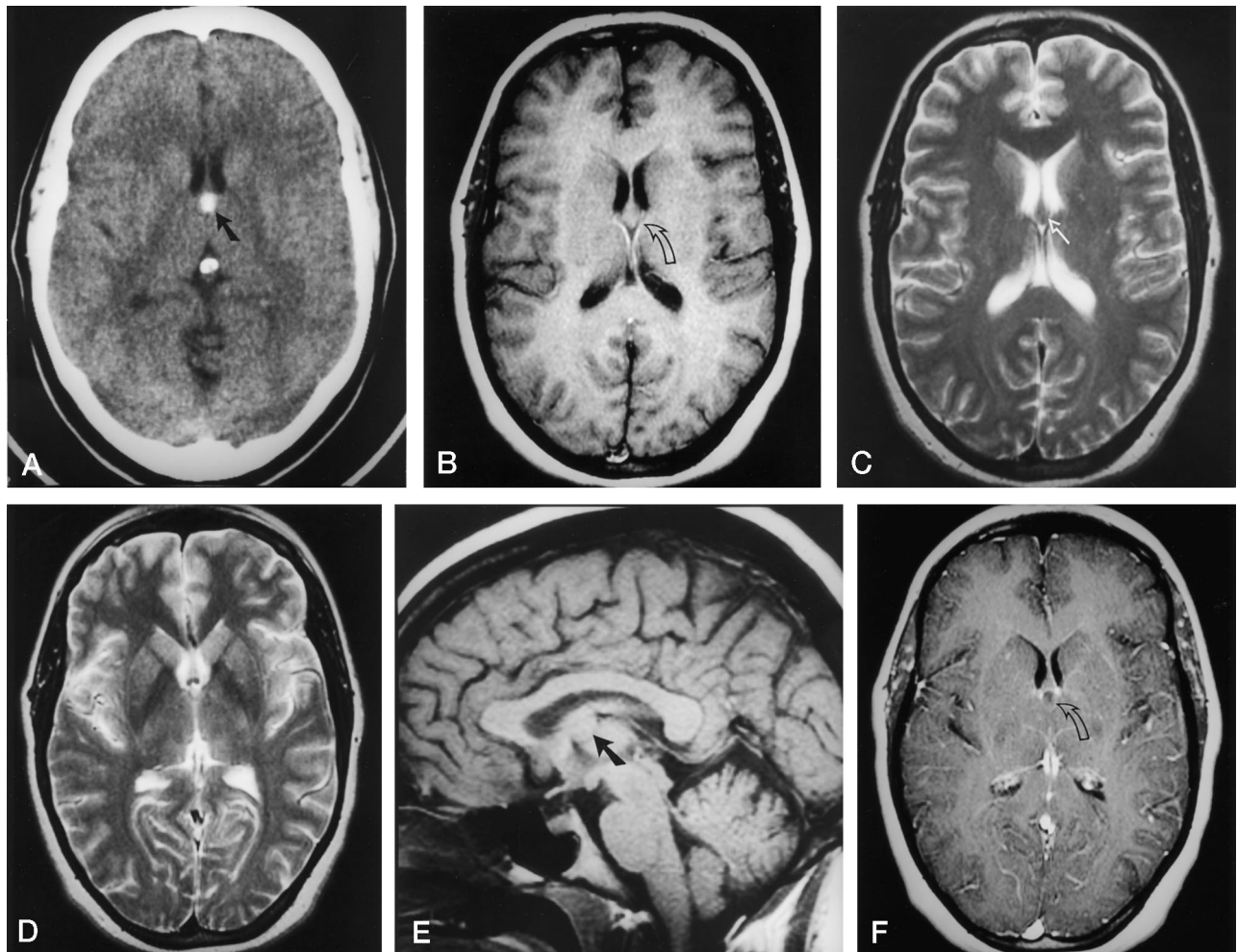


FIG 2. 34-year-old woman with severe daily headaches, frequently causing her to awaken from sleep, and accompanied by nausea and vomiting.

A, Axial CT scan shows the high-attenuation colloid cyst (arrow).

B, Axial MR image (416/26) shows the colloid cyst as a mass at the posterior septum but isointense with brain (arrow).

C and D, MR images (3000/108) at two adjacent levels show the colloid cyst as isointense with brain (arrow).

E, Sagittal MR image (633/11) at the midline shows the colloid cyst projecting as a mass lesion (arrow) superior to the region of the anterior commissure.

F, Axial contrast-enhanced MR image (416/26) shows the cyst is of low signal intensity relative to adjacent brain (arrow).

which low concentrations of paramagnetic ions were found (14). The contents of the cyst in our case 2 was studied in vitro after excision and was found to be isointense with saline on a  $10^\circ$  flip angle gradient-echo examination. This would also support a low concentration of iron, since that sequence accentuates susceptibility effects.

It had been our experience that MR imaging was frequently superior to CT in depicting colloid cysts, particularly when they were isointense on CT scans. It would appear that a corresponding problem may exist for MR imaging in regard to small cysts that appear hyperdense on CT studies. In addition to the two examples presented here, we have encountered two other cases of colloid cysts with typical CT features, which were followed up without surgery, in which the tumor was less apparent on MR images.

In case 1 of the present study, it is possible that the relatively thick sections we used for our T2-weighted

and intermediate imaging studies (8 mm) limited our ability to define this small tumor. However, the cyst was not evident on the coronal sequences either. In case 2, the cyst was larger, and the section thickness was only 6 mm. We would argue that the primary difficulty in visualizing these tumors on MR images is low contrast between cyst and brain.

### Conclusion

In these cases, colloid cysts were visible on sagittal T1-weighted MR images as a mass superior and posterior to the normally visualized anterior commissure. Therefore, in patients with suspected colloid cysts, we recommend careful attention to a thin sagittal T1-weighted section through the midline of the brain. In some cases, however, where a small colloid cyst is suspected at MR imaging, CT may better depict the typical hyperdense colloid cyst.



## References

1. Ryder JW, Kleinschmide-DeMasters BK, Keller TS. **Sudden deterioration and death in patients with benign tumors of the third ventricle area.** *J Neurosurg* 1986;64:216-223
2. Byard RW, Moore L. **Sudden and unexpected death in childhood due to a colloid cyst of the third ventricle.** *J Forensic Sci* 1993;38:210-213
3. Camacho A, Abernathy CD, Kelly PJ, Laws ER Jr. **Colloid cysts: experience with the management of 84 cases since the introduction of computed tomography.** *Neurosurgery* 1989;24:693-700
4. Kelly R. **Colloid cysts of the 3rd ventricle: analysis of 29 cases.** *Brain* 1951;74:23-65
5. Kondziolka D, Lunsford LD. **Stereotactic management of colloid cysts: factors predicting success.** *J Neurosurg* 1991;75:45-51
6. Abernathy DC, Davis DH, Kelly PJ. **Treatment of colloid cysts of the third ventricle by stereotaxic microsurgical laser craniotomy.** *J Neurosurg* 1989;70:525-529
7. Mathiesen T, Grane P, Lindgren L, Lindquist C. **Third ventricle colloid cysts: a consecutive 12-year series.** *J Neurosurg* 1997;86:5-12
8. Shuangshoti S, Roberts MP, Netsky MG. **Neuroepithelial (colloid) cysts.** *Arch Pathol* 1965;80:214-224
9. Ho KL, Garcia JH. **Colloid cysts of the third ventricle: ultrastructural features are compatible with endodermal derivation.** *Acta Neuropathol* 1992;83:605-612
10. Mackenzie IRA, Gilbert JJ. **Cysts of the neuraxis of endodermal origin.** *J Neurol Neurosurg Psychiatry* 1991;54:572-575
11. Sumida M, Mukada TUK, Arita K, Kurisu K, Eguchi K. **Rathke cleft cysts: correlation of enhanced MR and surgical findings.** *AJNR Am J Neuroradiol* 1994;15:525-532
12. Mamourian AC, Towfighi J. **Pineal cysts: MR imaging.** *AJNR Am J Neuroradiol* 1986;7:1081-1086
13. Donaldson JO, Simon RH. **Radiodense ions within a third ventricular colloid cyst.** *Arch Neurol* 1980;37:246
14. Maeder PP, Holtas SL, Basibuyuk LN, Salford LG, Tapper UAS, Brun A. **Colloid cysts of the third ventricle: correlation of MR and CT findings with histology and chemical analysis.** *AJR Am J Roentgenol* 1990;155:135-141
15. Wilms G, Marchal G, Van Hecke P, et al. **Colloid cysts of the third ventricle: MR findings.** *J Comput Assist Tomogr* 1990;14:527-531