

Are your **MRI contrast agents** cost-effective?

Learn more about generic **Gadolinium-Based Contrast Agents**.



**FRESENIUS
KABI**

caring for life

AJNR

Transdural spinal cord herniation: imaging and clinical spectra.

M R Watters, J C Stears, A G Osborn, G E Turner, B S Burton, K Lillehei and W T Yuh

AJNR Am J Neuroradiol 1998, 19 (7) 1337-1344

<http://www.ajnr.org/content/19/7/1337>

This information is current as of April 19, 2024.

Transdural Spinal Cord Herniation: Imaging and Clinical Spectra

Michael R. Watters, John C. Stears, Anne G. Osborn, Gary E. Turner, Bradford S. Burton, Kevin Lillehei, and William T. C. Yuh

PURPOSE: Transdural herniation of the spinal cord is a rarely reported clinical entity, and many of the existing reports were published before the advent of MR imaging. We describe five current cases and compare them with findings in 25 cases reported in the literature to delineate the clinical and imaging spectra of transdural spinal cord herniation.

METHODS: MR imaging, CT myelography, and conventional myelography were performed in five patients with transdural herniation of the spinal cord. These studies, along with clinical findings, are described. Intraoperative photographs are included for one case. The salient features of both the current and previously reported cases are summarized in tabular form.

RESULTS: In three cases, transdural spinal cord herniation occurred posttraumatically, in one case the cause was iatrogenic and in the others the herniation occurred spontaneously. Imaging features not previously reported include dorsally directed herniations at thoracolumbar levels (two patients), apparent (lacking surgical confirmation) syringomyelia (one case), a vertebral body nuclear trail sign (one case), and intramedullary hyperintensities on MR images (two cases). Clinical features not previously reported include unilateral pyramidal-sensory deficits (one case) and isolated unilateral pyramidal signs (one case). Clinical findings similar to previous reports include progressive paraparesis (two cases) and progressive Brown-Séquard syndrome (one case).

CONCLUSION: Our five cases illustrate certain clinical and imaging findings not previously reported, and, together with the established features of the 25 cases in the literature, delineate the spectra of transdural spinal cord herniation.

Herniation of the spinal cord through a dural defect is a rarely reported clinical entity that may be classified on the basis of etiology; that is, whether it occurs spontaneously, posttraumatically, or iatrogenically. Since the initial report in 1973 (1), only 24 additional cases have been described (2-17). We review and summarize these 25 previously reported cases, most of which occurred before the availability of MR imaging, and describe five additional patients

with transdural spinal cord herniation, four of whom had MR imaging as part of their workup. Our emphasis is on those imaging or clinical features not previously reported. Collectively, these 30 cases delineate the imaging and clinical spectra seen with transdural herniation of the spinal cord.

Methods

The 25 previously reported cases of transdural spinal cord herniation were included for review if the reports provided detailed clinical information, including laterality of sensory and motor signs and findings at conventional or CT myelography, CT, or MR imaging. The five previously unreported cases were evaluated for clinical signs of myelopathy. All five cases included at least one form of cross-sectional imaging: four of the five patients underwent MR imaging, and the fifth patient had CT myelography. Among the four patients who had MR imaging, two also had conventional myelography and CT myelography. The MR examinations included, as a minimum, 3-mm-thick sagittal T1- and T2-weighted images and 5-mm-thick axial T1-weighted images. The CT myelograms included 5-mm-thick axial scans obtained after intrathecal administration of non-ionic contrast medium. Imaging studies showing rotation of the spinal cord with displacement ventrally or dorsally at the thoracolumbar levels, or displacement dorsally at the cervical level, and a communicating, apparently dilated, CSF space occupying the normal cord position were considered features

Received September 9, 1997; accepted after revision May 28, 1998.

The opinions or assertions contained herein are the private views of the authors and are not to be construed as official nor as reflecting the views of the Department of the Army or the Department of Defense.

From the Divisions of Neurology (M.R.W.) and Radiology (G.E.T., B.S.B.), University of Hawaii School of Medicine; the Departments of Radiology (J.C.S.) and Neurosurgery (K.L.), University of Colorado Health Sciences Center; the Department of Radiology, University of Utah School of Medicine (A.G.O.); and the Department of Radiology, University of Iowa College of Medicine (W.T.C.Y.).

Address reprint requests to Michael R. Watters, MD, Chief, Neurology Service, Tripler Army Medical Center, HI 96859.

of transdural spinal cord herniation. Surgical confirmation of the herniation was available in all cases but one. Intraoperative photographs were obtained in one case.

Results

In three of the five cases, an episode of significant accidental trauma was identifiable prior to the onset of neurologic symptoms, although in each case the interval between trauma and onset of symptoms ranged from 1 to several years. One patient had postoperative iatrogenic trauma associated with a broken fixation wire. Only one herniation occurred spontaneously.

Case 1: Spontaneous Herniation, Brown-Séguard Syndrome

A 55-year-old woman had a 10-year history of progressive sensory disturbances in the right leg and a 2-year history of progressive weakness in the left leg, which was hyperreflexic on examination. Toe signs were downgoing bilaterally. Bowel and bladder function had remained normal. She had no pain along the spinal axis, although she did report an aching sensation throughout the right lower extremity. There was no history of back trauma or prior spinal surgery.

Imaging studies included a CT myelogram, which showed an abnormality of the spinal cord at T3–T4. The CSF space was locally wider dorsal to the cord, and the cord was displaced anteriorly. This was interpreted as a dorsal arachnoid cyst compressing the spinal cord and displacing it ventrally. Surgical laminectomies of T3 and T4 were performed, and the dura was opened in the dorsal midline. The dorsal arachnoid did not form a cyst. The cord appeared abnormally thinned in the anteroposterior dimension, and was positioned ventrally within the spinal canal. The ventral surface of the cord was not explored.

Postoperative MR imaging (Fig 1A) showed unchanged displacement of the cord at the T3–T4 level ventrally and ventrolaterally (to the left). A second opinion led to the diagnosis of a ventrolateral transdural spinal cord herniation. A defect in the ventral dura appeared to extend from the caudal aspect of T3 to the caudal aspect of T4 (which had not been appreciated on the preoperative CT myelogram) with a widened ventrolateral epidural space. There was no notching of the vertebral body anterior to the cord.

Clinically, the patient's neurologic deficits continued to progress, and a second operation was performed. Grossly, the dorsal arachnoid was normal and the configuration and position of the cord appeared unchanged from the initial surgical exposure, with displacement ventrolaterally toward the left. Traction on the locally divided left dentate ligament allowed gentle rotation of the cord dorsally and to the right, thereby exposing a defect in the ventral dura approximately 6 mm wide and 22 mm long. The epidural space ventral to this dural defect was pale and smooth. Near the center of the dural defect was an exiting spinal nerve root (Fig 1B). At the rostral end of the dural defect, a small lobule of herniated spinal

cord was seen, approximately 4 × 4 mm in size, tethered by the rostral arcuate margin of the dural defect and minimal adhesions. After resection of these adhesions, the herniated cord lobule was freed to move back against the cord surface, reducing the overall cord deformity (Fig 1C). However, the lobule did not completely flatten into the cord. The ventrolateral dural defect was closed with fine sutures.

Postoperatively, the patient had no new deficits, and by 2 months reported improved strength in the left and less discomfort in the right lower extremities. Her status then stabilized, and has remained so for 18 months. An MR study of the thoracic spine performed several months after the second operation showed that the cord remained within the spinal canal and was mildly narrowed.

Case 2: Posttraumatic Herniation, Isolated Unilateral Pyramidal Signs

A 46-year-old man had a 3-year history of back pain, paraspinal muscle spasms, and progressive weakness in the left lower extremity, occurring subsequent to a whiplash injury incurred while standing in a boat. The patient described initial torso hyperextension followed by torso flexion, and immediate onset of pain in the lumbar region. Pain and muscle spasms extended to the upper thoracic level during the subsequent weeks. His initial neurologic examination 2 months after the injury noted symmetrical reflexes at the knees, no objective deficits, and prominent paraspinal muscle spasms. Findings on a lumbosacral CT scan were normal. His thoracic back pain persisted, and moderate weakness of the left lower extremity developed gradually over the next 3 years. He had no sensory or bowel-bladder disturbances.

Subsequent neurologic examinations revealed hyperreflexia of the left knee, an extensor toe on the left, and moderate weakness of the left lower extremity. An MR study of the lumbosacral spine showed disk desiccation at L4–L5 with mild disk bulging, otherwise unremarkable. Findings on MR studies of the brain and cervical cord were normal. However, the thoracic MR study revealed focal ventral displacement of the cord at the midthoracic level, with scalloping of the dorsal wall of the T6 vertebral body (Fig 2A). The spinal cord at this level was thin and showed T2-weighted hyperintensity. Dorsal to this defect appeared to be a capacious space with CSF signal characteristics on MR images, which opacified with administration of intrathecal contrast material at myelography (Fig 2B). Axial CT myelography showed sclerotic notching of the dorsal margin of the T6 vertebral body, most prominent to the left of midline, into which protruded the left side of the rotated spinal cord (Fig 2C). At the caudal aspect of the T6 vertebral body, a nuclear trail sign was seen (Fig 2D). The right side of the cord remained within the confines of the spinal canal. Caudal to T6 the spinal cord regained a normal configuration; however, it remained thin in caliber. A diagnosis of transdural spinal cord herniation was made.

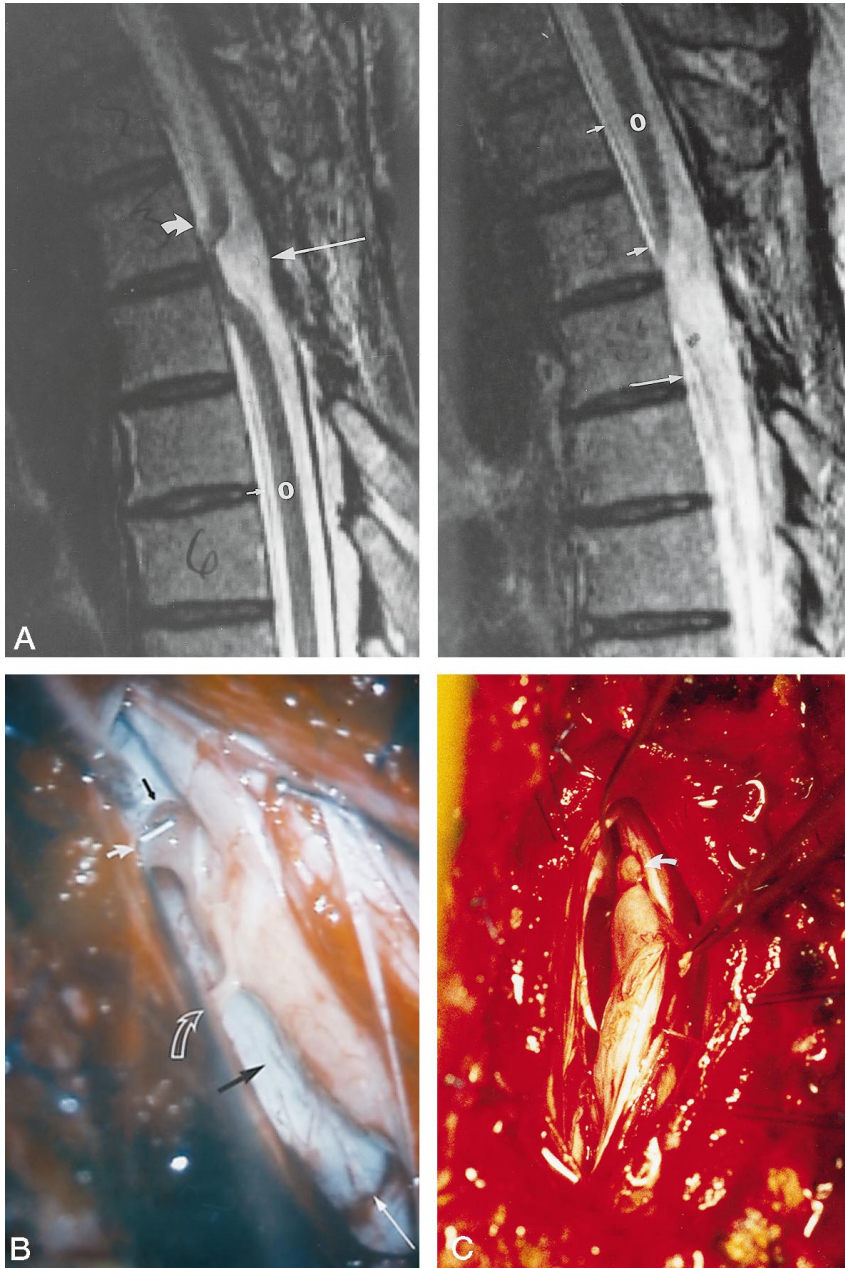


FIG 1. Case 1: spontaneous spinal cord herniation.

A, Sagittal T2-weighted MR image (4050/102 [TR/TE_{eff}]) shows an apparently dilated CSF space dorsal to the ventral cord herniation.

B, Intraoperative view before surgical reduction shows a spinal root exiting through the dural defect, which may suggest a preexisting congenital abnormality.

C, The herniated lobule is now reduced against the major cord surface, but the lobule does not completely flatten into the cord.

Longest thin white arrow points from the dorsal surface of the vertebral canal toward the ventrally retracted spinal cord; O, indicates the spinal cord; curved solid arrow, the cord lobule herniated into the epidural space; small black arrow, the rostral end of the ventral dural defect; medium length thin white arrow, the caudal end of the ventral dural defect; small white arrows, the ventral dura; open curved arrow, the spinal nerve root; large black arrow, the epidural space.

At surgery, the cord was very thin grossly at the midthoracic level. A dural defect approximately 4 mm in diameter was identified ventrally to the left of midline at T6. The left side of the cord was herniated through this defect and attached by duplicated dural membranous tissues to the dorsal vertebral body of T6, which was notched. This membranous tissue appeared to represent a pseudomeningocele pouch, into which the cord had been partially drawn. The pouch was excised, and the cord assumed a more normal configuration. The vertebral notch was packed with muscle and the dura closed with fine sutures.

The patient's back pain and spasms were dramatically relieved postoperatively, and his left lower extremity weakness improved over the first 2 months. However, by 4 months, back pain and spasms had recurred, and the left lower extremity weakness had

progressed. A repeat MR examination was unchanged from the initial postoperative MR study, showing the cord positioned wholly within the spinal canal, with persistent intramedullary T2-weighted hyperintensities, consistent with myelomalacia (Fig 2E).

Case 3: Posttraumatic Herniation, Dorsal Thoracic Herniation with Syrinx

A 35-year-old man had a slowly progressive spastic paraparesis and a remote history of trauma to the thoracic spine 17 years earlier. MR images showed features of extensive syrinx cavitation from C2 to T8 and a dorsal cord herniation at the T3 level (Fig 3A). The syrinx appeared to extend into the herniated cord (Fig 3B). The surgical and postoperative courses are unknown.

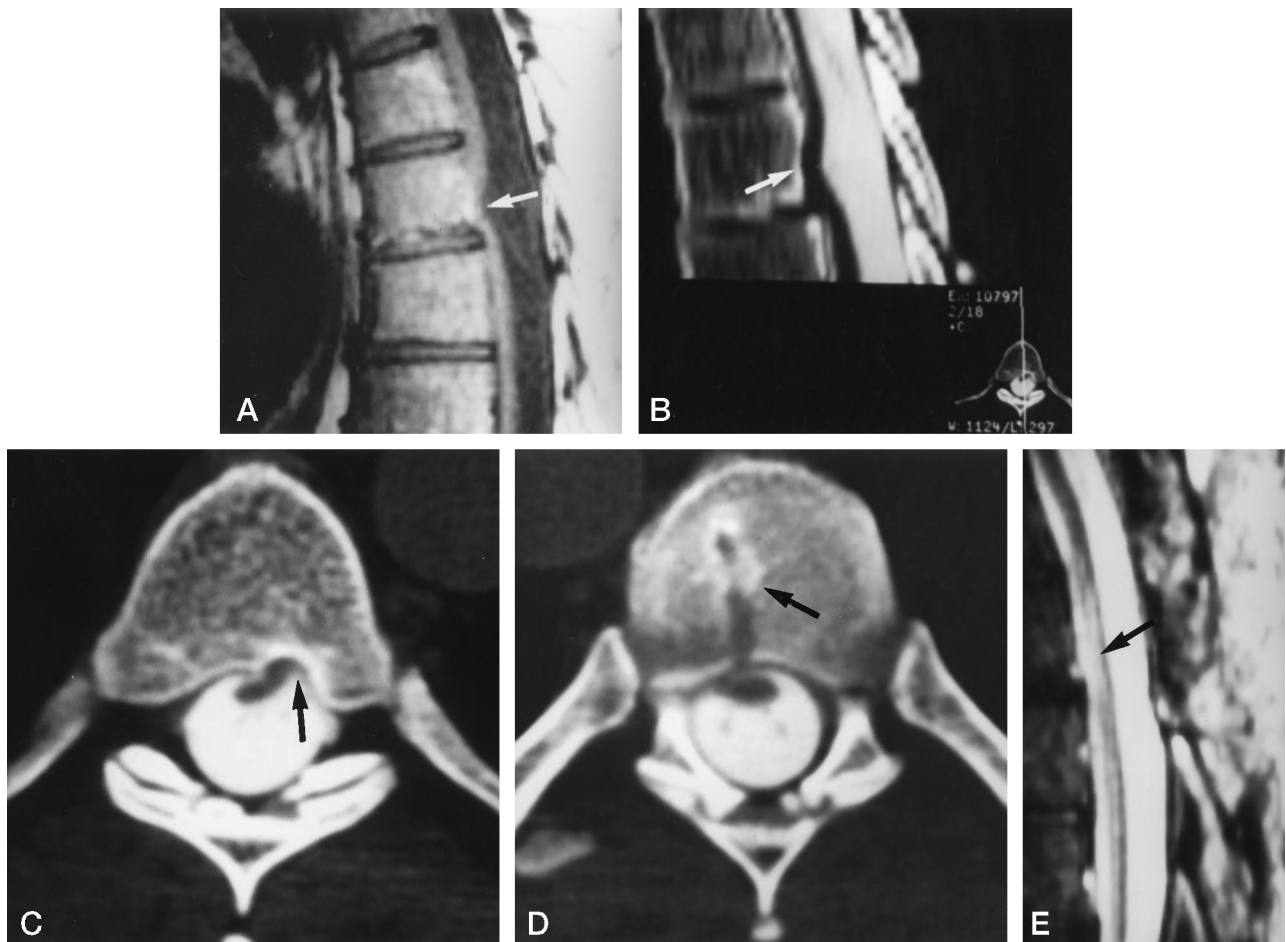


FIG 2. Case 2: posttraumatic spinal cord herniation.

A, Sagittal T1-weighted spin-echo MR image (600/11/2) shows the spinal cord (*arrow*) is thin and situated close to the dorsal T6 vertebral body.

B, Sagittal CT myelogram with reconstruction shows notching of the dorsal T6 vertebral body (*arrow*), ventral displacement of the spinal cord, and contrast material filling an apparently dilated CSF space dorsally.

C, Axial CT scan shows herniation of the ventral spinal cord to the left, with sclerotic notching of the T6 vertebra (*arrow*) and rotation of the cord toward the notching.

D, Nuclear trail sign (*arrow*) is seen just below the site of cord herniation, suggesting a previously herniated nuclear disk fragment.

E, Sagittal postreduction T2-weighted MR image (4200/80/4) shows the cord wholly positioned within the spinal canal. Intramedullary hyperintensity (*arrow*) is seen, which may be an unfavorable prognostic sign.

Case 4: Posttraumatic Herniation, Dorsal Herniation of Conus

A 46-year-old man fell off a 25-foot wall, sustaining an L1 burst fracture, which resulted in clinical paraparesis, worse in the right lower extremity. The patient underwent L1 anterior vertebrectomy with instrumentation and stabilization, and had some improvement in motor functioning. No posterior surgery was performed at that time.

Over the subsequent 10 months, significant back pain developed, radiating into the right buttock and right lower extremity with loss of tendon reflexes and neurogenic bowel and bladder disturbances. Myelography (Fig 4A) showed a dilated CSF space anterior to a dorsally displaced conus medullaris at L1. Axial MR images (Fig 4B) showed herniation of dura and cord dorsally to the right, through the right bony lamina of the L1 vertebra, and hyperintensities within the herniated conus.

Combined orthopedic and neurosurgical intervention at L1 resulted in an L1 laminectomy, exposing the bony defect through which herniated portions of the conus and right sacral nerve roots. Dural reflections were found along both the medial and lateral aspects of the laminal defect. Postoperatively, the patient has had no significant change in his functional status or pain.

Case 5: Iatrogenic Herniation, Unilateral Pyramidal-Sensory Signs

A 33-year-old man had neck pain, sensory loss in the left lower extremity, and progressive clumsiness in the left hand. Sixteen years earlier, he had sustained a traumatic odontoid fracture with C1–C2 instability, and had undergone posterior cervical wiring. Currently, cervical spine radiographs showed broken wiring beneath the lamina of C1, and myelography

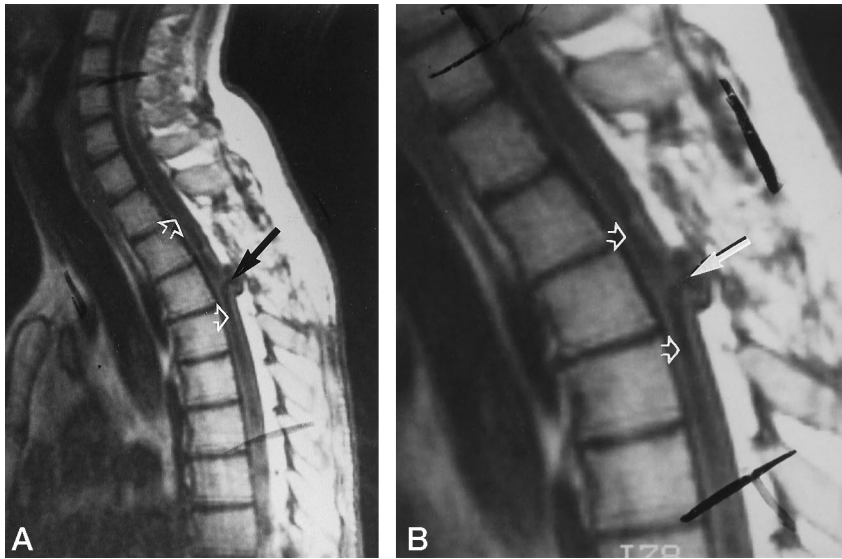


FIG 3. Case 3: posttraumatic spinal cord herniation.

A, Sagittal T1-weighted MR image (600/20) shows an apparent syrinx cavitation (*open arrows*) extending from C2 to T8, with a dorsal herniation of the spinal cord at T3 (*arrow*).

B, Enlarged detail at the T3 herniation. All previously reported thoracolumbar herniations had been ventrally directed.

showed the wire to be indenting the cord dorsally at C2. At surgery, the wire was removed, and CSF flow was noted, indicating a dural tear, which was not repaired surgically nor overlaid with gelatin sponge or Surgicel. Subsequent improvement in all signs and symptoms was sustained for approximately 2 weeks. Thereafter, the neck pain returned and the sensorimotor deficits on the left increased. The patient's reflexes became diffusely hyperactive, with an extensor toe on the left. A repeat myelographic CT examination (Fig 5) suggested herniation of the spinal cord at C1–C2 dorsally to the left, with extravasation of contrast material into the dorsal epidural space and dilatation of the CSF space ventral to the herniated cord.

Additional surgery was performed, which confirmed a dural tear dorsally with herniation of the spinal cord below the lateral aspect of the posterior arch of C1 on the left. No arachnoid cyst was seen ventral to the cord herniation. Subdurally, fibrotic

scar tissue had formed a subdural membrane, which was sectioned along with arachnoid adhesions to free the incarcerated cord. The subdural membrane, as well as dural sutures, was used to repair the dural opening, which was overlaid with gelatin sponge. Stability was restored via C1–C3 interlaminar fusion with wire and rib graft. The left hemiparesis resolved on the first postoperative day, and the patient resumed ambulation. Long-term follow-up results are not available.

Discussion

Owing to the infrequent occurrence of spinal cord herniation and to the previously unreported features of cases 2 through 5, an analysis of all available cases of spinal cord herniation is required to delineate the full spectra of imaging and clinical features, which are summarized in Tables 1 through 3. Previously unreported imaging features found among the current cases include the nuclear trail sign (case 2), the in-

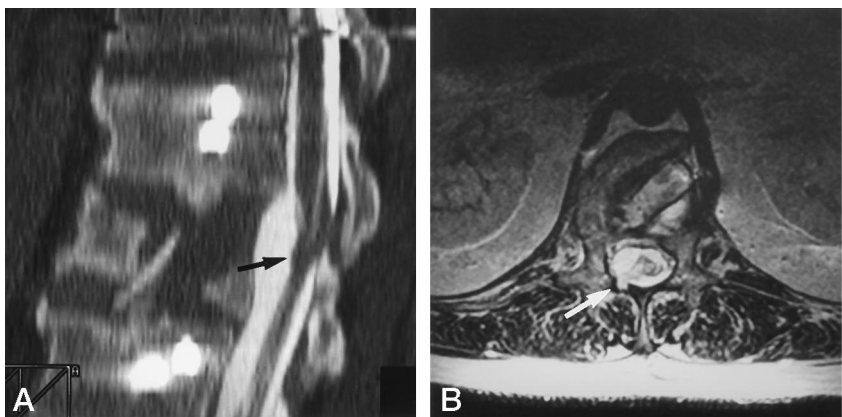


FIG 4. Case 4: posttraumatic spinal cord herniation.

A, Sagittal myelogram shows contrast material filling an apparently dilated CSF space anterior to the spinal cord (*arrow*), which is dorsally displaced at the L1 level.

B, Axial fast spin-echo MR image (3200/80) shows herniation of the dura and cord at the L1 level, dorsally to the right, through a defect in the bony lamina (*arrow*). Intramedullary hyperintensities are seen.

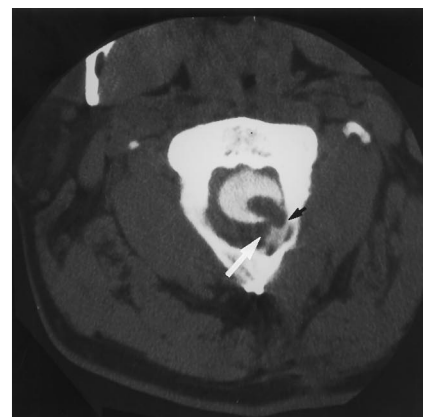


FIG 5. Case 5: iatrogenic spinal cord herniation after excision of a broken fixation wire without repair of the dura. Axial CT myelogram shows herniation of the cord (*small arrow*) at the C1–C2 level, dorsally to the left, with extravasation of contrast material into the dorsal epidural space (*large arrow*).

TABLE 1: Spontaneous cord herniations

Author	Age (y)/ Sex of Patient	Spinal Level	Herniation Direction	Spinal Pain	Clinical Deficits	Meningeal Cyst	Postoperative Course
Masuzawa et al (5)	36/M	T4-T5	VL	+	Brown-Séquard	+	Complete recovery
Isu et al (9)	43/F	T5-T6	VL	-	Brown-Séquard	+	Improved
	45/F	T2-T3	VL	-	Myelopathy	+	Improved
Tronnier et al (10)	45/F	T3-T4	V	+	Unilateral sensory	-	Worsened, then improved
Nakazawa et al (11)	43/F	T2	VL	-	Brown-Séquard	-	Improved
	39/F	T4-T5	V	-	Brown-Séquard	-	Improved
Kumar et al (12)	38/M	T7-T8	VL	-	Brown-Séquard	-	Complete recovery
Borges et al (13)	68/F	T7-T8	VR	-	Brown-Séquard	-	Complete recovery
	48/F	T7-T8	VL	-	Brown-Séquard	-	Improved
Miura et al (15)	49/M	T5-T6	VR	-	Myelopathic	+	Improved
Hausmann and Moseley (16)	57/F	T6	VL	+	Brown-Séquard	-	Improved
	36/M	T6-T7	VR	+	Myelopathy	-	NR
	51/F	T6-T7	VL	-	Brown-Séquard	NOp	NOp
Uchino et al (17)	49/M	T4-T5	V	-	Myelopathy	NOp	NOp
	71/F	T4-T5	V	-	Myelopathy	+	No improvement
Present study, case 1	61/F	T6	VL	-	Brown-Séquard	-	Improved
	55/F	T3-T4	VL	-	Brown-Séquard	-	Improved

Note.—V indicates ventral; L, left; R, right; +, present; -, absent; NRp, not reported; NOp, not operated on.

tramedullary MR hyperintensities (cases 2 and 4), the dorsally directed thoracolumbar herniations (cases 3 and 4), and the apparent syrinx (case 3). Previously unreported clinical features include the unilateral pyramidal-sensory signs (case 5) and the isolated unilateral pyramidal signs (case 2). Most published reports include only one or two cases of spinal cord herniation, with the largest series (16) reporting four cases.

Spontaneous spinal cord herniations, summarized in Table 1, occurring in the absence of apparent spinal trauma or spinal surgery, account for 17 (57%) of the 30 known cases of spinal cord herniation. Our case 1, a woman with painless progressive Brown-Séquard syndrome due to a ventrolaterally directed herniation at the thoracic level with improvement after surgical intervention, is typical of previously reported cases. Twelve of the 17 reported patients are women, in contrast to only one woman among the 13 patients with posttraumatic or iatrogenically occurring herniation. Eleven (65%) of the 17 patients with spontaneously occurring herniation had signs characteristic of Brown-Séquard syndrome. Five patients had more diffuse myelopathic signs (paraparesis,

sphincter disturbances, sensory levels), and one patient had unilateral sensory signs.

Posttraumatic spinal cord herniations are summarized in Table 2. Only one of these seven patients had Brown-Séquard syndrome. Although Brown-Séquard described this syndrome of hemimyelopathy associated with spinal trauma as long ago as 1869 (18), no cases associated with posttraumatic spinal cord herniation were reported until 1995, and this occurred in a patient 48 years after shrapnel injury (13). Four of the remaining six patients with posttraumatic spinal cord herniations had diffuse myelopathic signs, whereas one had unilateral sensorimotor deficits, and the sixth (our case 2) uniquely manifested unilateral pyramidal signs. Case 3 represents the initial report of an apparent (not surgically confirmed) syrinx associated with spinal cord herniation (Fig 3B).

All 17 spontaneous cases and five of the seven posttraumatic cases were associated with ventrally or ventrolaterally directed spinal cord herniations at the thoracolumbar level. Our cases 3 and 4 represent the initial reports of dorsally directed herniations at the thoracolumbar level.

TABLE 2: Posttraumatic cord herniations

Author	Age (y)/ Sex of Patient	Spinal Level	Herniation Direction	Spinal Pain	Clinical Deficits	Years since Prior Trauma	Meningeal Cyst	Postoperative Course
Wortzman et al (3)	63/M	T7	V	+	Myelopathy	31 6	-	Worsened, then improved
Sachdev et al (6)	44/F	L1	VR	+	R leg sensorimotor	12	+	Worsened, then improved
Borges et al (13)	68/M	T2-T3	VL	-	Brown-Séquard	48	-	Improved
Urbach et al (14)	44/M	T5-T6	VR	-	Myelopathy	38	-	Improved
Present study								
Case 2	46/M	T6	VL	+	L leg pyramidal	3	-	Improved, then worsened
Case 3	35/M	T3	D	NR	Myelopathy	17	NR	Unknown
Case 4	46/M	L1	DR	+	Myelopathy	1	-	Unchanged

Note.—V indicates ventral; D, dorsal; L, left; R, right; +, present; -, absent; NR, not reported.

TABLE 3: Iatrogenic cord herniations

Author	Age (y)/ Sex of Patient	Spinal Level	Herniation Direction	Spinal Pain	Clinical Deficits	Years since Prior Surgery	Meningeal Cyst	Postoperative Course
Cobb and Ehni (1)	39/M	C5-C6	D	+	Myeloradiculopathy	3	-	Improved
Goodman and Gregorius (2)	54/M	C4	D	-	Myelopathy	7	+	Improved
Burres and Conley (4)	41/M	C2	D	+	Myelopathy	18	+	Improved
Mizuno et al (7)	55/M	C6-C7	D	-	Myelopathy	13	+	NR
Dunn et al (8)	33/M	C1-C2	DL	+	Radiculopathy	15	-	Complete recovery
Present study, case 5	33/M	C1-C2	DL	+	Unilateral pyramidal-sensory	16	-	Improved

Note.—D indicates dorsal; L, left; +, present; -, absent; NR, not reported.

All cases of iatrogenic (postoperative) herniations, summarized in Table 3, were associated with dorsally or dorsolaterally directed herniations at the cervical level. Four of the six postoperative patients had previously undergone laminectomies with dural openings. In one patient the dural defect was covered with gelatin sponge (1) and in another it was covered only by closure of the surgical wound (2); the remaining two cases were lacking details of the initial laminectomies, which had been performed more than a decade earlier (4, 7). Like our case 5, the remaining case was associated with a dural tear caused by a broken fracture-fixation wire (8). Hence, a dorsal dural defect was produced iatrogenically in each of these six cases. Clinically, these iatrogenic herniations were manifested by diffuse myelopathic signs in three patients, by myeloradiculopathic signs in one patient, by radiculopathic signs in one patient, and by unilateral pyramidal-sensory signs in one patient (case 5); they did not occur in any patient with Brown-Séquard syndrome. Like the patients with posttraumatic herniation, the patients with an iatrogenic origin experienced a long delay before the onset of clinical signs and symptoms of spinal cord herniation, averaging 15.5 years from fixation wire placement and 10.2 years from cervical laminectomy. It is presumed that failure to close the dura resulted in persistence of the dural defects.

The mechanisms for the dural defects in the 24 thoracolumbar herniations are less obvious. It is presumed that trauma precipitated the dural tears in the seven patients with known previous trauma. In our case 2, we found a nuclear trail sign (Fig 2D) at the level of the dural defect, which had not been reported previously. Such densities at the level of the disk or vertebral endplate have been proposed to represent sclerotic changes in the path of a previously herniated nuclear disk fragment, present in up to 45% of thoracic disk herniations (19). It is likely that our case 2 had suffered a herniated thoracic disk at the time of his trauma 3 years prior to presentation, evidenced now only by the nuclear trail sign.

A congenital abnormality is suggested in case 1 by the presence of a nerve root traversing the central portion of the dural defect into the epidural space (Fig 1B). Additionally, the associated lobule of herniated cord once surgically released fell back against the cord but did not seem to flatten into the cord (Fig

1C), suggesting the cord may have been malformed congenitally. There were no congenital anomalies of the spine reported among the remaining 16 spontaneously occurring spinal cord herniations, although it is possible that dural defects may have been congenitally present or acquired by subclinical trauma. Thus, the mechanism of the dural defect remains obscure in these 17 cases.

A mechanism for spinal cord herniation through an established dural defect has been proposed by Kumar et al (12). When the dural defects are situated dorsally at the cervical level or ventrally at the thoracic level, the cord is closer to such defects, owing to the normal curvature of the spine, which positions the cord more dorsally at cervical levels and more ventrally at thoracic levels. Both the cord and dura are normally mobile, with motion in the craniocaudal direction during spine flexion and extension, and pulsatile motion in the anteroposterior direction at both respiratory and cardiac rates. Kumar et al proposed that these anteroposterior movements might be exaggerated in the presence of a dural pouch or cyst. Indeed, Goodman and Gregorius (2) directly observed increased cord bulging through a dorsal cervical dural defect into an extradural cyst with each heartbeat, and more so with each respiration. Uchino et al (17) proposed that as cord herniation occurs, the meninges opposite to the direction of the herniation may be pulled with the herniated cord, resulting in an invagination and duplication of the arachnoid, which may form arachnoid cysts. Cysts were found intraoperatively in nine (30%) of the cases. Adhesions may develop as the cord comes into sustained dural contact. As the adhesions and the herniated cord itself block CSF communication with any cyst, pseudomeningocele, or duplicated dural pouch at the defect, the normal CSF pulsations within the spinal canal may further increase the degree of cord herniation and incarceration, thus accounting for the progressive nature of the clinical deficits. Intraoperative sonographic monitoring of spinal cord motion has shown that cord motion is maximal in the areas of most severe disease (20). However, the long delay in onset of symptoms among posttraumatic patients would suggest that the pathophysiology is an insidious process.

Although the dura is considered a pain-sensitive structure, pain was reported in only 12 (40%) of the 30 cases. Pain was least frequently reported among

the spontaneously occurring spinal cord herniations, affecting only 23% of such patients. Among posttraumatic and iatrogenic herniations, pain was reported in the majority (61%) of cases.

Imaging studies characteristically show the cord appearing small, rotated, and displaced, with an apparently dilated CSF space opposite to the direction of cord displacement (Fig 2A). This apparently dilated CSF space represents the void left by the herniated cord. In such cases, the CSF space would be expected to follow the signal characteristics of normal CSF on MR sequences (Figs 1A and 2A) and to fill readily with intrathecal contrast material (Fig 2B). This could also be interpreted as an expansive communicating arachnoid cyst compressing the cord or as spinal cord adhesions from posttraumatic or postoperative fibrosis that have tethered the cord to the dura against the wall of the spinal canal. Axial images may be helpful in distinguishing a compressed cord from a herniated cord, especially if the dural defect has allowed only the lateral portion of the cord to herniate into bony defects or notches (Figs 2C, 4B, and 5).

Surgical release of the incarceration, with repair of the dural defect appears to result in a good outcome in most patients. Although long-term follow-up was not available for all patients, only one patient (our case 2) worsened after surgery. This patient's MR examination showed T2-weighted hyperintensity within the cord (Fig 2E). Similarly, intramedullary hyperintensity was seen in case 4 (Fig 4B), and this patient did not display clinical improvement postoperatively. Such MR findings may predict less potential for recovery. Four (13%) of the 30 patients made a full recovery and three (10%) had initial worsening followed by clinical improvement.

Conclusion

Herniation of the spinal cord is a rarely encountered cause of myelopathy. Previously unreported clinical features include unilateral isolated pyramidal signs (case 2) and unilateral pyramidal-sensory signs (case 5). Previously unreported imaging features include a nuclear trail sign (case 2), dorsally directed thoracolumbar herniations (cases 3 and 4), an apparent syrinx (case 3), and intramedullary hyperintensities on T2-weighted MR images (cases 2 and 4). The most common manifestation is a thoracic level Brown-Séquard syndrome from an anterior cord herniation, typically occurring spontaneously in women and posttraumatically in men. Dorsally directed cord herniations characteristically occur iatrogenically at cervical levels and may include root symptoms. There is typically a delay of several years to decades between the clinical presentation and any antecedent trauma or spinal surgery. Deficits are progressive and, with surgical intervention, recovery is often excellent. Imaging studies showing a small rotated cord displaced ventrally or dorsally at the thoracolumbar levels, or

displaced dorsally at the cervical level, and a communicating, apparently dilated, CSF space are suggestive of transdural spinal cord herniation.

Acknowledgments

We acknowledge, with much appreciation, the following contributors to this article: Jay S. Ogsbury, Clinical Assistant Professor of Surgery, Division of Neurosurgery, the University of Colorado Health Sciences Center, for his assistance in providing clinical and intraoperative descriptions for case 1; Anne Giuliano, Resident in Radiology, the University of Utah School of Medicine, for her assistance in providing clinical and imaging data for cases 3 and 4; and Virginia Fukumoto for her work in manuscript preparation.

References

1. Cobb C, Ehni G. **Herniation of the spinal cord into an iatrogenic meningocele.** *J Neurosurg* 1973;39:533-536
2. Goodman SJ, Gregorius FK. **Cervical pseudomeningocele after laminectomy as a cause of progressive myelopathy.** *Bull L A Neurol Soc* 1974;39:121-127
3. Wortzman G, Tasker RR, Rewcastle NB, Richardson JC, Pearson FG. **Spontaneous incarcerated herniation of the spinal cord into a vertebral body: a unique cause of paraplegia.** *J Neurosurg* 1974;41:631-635
4. Burres KP, Conley FK. **Progressive neurological dysfunction secondary to postoperative cervical pseudomeningocele in a C4 quadriplegic.** *J Neurosurg* 1978;48:289-291
5. Masuzawa H, Nakayama H, Shitara N, Suzuki T. **Spinal cord herniation into a congenital extradural arachnoid cyst causing Brown-Séquard syndrome.** *J Neurosurg* 1981;55:983-986
6. Sachdev VP, Huang YP, Shah CP, Malis LI. **Posttraumatic pseudomeningocele (enlarging fracture?) in a vertebral body.** *J Neurosurg* 1981;54:545-549
7. Mizuno J, Nakagawa H, Iwata K. **Postoperative spinal cord herniation diagnosed by metrizamide CT: a case report.** *Neurol Surg (Tokyo)* 1986;14:681-685
8. Dunn V, Smoker WRK, Menezes AH. **Transdural herniation of the cervical spinal cord as a complication of a broken fracture-fixation wire.** *AJNR Am J Neuroradiol* 1987;8:724-726
9. Izu T, Iizuka T, Iwasaki Y, Nagashima M, Akino M, Abe H. **Spinal cord herniation associated with an intradural spinal arachnoid cyst diagnosed by magnetic resonance image.** *Neurosurgery* 1991;29:137-139
10. Tronnier VM, Steinmetz A, Albert FK, Scharf J, Kunze S. **Hernia of the spinal cord: case report and review of the literature.** *Neurosurgery* 1991;29:916-919
11. Nakazawa H, Toyama Y, Satomi K, Fujimura Y, Hirabayashi K. **Idiopathic spinal cord herniation, report of two cases and review of the literature.** *Spine* 1993;18:2138-2141
12. Kumar R, Taha J, Greiner AL. **Herniation of the spinal cord.** *J Neurosurg* 1995;82:131-136
13. Borges LF, Zervas NT, Lehrich JR. **Idiopathic spinal cord herniation: a treatable cause of the Brown-Séquard syndrome (case report).** *Neurosurgery* 1995;36:1038-1033
14. Urbach H, Kaden B, Pechstein U, Solymosi L. **Herniation of the spinal cord 38 years after childhood trauma.** *Neuroradiology* 1996;38:157-158
15. Miura Y, Mimatsu K, Matsuyama Y, Yoneda M, Iwata H. **Idiopathic spinal cord herniation.** *Neuroradiology* 1996;38:155-156
16. Hausmann ON, Moseley IF. **Idiopathic dural herniation of the thoracic spinal cord.** *Neuroradiology* 1996;38:503-510
17. Uchino A, Kato A, Momozaki N, Yukitake M, Kudo S. **Spinal cord herniation: report of two cases and review of the literature.** *Eur Radiol* 1997;7:289-292
18. Brown-Séquard CE. **Lectures on the physiology and pathology of the nervous system, and on the treatment of organic nervous affections, lecture II: on organic affections and injuries of the spinal cord producing some of the symptoms of spinal hemiplegia.** *Lancet* 1869;1:1-3, 219-220, 703-705, 873-876
19. Awwad EE, Martin DS, Smith KR. **The nuclear trail sign in thoracic herniated disks.** *AJNR Am J Neuroradiol* 1992;13:137-143
20. Jokich PM, Rubin JM, Dohrmann GJ. **Intraoperative ultrasonic evaluation of spinal cord motion.** *J Neurosurg* 1984;60:707-711