

Are your MRI contrast agents cost-effective?
Learn more about generic Gadolinium-Based Contrast Agents.



AJNR

Complete myelography with metrizamide.

A J Fox, F Vinuela and G Debrun

AJNR Am J Neuroradiol 1981, 2 (1) 79-84
<http://www.ajnr.org/content/2/1/79>

This information is current as
of April 18, 2024.

Complete Myelography with Metrizamide

Allan J. Fox¹
 Fernando Vinuela
 Gerard Debrun

Thorough myelography of the entire spinal cord including the foramen magnum region can be accomplished consistently and promptly after metrizamide injection via lumbar or lateral cervical puncture. When lumbar puncture is used the patient's torso is oblique, but the neck is prone and straight and the table is tilted 20° head-down to allow direct cervical filling with contrast material. Each region is filmed in several projections, the patient being turned gently from the prone cervical to the supine thoracic position. Of 100 cases without block studied in this way, all had adequate cervical and foramen magnum films. In only five was the contrast material too dilute to show the edges of the spinal cord well and the subarachnoid sac adequately in the thoracic region. In 29 patients, there were mild side effects not requiring medication, while 20 had side effects of a more moderate to severe nature. No seizures were encountered. Metrizamide proved a convenient, efficient, and acceptable contrast medium for myelography when a study of the entire spinal cord is indicated.

Since the introduction of metrizamide in the last decade [1-4], there have been numerous clinical reports of its use for myelography of cervical and thoracic regions [1-17]. Depending on the approach of specific authors, metrizamide has been injected in varying amounts and concentrations via lumbar puncture, lateral C1-C2 puncture, or suboccipital puncture. Films have been obtained as spot films, overhead films, or tomograms, depending both on the technique and on the equipment available in the respective radiology departments. While generally the myelographic quality in the area of interest has been good, examining more than one region of the spine as part of the same procedure has decreased the chance for success [6, 18, 19] due to the limitations of metrizamide dose and dilution produced by excessive movement [2]. We describe the use of metrizamide as the primary myelographic contrast medium for "complete myelography" in patients being studied for myelopathy or radicular symptoms referable to the cervical region.

Materials and Methods

In the first 12 months after its introduction in our area, 228 myelographic studies were performed with metrizamide in our radiology department. There were 109 myelograms for lumbar radicular or cauda equina problems and 119 for cervical radicular or myelopathy problems.

The 100 (of 119) metrizamide myelograms that showed no block and were performed for radicular cervical or spinal cord problems formed the basis of this study. We had some previous experience with metrizamide when its availability was limited. Although the technique we used was reasonably standardized, the study participants included five radiology house staff members who were introduced to metrizamide myelography for the first time. Thus, the prime operator in each case had a variable background. Myelograms that showed a complete or almost complete block were excluded because the best metrizamide films are easily obtained at an intraspinal block, making these myelograms technically different from cases without block.

Received June 2, 1980; accepted after revision August 26, 1980.

Presented at the annual meeting of the American Society of Neuroradiology, Los Angeles, CA, March 1980.

¹All authors: Departments of Diagnostic Radiology and Clinical Neurosciences, University Hospital, University of Western Ontario, London, Ontario, Canada N6A 5A5. Address reprint requests to A. J. Fox.

AJNR 2:79-84, January/February 1981
 0195-6108/81/0021-0079 \$00.00
 © American Roentgen Ray Society

Technique

Patients were premedicated with 10 mg Valium by mouth about 40 min before myelography and were well hydrated before and after. Antiemetics and analgesics were used only if necessary. In most instances the myelogram was ended in the erect position, and patients were kept upright subsequently.

Injection via a 22 gauge needle of a full 6.75 g bottle of metrizamide (3.26 g organically-bound iodine), generally diluted to 250 mg/ml (about 13 ml) was done in most cases. There were 45 myelograms injected from above, all via lateral C1–C2 puncture except for one suboccipital puncture. Lateral C1–C2 puncture was performed, generally with the patient in the prone position with the table horizontal.

There were 55 myelograms injected via lumbar puncture. All but four of these were injected with the torso turned obliquely to a semilateral decubitus position, while the head and neck were in a straight prone extension position with the table about 20°–30° Trendelenburg. This position, in most instances, allowed for *direct cervical filling of metrizamide via lumbar puncture* with only minimal dilution (technique adapted from Swick et al. [20]). This injection technique promotes nonturbulent flow of contrast medium to the neck. As an adjustment of this approach for those few cases exhibiting lumbar radicular problems in addition to myelopathy, four cases had a lumbar study performed first. The same 250 mg/ml concentration of metrizamide was used for the lumbar films in a prone, horizontal position, followed by gentle movement of metrizamide to the cervical region by the oblique torso, prone neck, Trendelenburg positioning.

Well collimated films were obtained in several projections using fluoroscopic centering and phototimed spot filming. Cervical and anteroposterior foramen magnum films were done prone with the table horizontal, using 75 kV for anteroposterior and oblique films (fig. 1), and 85–95 kV for lateral and swimmers position films. Subsequently the patient was assisted to gently turn supine, and films were obtained of the foramen magnum (lateral) and thoracic region (fig. 2) using 70 kV in all projections. Subsequently the patient was put into an erect position, with support if necessary, and films obtained of the lumbar area (fig. 3) using 70–80 kV. In cases of suspected syringomyelia, additional films of the suspicious region were obtained erect and Trendelenburg to attempt to image cord collapse (fig. 4). Filming was generally completed within 15 min after metrizamide injection.

Filming was performed according to this protocol regardless of whether the injection of metrizamide was via lumbar puncture or lateral C1–C2 puncture, except for the four cases with lumbar myelography first. In those instances, the lumbar films were done with 80–90 kV because of the high concentration of contrast material. After the movement of contrast material to the cervical region, the filming of the rest of the spine was according to the above scheme.

Review Procedure

The 100 metrizamide myelograms were reviewed retrospectively with reference to injection site, film quality, and side effects. Except for one case with cross-table lateral films taken without a fluoroscope, all films were spot films done using Siemens Orbiskop in various positions. Films of each area of interest were rated according to quality as excellent, good, adequate, poor, or not done. Films were rated as *good* or *excellent* if all information concerning the edges of the sac, edges of the spinal cord, and small intraarachnoidal structures (e.g., nerve roots) (fig. 5) was visible, the differences between good and excellent being a degree of slight dilution. Films were rated as *adequate* if the edges of the sac and of the

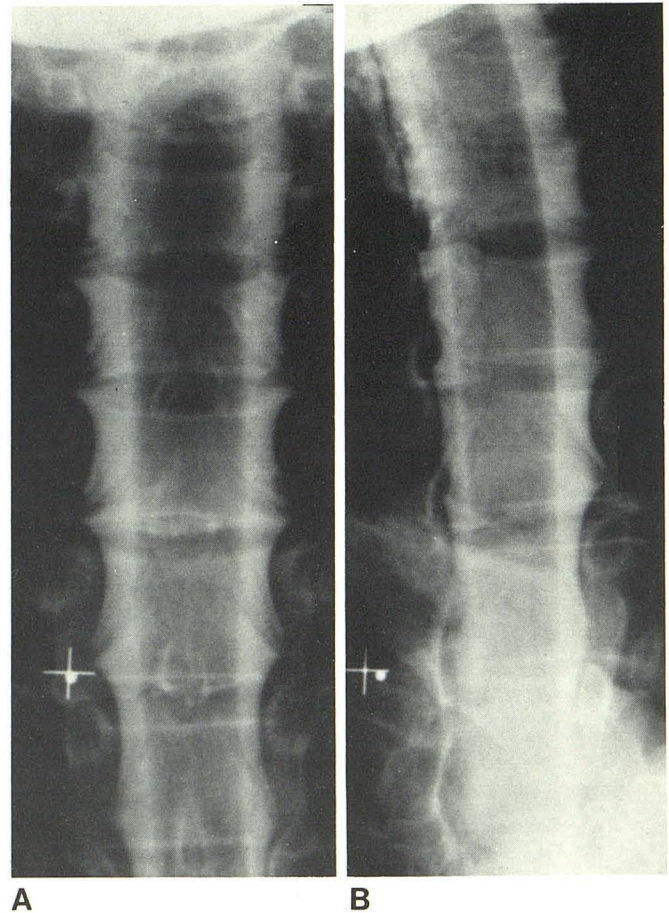


Fig. 1.—Excellent anteroposterior (A) and oblique (B) films of cervical region after direct cervical filling via lumbar puncture technique.

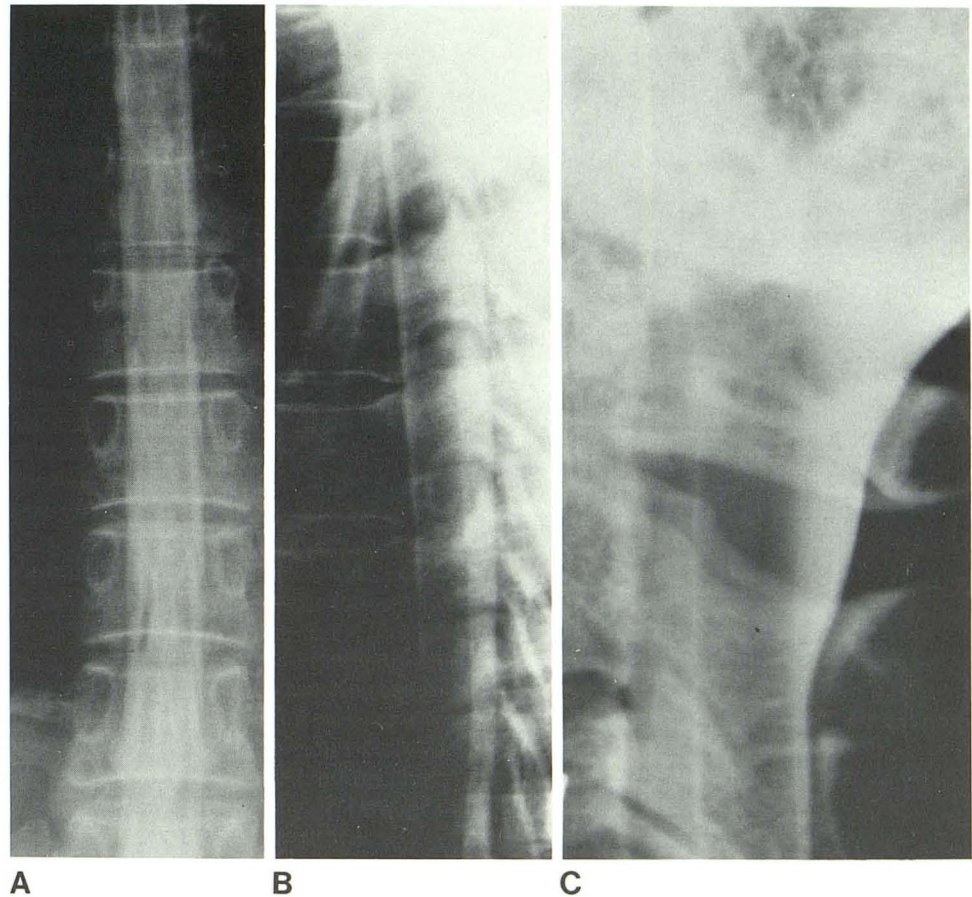
spinal cord were seen, although due to dilution small intraarachnoidal structures were not clear (fig. 6). Films were called *poor* if one could not distinguish all sac or cord edges throughout. Films not available were recorded as *not done* without knowing whether the films were not done because of excessive dilution, clinical judgment, or nonavailability.

Side effects were evaluated retrospectively from the clinical records, especially nurses' notes. Side effects were rated as mild if the patient had complaints but did not require analgesic or antiemetic medication and were only of short duration (1–2 hr). They were rated as moderate to severe if complaints necessitated medication or persisted for more than a short time.

Results

Quality of films in the 51 myelograms performed via lumbar puncture, cervical films first, is listed in table 1. Virtually all the cases showed optimal cervical and foramen magnum films. Most thoracic and lumbar films were also optimal (excellent or good), although seven thoracic and 10 lumbar films were in the category adequate where small intraarachnoidal structures were not well seen throughout. One case was extremely dilute in the lumbar and thoracic regions. In three instances CT was added to image the foramen magnum region due to some doubts and in all three

Fig. 2.—Excellent anteroposterior (A) and lateral (B) films of thoracic region obtained supine after cervical study. Lateral foramen magnum (C) in same position.



myelographic findings were confirmed. The four cases in which the lumbar region was studied before the cervical-foramen magnum-thoracic regions all showed good or excellent films at all levels (table 2).

Quality of films in the 45 myelograms performed via lateral C1-C2 puncture is listed in table 3. While the foramen magnum and cervical regions usually had optimal films, 11 thoracic and 11 lumbar were adequate, and four thoracic and three lumbar were poor. The vast majority of those that were dilute were in cases studied for cervical spondylosis. In two instances CT was added as confirmation in the cervical region, with no additional findings. One case was repeated with oil, which confirmed the findings in the thoracic region.

Side effects are recorded in table 4. One-half the patients had no complaints of side effects, 29% had mild effects, and 21% had moderate or severe side effects (i.e., problems requiring medication or prolonged complaints). No patients had seizures. The four cases that had lumbar myelography before the complete study all showed side effects.

Discussion

Most reports on metrizamide myelography describe techniques for selected regions of the spine [1, 2, 4-6, 8-11,

13-15, 17]. While those approaches will consistently produce good quality studies of those areas, the general feeling has been that it was difficult to obtain a *complete* myelographic study. A previous report on *complete* myelography [7] in fact refers to lumbar and cervical myelography as part of the same study rather than to *complete* myelography. If a block is present, any sensible approach will produce a successful study of that region. However, if no block is present, a suspected myelopathy should be studied all the way to the foramen magnum. All intramedullary lesions, including those with signs referable to the thoracic region, require a foramen magnum study for the possibility of a coexisting Chiari malformation. Intramedullary tumors can be extensive over many segments. Schwannomas, usually extramedullary intradural lesions, can be multiple even if presentation is at one level only; this is similar for extradural metastases. Arteriovenous malformations can also extend over many segments.

The sequence of cervical-foramen magnum-thoracic-lumbar study reviewed here is an efficient and relatively simple way of producing a complete myelographic study. Few cases had films with less than optimal quality. We had the advantage of the multiprojection spot film ability of Siemens Orbiskop. Any biplane fluoroscopy room with some table tilting ability would be equivalent. Without a lateral spot film

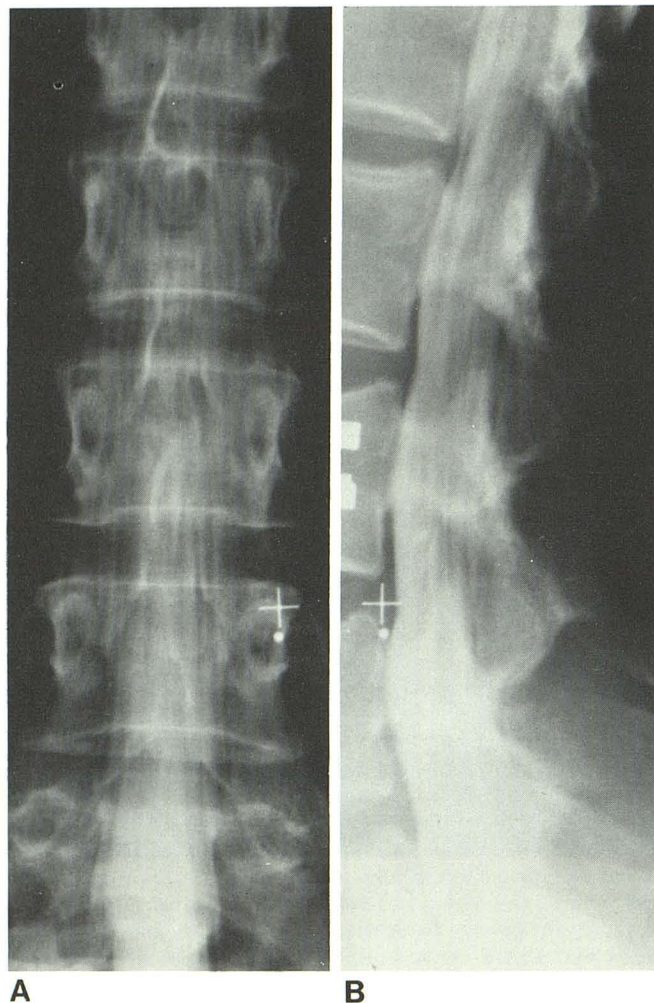


Fig. 3.—Good anteroposterior (A) and lateral (B) films of lumbar region obtained erect after cervical and thoracic filming.

ability this myelography approach can still be used but only with skilled technicians who can promptly produce excellent cross-table lateral radiographs.

It is uncommon for a patient to have signs and symptoms requiring both a high detail lumbar myelogram and a good complete spinal cord study. When this series was begun, this situation remained an indication for oil myelography [19]. However, obtaining the lumbar myelogram before the complete study, as in four of our cases, gives a high level of confidence to conduct the procedure with metrizamide (table 2), although there is the suggestion that the incidence of side effects might be more common (table 4) with this sequence.

The side effects reported here are certainly acceptable in comparison with those after air or complete oil myelography with large volumes and/or supine thoracic studies. The spinal cord is more easily imaged in several projections and without the time-consuming and meticulous technique of air myelography [19]. Since metrizamide is water soluble, it bathes the cord all around with contrast material, making delineation of the cord more complete than with oil [16]. In

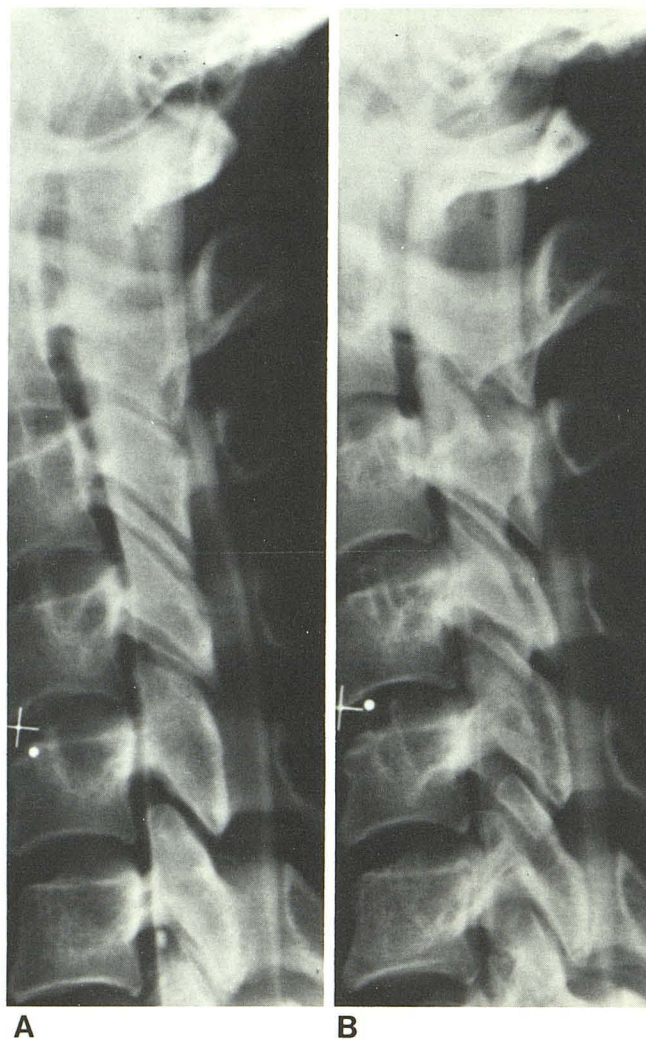


Fig. 4.—“Collapsing cord” of syringohydromyelia shown by gravity positioning. A, Erect lateral view. Cord enlarged from C3–C4 level downward. B, Supine 20° Trendelenburg position. Cord “collapsed” to more normal size. Herniated tonsil also seen down to C1 arch.

addition, since aspiration of metrizamide is unnecessary, supine study can be performed without repuncture.

The side effects documented here are perhaps surprisingly few, despite exceeding slightly the maximum recommended dose of 3 g organically-bound iodine. We believe that this is due both to patient hydration and positioning. In most cases metrizamide entered *directly* into the cervical region (whether by lumbar or C1–C2 puncture), and the final myelographic position was erect. This sequence tends to minimize rapid flow of metrizamide intracranially.

An adjunct study must be performed if an area of clinical interest is less than optimally seen. The most convenient protocol is metrizamide myelography followed by CT, although conventional tomography is also an option. Occasionally, repeat myelography oriented to one region is necessary. In our 100 cases without block studied with metrizamide, five had CT to confirm the findings of a somewhat dilute myelogram and one case with intramedullary thoracic cord enlargement had an oil myelogram as a second study. In none of these were there any additional findings.

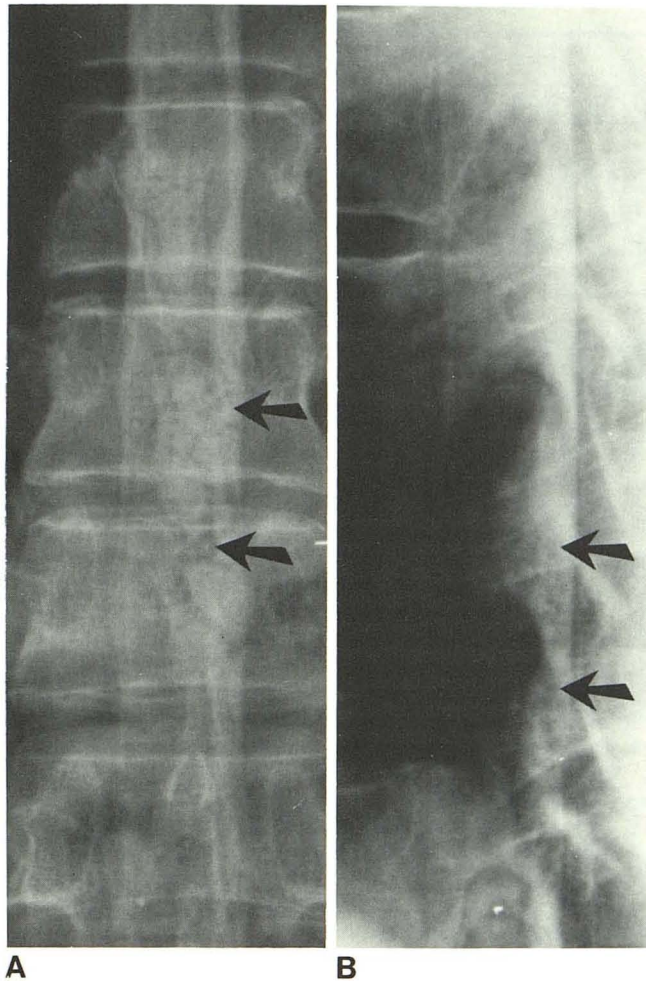


Fig. 5.—Retromedullary thoracic arteriovenous malformation shown as filling defect (arrows) within contrast material on good anteroposterior (A) and lateral (B) films despite some dilution of contrast material.

TABLE 1: Film Quality (Lumbar Injection; Cervical Films First)

Region	No. Cases (n = 51)				
	Excellent	Good	Adequate	Poor	Not Done
Foramen magnum	38	11	1	0	1
Cervical	45	6	0	0	0
Thoracic	13	29	7	1	1
Lumbar	11	22	10	1	7

There are three technical reasons why oil myelography may be preferable: (1) for very obese patients; (2) for patients who cannot hold their breath for some of the 2–4 sec low kV exposures; and (3) when it is desirable to leave oil in for follow-up study. During the 12 month period of our study, 11 more myelograms were obtained with oil. Most were due to lack of confidence in metrizamide for the thoracic region or for problems requiring a good lumbar study in addition to the cord myelogram. This doubt was

Fig. 6.—Adequate lateral lumbar film despite greatly diluted contrast. Block at L3–L4 due to spondylolisthesis.

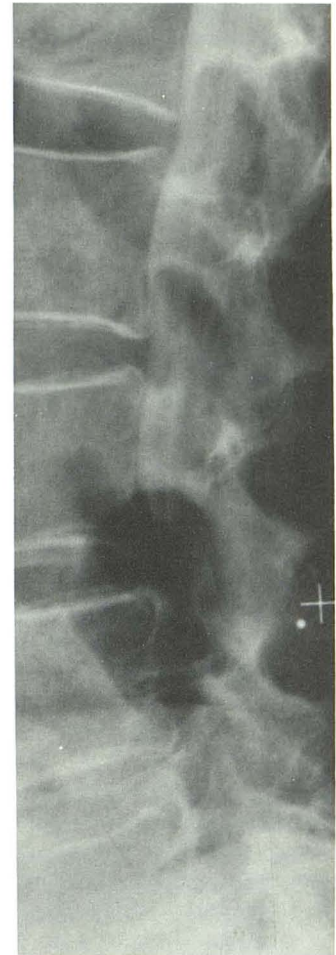


TABLE 2: Film Quality (Lumbar Injection; Lumbar Films First)

Region	No. Cases (n = 4)	
	Excellent	Good
Foramen magnum	2	2
Cervical	3	1
Thoracic	2	2
Lumbar	4	0

TABLE 3: Film Quality (C1–C2 Injection)

Region	No. Cases (n = 45)				
	Excellent	Good	Adequate	Poor	Not Done
Foramen magnum	37	4	0	0	4
Cervical	38	4	1	0	2
Thoracic	5	20	11	4	5
Lumbar	4	15	11	3	12

early in the series; lack of confidence in metrizamide is no longer an indication for oil myelography.

One more patient was studied with air during the period of this report. The problem was known thoracic arachnoiditis, and air was chosen as the most benign contrast medium

TABLE 4: Side Effects

Side Effects	Lumbar Puncture (Cervical Films First) (n = 51)		C1-C2 Injection (n = 45)		Lumbar Films First (n = 4)	
	Mild	Moderate/Severe	Mild	Moderate/Severe	Mild	Moderate/Severe
Headache	4	0	2	1	0	0
Nausea/emesis	5	4	5	3	1	1
Headache and nausea/emesis	6	4	4	6	0	1
Confusion	0	0	1	0	0	1
Back pain	1	0	0	0	0	0
Total Effects	16	8	12	10	1	3

available. (The patient was later reexamined with metrizamide to obtain better detail with several projections at the block). Since there is no evidence to suggest that metrizamide will aggravate preexisting arachnoiditis, this is not an obligatory indication for air. While cord atrophy has been claimed to be best studied with air [3], this series includes three cases of cord atrophy clearly shown with the appropriate exposures. This series also shows that complete cord study with metrizamide, including the foramen magnum region, can be well tolerated, despite claims that air is the method of choice for subarachnoid study of the craniovertebral junction [10]. Air classically has been used as the technique to demonstrate changes in cord size and shape ("collapsing cord") [21]. Similar changes have been produced by gravity positioning on metrizamide myelography [22]. While one cannot claim that cord collapse is identical with metrizamide and air, delayed CT scanning following metrizamide injection [23] has revolutionized the recognition of spinal cord cystic lesions that are responsible for it.

On the basis of our experience, we believe that metrizamide can be the contrast medium of choice in virtually all patients requiring myelography, including undiagnosed myelopathies where a complete survey of the spinal cord is indicated. Good understanding of the spinal curvatures and sensible prediction of potential technical problems are essential for choosing the injection site and patient positioning in each case before metrizamide injection.

Filming of various regions should be precise and efficient. Different regions should be studied in the ideal position for that region (i.e., prone for cervical, supine for thoracic and foramen magnum, and prone or erect for lumbar). All metrizamide and patient movements should be smooth and gentle to prevent excessive dilution. If lumbar injection is done for the cervical region, then oblique positioning of the patient's torso with 20° Trendelenburg tilt of the table is suggested because it produces minimal turbulence of the contrast material. CT or conventional tomography should be available as an adjunct in case of excessive dilution of contrast material in areas of high clinical suspicion.

REFERENCES

- Amundsen P, Skälpe IO. Cervical myelography with a water-soluble contrast medium (metrizamide). *Neuroradiology* 1975;8:209-212
- Amundsen P. Metrizamide in cervical myelography. Survey and present state. *Acta Radiol [Suppl]* (Stockh) 1977;355:85-97
- Hindmarch T. Myelography with the non-ionic water-soluble contrast medium metrizamide. *Acta Radiol [Diagn]* (Stockh) 1975;16:417-435
- Skälpe IO, Amundsen P. Thoracic and cervical myelography with metrizamide. *Radiology* 1975;116:101-106
- Ahlgren P. Myelography with metrizamide using lumbar injection. *Acta Radiol [Suppl]* (Stockh) 1977;355:98-104
- Bergstrom K, Mostrom U. Technique of cervical myelography with metrizamide. *Acta Radiol [Suppl]* (Stockh) 1977;355:105-109
- Boyd WR, Gardiner GA. Metrizamide myelography. *AJR* 1977;129:481-484
- Cronquist S. Thoracic myelography with metrizamide. *Acta Radiol [Suppl]* (Stockh) 1977;355:65-76
- Cronquist S, Brismar J. Cervical myelography with metrizamide. *Acta Radiol [Suppl]* (Stockh) 1977;355:110-120
- Hindmarsh T. Metrizamide in selective cervical myelography. *Acta Radiol [Suppl]* (Stockh) 1977;355:127-134
- Kieffer SA, Binet EF, Esquerre JV, Hautman RP, Gross CE. Contrast agents for myelography: clinical and radiological evaluation of amipaque and pantopaque. *Radiology* 1978;129:695-705
- Sackett JF, Hausserman SA, Okagaki HI, et al. Myelography with metrizamide in intraspinal and spinal abnormalities. *Acta Radiol [Suppl]* (Stockh) 1977;355:135-140
- Skälpe IO, Sortland O. Thoracic myelography with metrizamide. *Acta Radiol [Suppl]* (Stockh) 1977;355:57-64
- Sortland O. Cervical myelography with metrizamide using lumbar injection. *Acta Radiol [Suppl]* (Stockh) 1977;355:141-153
- Sortland O, Skälpe IO. Cervical myelography by lateral cervical and lumbar injection of metrizamide. A comparison. *Acta Radiol [Suppl]* (Stockh) 1977;355:154-163
- Valk J. Myelography with metrizamide. *Medicamundi* 1976;21:164-177
- Valk J. Thoracic myelography with metrizamide. *Acta Radiol [Suppl]* (Stockh) 1977;355:77-82
- Baker RA. Spinal axis tumors. In: Wolpert SM, ed. *Multiple imaging procedures. Volume 2: Central nervous system*. New York: Grune & Stratton, 1979:191-207
- Hammerschlag SB. Degenerative spinal disorders. In: Wolpert SM, ed. *Multiple imaging procedures. Volume 2: Central nervous system*. New York: Grune & Stratton, 1979:129-161
- Swick HM, Sty JR, Haughton VM. Clinical evaluation of metrizamide for neuroradiology in children. *Ann Neurol* 1978;3:409-415
- Westberg G. Gas myelography and percutaneous puncture—dry s.c. cysts. *Acta Radiol [Suppl]* (Stockh) 1966;252:7-67
- Fox AJ, Barnett HJM, Debrun G. Amipaque myelography and C.T. in syringomyelia (abstr). *AJNR* 1980;1:112
- Vignaud J, Aubin ML, Jardin C. CT in 40 cases of syringomyelia (abstr). *AJNR* 1980;1:112