

Are your **MRI contrast agents** cost-effective?

Learn more about generic **Gadolinium-Based Contrast Agents**.



FRESENIUS  
KABI

caring for life

**AJNR**

## **Improved Lateral Cervical Spine Radiography through Halo Traction Device**

William O. Bank, Robert K. Kerlan, Jr. and Lawrence W. Kesselring

*AJNR Am J Neuroradiol* 1981, 2 (3) 282-283

<http://www.ajnr.org/content/2/3/282.citation>

This information is current as of April 19, 2024.

## Improved Lateral Cervical Spine Radiography through Halo Traction Device

William O. Bank,<sup>1,2</sup> Robert K. Kerlan, Jr.,<sup>1</sup> and Lawrence W. Kesselring<sup>2</sup>

Patients with instability of the cervical spine due to trauma, neoplasm, infection, or surgery wear halo traction devices for prolonged periods of time. While providing the requisite distraction and stability, the four post frame of this device frequently frustrates attempts to monitor the progress of healing with sequential radiographs in the following ways: (1) the metal frame and wide plastic shoulder plates are too dense to penetrate; (2) when angulation is used, frame superimposition frequently obscures the area of interest; (3) frontal and oblique films do not answer the critical question of alignment provided by the lateral view; and (4) the combined width of the frame and patient's shoulders exceeds the limits for pluridirectional lateral tomography.

The poor quality of diagnostic information on angled radiographs can be overcome by careful removal of the traction device to allow higher quality films. While the importance of the information gained frequently outweighs the inherent risks of this procedure, we recently chanced upon an excellent alternative that takes advantage of fundamental radiographic principles and does not risk transient instability.

### Technique

A 12.7–17.8 cm screen cassette is inserted between the four post frame and the patient's neck on one side (fig. 1). Depending on the level to be studied, the tube is angled slightly cephalad or caudad while maintaining strict laterality

to project the area of interest free from the frame nearest x-ray tube. If a slight discrepancy exists between the height of the shoulder piece on one side and that of the other side, this can be used to advantage when selecting the side to insert the film.

The advantage of this technique is readily apparent in the radiographs of a 50-year-old man with a C4 instability secondary to postoperative osteomyelitis. Figure 2A shows the difficulties encountered with standard lateral films. The superior quality of the small cassette lateral radiography (fig. 2A) speaks for itself.

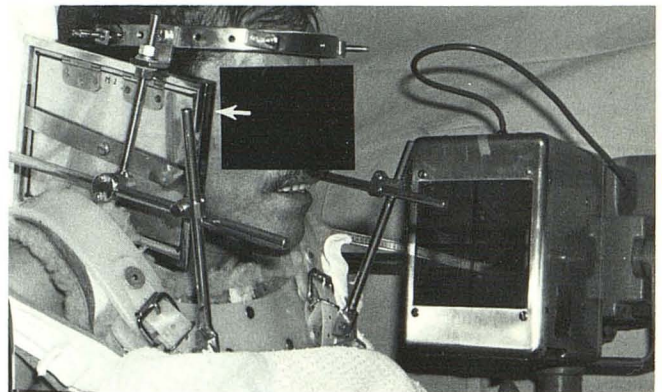
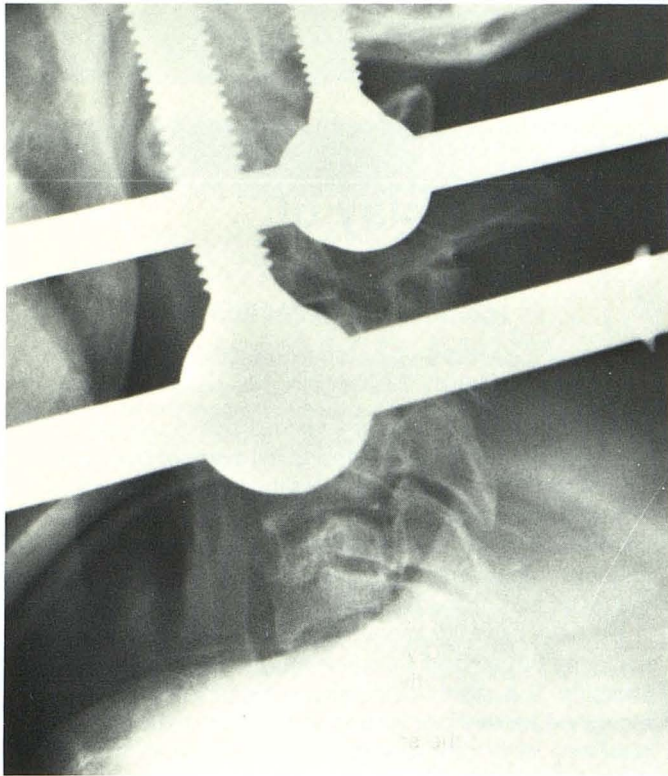


Fig. 1.—Supine patient with tube and small cassette (arrow) in position for lateral cervical spine film. Cephalad angulation projects frame near x-ray tube out of region of clinical interest.

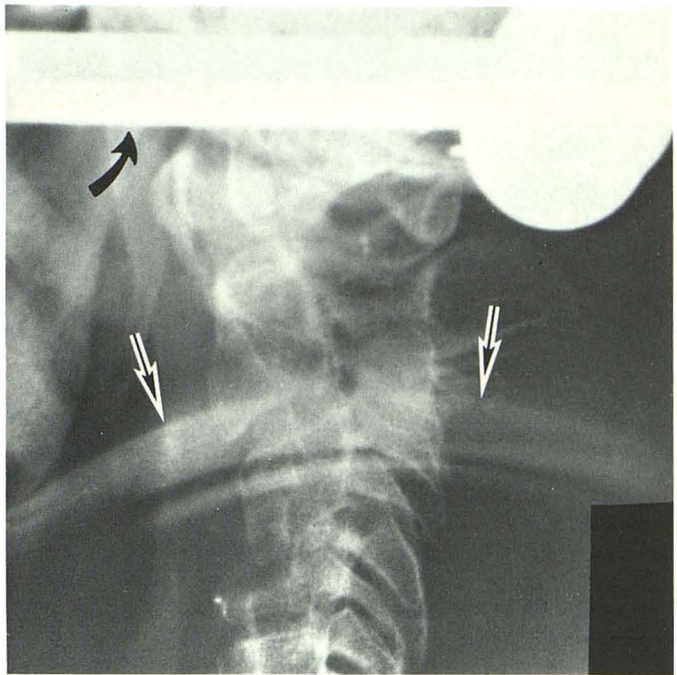
Received September 22, 1980; accepted November 6, 1980.

<sup>1</sup>Department of Radiology, School of Medicine, University of California, San Francisco, San Francisco, CA 94143.

<sup>2</sup>Radiology Service, Veterans Administration Medical Center, 4150 Clement St., San Francisco, CA 94121. Address reprint requests to W. O. Bank. This article appears in May/June 1981 *AJNR* and July 1981 *AJR*.



**A**



**B**

Fig. 2.—Same patient as in fig. 1. **A**, Standard lateral film of cervical spine without cephalad angulation. Superimposition of metallic frame near x-ray tube obscures area of clinical interest. **B**, Small cassette lateral film taken as seen in fig. 1. Surgical element absent from C3-C5. Curve artifact (*arrows*) is plastic shoulder plate on tube side. Frame projects superiorly away from area of interest.