

Are your **MRI contrast agents** cost-effective?

Learn more about generic **Gadolinium-Based Contrast Agents**.



FRESENIUS
KABI

caring for life

AJNR

Endovascular Treatment of Ruptured, Peripheral Cerebral Aneurysms: Parent Artery Occlusion with Short Guglielmi Detachable Coils

Harry J. Cloft, David F. Kallmes, Mary E. Jensen, Giuseppe Lanzino and Jacques E. Dion

This information is current as of April 18, 2024.

AJNR Am J Neuroradiol 1999, 20 (2) 308-310
<http://www.ajnr.org/content/20/2/308>

Case Report

Endovascular Treatment of Ruptured, Peripheral Cerebral Aneurysms: Parent Artery Occlusion with Short Guglielmi Detachable Coils

Harry J. Cloft, David F. Kallmes, Mary E. Jensen, Giuseppe Lanzino, and Jacques E. Dion

Summary: We report two cases of distal cerebral aneurysms that were treated by parent artery occlusion with short Guglielmi detachable coils (GDCs). One patient had a presumed mycotic aneurysm of the distal left posterior cerebral artery, and the other had a partially clipped aneurysm of the distal right anterior inferior cerebellar artery that had hemorrhaged. Short GDCs allow controlled, accurate occlusion of the parent artery at the aneurysmal neck.

Endovascular coil embolization of cerebral aneurysms with Guglielmi detachable coils (GDCs) is an acceptable alternative to surgery in selected patients (1). Distal, small aneurysms can be difficult to access with endovascular techniques, making it impossible to place GDCs within them. These aneurysms are often mycotic. Unruptured mycotic aneurysms may be treated with antibiotics alone, but ruptured mycotic aneurysms are usually treated surgically (2). The traditional surgical therapy for a mycotic aneurysm consists of parent artery occlusion and aneurysmal resection (2). Therefore, endovascular parent artery occlusion is an acceptable alternative for mycotic aneurysms. We report two cases of distal aneurysms that were treated by parent artery occlusion using short GDCs (Fig 1), which allowed controlled, accurate occlusion of the parent artery at the aneurysmal neck.

Case Reports

Case 1

A 63-year-old woman had a history of acute severe headache. CT examination revealed subarachnoid hemorrhage predominantly in the left parietooccipital region. She was noted to have a partial right homonymous hemianopsia related to her hemorrhage but was otherwise neurologically intact. Angiography revealed a small, distal left posterior cerebral artery aneurysm (Fig 2), compatible in appearance with a mycotic aneurysm. The patient initially refused surgery or endovascular treatment; however, 5 days after presentation, she reported a severe headache.

Received January 14, 1998; accepted after revision April 28.

From the Departments of Radiology (H.J.C., D.F.K., M.E.J., J.E.D.) and Neurosurgery (M.E.J., G.L., J.E.D.), University of Virginia Health Sciences Center, Charlottesville.

Address reprint requests to Harry J. Cloft, MD, PhD, Department of Radiology, Box 170, University of Virginia Health Sciences Center, Charlottesville, VA 22908.

© American Society of Neuroradiology

CT scans showed an acute left parietooccipital intraparenchymal hemorrhage, and the patient then requested endovascular treatment.

A decision was made to occlude the parent artery as close to the aneurysmal neck as possible. The microcatheter was advanced until the tip was just proximal to the aneurysm. A crescent-shaped GDC-10 coil (Target Therapeutics, Fremont, CA) was advanced through the microcatheter and into the parent artery until it was at the aneurysmal neck, where it was detached. This was followed by placement of a standard 0.010-in. 5-mm straight-fibered coil (Target Therapeutics, Fremont, CA), which was advanced through the microcatheter with a coil and deployed parallel to the GDC coil. Angiography performed immediately after coil placement showed occlusion of the parent vessel (Fig 2). The patient experienced no change in neurologic condition during coil embolization.

Case 2

A 49-year-old woman had an unruptured right distal anterior inferior cerebellar artery aneurysm, which was surgically clipped. She had complete right-sided sensorineural hearing loss as a result of this operation. Angiography performed to evaluate the hearing loss showed slow filling of only the proximal portion of the anterior inferior cerebellar artery and no filling of the aneurysm.

Ten months later, the patient had a severe headache and drowsiness consequent to subarachnoid hemorrhage. Except for her right-sided sensorineural hearing loss, she had no focal neurologic deficits. Angiography showed incomplete clipping of the right anterior inferior cerebellar artery aneurysm (Fig 3), and she was transferred to our institution for endovascular treatment.

A microcatheter was placed with the tip approximately 5 mm proximal to the aneurysmal neck and could not be advanced farther. Three 5-mm straight GDC-18 coils were placed in the anterior inferior cerebellar artery just distal to the microcatheter tip (Fig 3). Angiography showed occlusion of the anterior inferior cerebellar artery by the coils (Fig 3). The patient had no change in neurologic condition after coil embolization.

Discussion

The two patients reported here had distal aneurysms in which parent vessel occlusion at the aneurysmal neck was thought to be the best therapeutic alternative. Treatment was easily effected in both cases through the use of short GDCs, which allowed for controlled, accurate coil placement in quite distal locations.

The use of endovascular therapy for mycotic aneurysms has been reported in three cases by Khayata et al (3) and in one case by Frizzell et al (4).




FIG 1. 6-mm-long crescent-shaped GDC-10 coil (arrow indicates detachment zone).

Khayata and coworkers used *n*-butyl cyanoacrylate in one case, autologous clot in another, and platinum coils in the third. Frizzell et al used platinum coils in their case. Chaloupka et al (5) reported two cases of superior cerebellar artery aneurysms treated by parent artery occlusion with platinum microcoils. Treatment was successful in all these previously reported cases.

The controlled detachability of short GDCs allows them to be carefully positioned, repositioned, and even retrieved before they are detached. This is a significant advantage over coils placed with a coil pusher, in which they cannot be repositioned or retrieved once they are deployed. Introducing coils by using fluid is also somewhat uncontrolled, and could result in a higher prevalence of aneurysmal rupture because of the rapid burst of increased pressure that occurs when the coil is injected. Short

GDCs may even be navigated and detached some distance from the tip of a microcatheter in cases in which a catheter cannot reach the desired location but the coil and its delivery wire can. However, this maneuver should only be performed with great caution, because the relative stiffness at the junction of the delivery wire and coil could cause vessel injury and perforation, especially in cases of mycotic aneurysms, in which the parent artery may be inflamed and fragile.

The disadvantages of retrievable versus nonretrievable coils were recently pointed out in a letter by Debrun (6) responding to the report of two cases of superior cerebellar artery aneurysms by Chaloupka et al (5). Injecting *n*-butyl cyanoacrylate and autologous clot could also cause a rapid burst of increased pressure, especially since the microcatheter is likely to cause flow arrest when placed in small, distal arteries, as occurred in both our cases. Detachable balloons are often used for permanent occlusion in the treatment of aneurysms of the internal carotid and vertebral arteries, but currently available balloons are too large for use in distal, small arteries.

While the short GDCs worked well in the cases described here, there are potential disadvantages. The lack of fibers may result in less thrombogenicity relative to fibered coils. In case 1, once the short GDC was accurately placed and detached, we

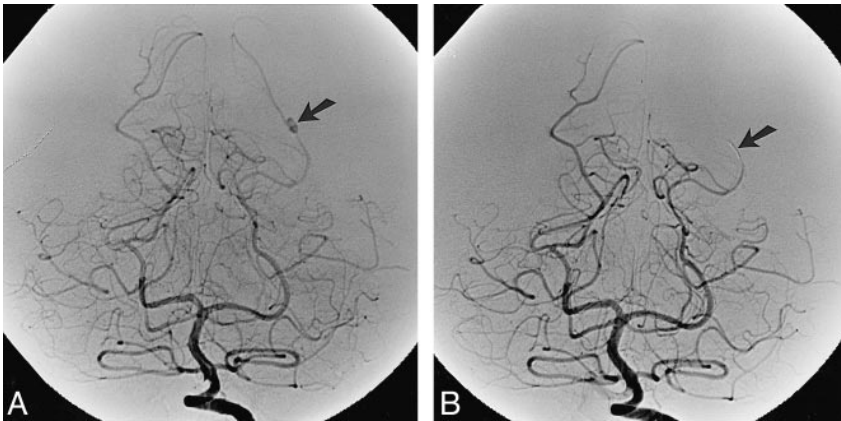


FIG 2. Case 1: angiograms show mycotic aneurysm treated with short Guglielmi detachable coils.

A, Initial angiogram before treatment shows distal left posterior cerebral artery aneurysm (arrow).

B, Arterial phase of angiogram after treatment shows parent vessel occlusion by coils (arrow).

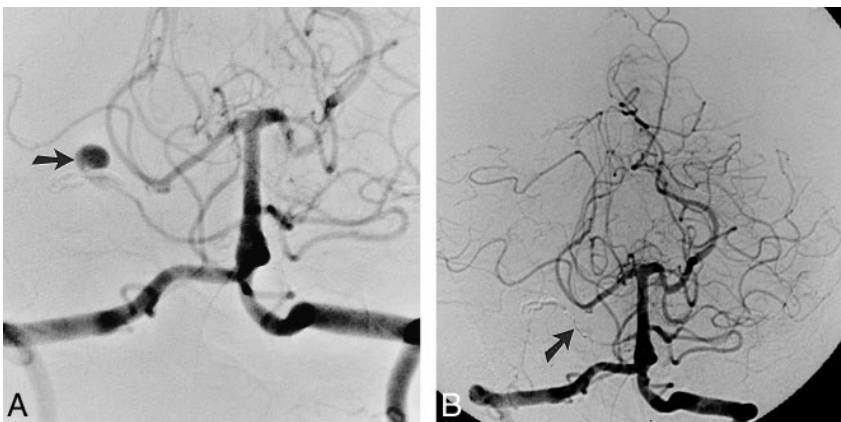

FIG 3. Case 2: angiograms show partially clipped aneurysm treated with short Guglielmi detachable coils.

A, Initial angiogram before treatment shows filling of distal right anterior inferior cerebellar artery aneurysm through unclipped neck laterally (arrow).

B, Arterial phase of angiogram after treatment shows parent vessel occlusion by coils (arrow) and no opacification of aneurysm.

thought it safe to place a standard fiber coil in an overlapping configuration. Another disadvantage of the short GDC is the potential for migration after detachment, owing to the fact that it has neither a curved configuration nor fiber bristles, both of which secure the coil by applying tension to the arterial wall.

Conclusion

GDCs have become an acceptable treatment for aneurysms, because their retrievability and controlled detachment allows them to be placed with great accuracy. These same features make short GDCs useful in the treatment of small, distal aneurysms by allowing reliable and predictable per-

manent occlusion of the parent artery near the aneurysmal neck.

References

1. Guglielmi G, Viñuela F. **Intracranial aneurysms: Guglielmi detachable coils.** *Neurosurg Clin N Am* 1994;5:427-435
2. Clare CE, Barrow DL. **Infectious intracranial aneurysms.** *Neurosurg Clin N Am* 1992;3:551-566
3. Khayata MH, Aymard A, Casasco A, Herbreteau D, Woimant F, Merland JJ. **Selective endovascular techniques in the treatment of cerebral mycotic aneurysms.** *J Neurosurg* 1993;78:661-665
4. Frizzell RT, Vitek JJ, Hill DL, Fisher WS. **Treatment of bacterial (mycotic) intracranial aneurysm using an endovascular approach.** *Neurosurgery* 1993;32:852-854
5. Chaloupka JC, Putman CM, Awad IA. **Endovascular therapeutic approach to the superior cerebellar artery.** *AJNR Am J Neuroradiol* 1996;17:1338-1342
6. Debrun G. **Retrievable versus nonretrievable coils (letter).** *AJNR Am J Neuroradiol* 1997;18:1389-1390