

Are your **MRI contrast agents** cost-effective?

Learn more about generic **Gadolinium-Based Contrast Agents**.



FRESENIUS  
KABI

caring for life

# AJNR

## **Benign Expansile Lesions of the Sphenoid Sinus: Differentiation from Normal Asymmetry of the Lateral Recesses**

Jonathan S. Lewin, Hugh D. Curtin, Elizabeth Eelkema and Nancy Obuchowski

This information is current as  
of April 17, 2024.

*AJNR Am J Neuroradiol* 1999, 20 (3) 461-466  
<http://www.ajnr.org/content/20/3/461>

## Benign Expansile Lesions of the Sphenoid Sinus: Differentiation from Normal Asymmetry of the Lateral Recesses

Jonathan S. Lewin, Hugh D. Curtin, Elizabeth Eelkema, and Nancy Obuchowski

**BACKGROUND AND PURPOSE:** There is a wide range of normal variation in sphenoid sinus development, especially in the size of the lateral recesses. The purpose of this study was to determine imaging characteristics that may help differentiate between opacification of a developmentally asymmetric lateral recess and a true expansile lesion of the sphenoid sinus.

**METHODS:** Coronal CT was performed in seven patients with expansile or erosive benign lesions of the sphenoid sinus, and results were compared to a control population of 72 subjects with unopacified sphenoid sinuses. The degree of asymmetry of lateral recess development was assessed with particular attention to the separation of vidian's canal and the foramen rotundum (vidian-rotundum distance). The images were also examined for evidence of: erosion, defined as loss of the normal thin bony margin on at least two contiguous sections; apparent thinning of the sinus wall, defined as a focal apparent decrease in thickness again on at least two contiguous sections; and for vidian's canal or foramen rotundum rim erosion or flattening.

**RESULTS:** Of the seven patients with expansile lesions, vidian's canal margin erosion was present in seven, unequivocal sinus expansion in three, wall erosion in three, wall thinning in three, erosion of the foramen rotundum in two, and flattening in the foramen rotundum in four. Forty-one of the 72 controls had lateral recess formation, 28 of which were asymmetric. The distance between vidian's canal and the foramen rotundum (vidian-rotundum distance) relied on the presence or absence of pneumatization, with a significantly larger distance in the presence of greater wing pneumatization. Examination of 24 controls revealed apparent thinning of the sinus wall, typically at the carotid groove, but no flattening, thinning, or erosion of the vidian canal or of the foramen rotundum.

**CONCLUSION:** Examination of controls and patients with expansile or erosive lesions of the sphenoid sinus revealed side-to-side asymmetry in the development of the sinus and lateral recess, making subtle expansion difficult to assess. Furthermore, variability in the vidian-rotundum distance correlated with degree of pneumatization, and did not necessarily reflect expansion. Thus, in the absence of gross sinus wall erosion, flattening or erosion of the rims of vidian's canal or the foramen rotundum provides the most specific evidence of an expansile or erosive process within the sinus.

Previous reports of sphenoid sinus mucocele suggest that sinus expansion is one of the imaging findings supporting this diagnosis (1, 2). Nonethe-

---

Received in original form July 19, 1996; accepted after revision November 17, 1998.

From the Department of Radiology (J.S.L.), University Hospitals of Cleveland and Case Western Reserve University, Cleveland, OH; the Department of Radiology (H.D.C.), The Eye and Ear Infirmary, Massachusetts General Hospital; Boston, MA; the Department of Radiology (E.E.), St. Clair Hospital, Pittsburgh, PA; and Department of Biostatistics (N.O.), The Cleveland Clinic Foundation, Cleveland, OH.

Address reprint requests to Jonathan S. Lewin, MD, Department of Radiology, University Hospitals of Cleveland, 11100 Euclid Avenue, Cleveland, OH 44106.

© American Society of Neuroradiology

less, the differentiation between sinus expansion and opacification of a developmentally asymmetric sphenoid sinus may be difficult in the absence of gross erosion of the sinus wall. In particular, the size of the lateral recesses of the sphenoid sinus, which extends outward from the main sinus cavities into the greater wing of the sphenoid bone, is highly variable and can make differentiation of normal asymmetry from pathologic expansion difficult. These air cells pass between vidian's canal and the foramen rotundum, resulting in variation in the distance between these two structures. The purpose of this study was to determine imaging characteristics that may help differentiate between opacification of a developmentally asymmetric lateral recess and an expansile lesion of the sphenoid sinus,

with particular attention to variation in the distance between vidian's canal and the foramen rotundum (vidian-rotundum distance).

### Methods

The study population consisted of seven patients with surgically confirmed expansile lesions of the sphenoid sinuses, and 72 control subjects without sphenoid sinus opacification. The patient group included two men and five women ranging from 12 to 51 years of age. Six presented with a sphenoid sinus mucocele and one with sphenoid sinus expansion from sinonasal polyposis.

The control cohort was obtained through random selection of 96 patients referred for CT of the paranasal sinuses during a 6-month period. Of the 96 examinations, 72 revealed unopacified sphenoid sinuses.

All subjects underwent coronal CT with 3-mm contiguous slices and high-resolution bone-algorithm reconstruction. The configuration and degree of asymmetry of the body and lateral recesses of the sphenoid sinus were assessed, with particular attention to vidian-rotundum distance, measured as the length between the nearest margins of the neural canals. Measurements were obtained by electronic calipers on the console for the control group and by mechanical calipers for the patient cohort (Fig 1). No attempt was made to standardize the angle of the plane of the CT scan. Occasionally, the foramen rotundum did not appear as a complete canal, and in these cases the inferior edge of the groove representing the foramen was used for measurement.

On the same image used to measure the vidian-rotundum distance, the degree of pneumatization of the greater wing of the sphenoid was assessed. Sinuses that were confined to the sphenoid bone medial to vidian's canal and the foramen rotundum were considered to have nonpneumatized greater sphenoid wings. If the sinus cavity extended lateral to a line connecting vidian's canal and the foramen rotundum, the greater wing of the sphenoid was considered pneumatized and the patient was considered to have lateral recess formation (Fig 1). The images were also examined for the following: erosion (loss of the normal thin bony margin on at least two contiguous sections); thinning of the sinus wall (focal apparent decrease in thickness on at least two contiguous sections); bony integrity of the margins of the foramen rotundum and vidian's canal; and areas of unequivocal sinus expansion (subjective enlargement resulting in gross distortion of the normal sinus contours) (Fig 2).

The largest vidian-rotundum distance in sinuses with greater wing pneumatization was compared to the vidian-rotundum distance in sinuses without greater wing pneumatization within the control group by using a Student's paired *t* test for comparison of pneumatized versus nonpneumatized sides in subjects with unilateral pneumatization. The Student's two-sample *t* test was used to compare subjects with bilateral pneumatization vs those without pneumatization. A significance level of .05 was used for both *t* tests. The use of the vidian-rotundum distance to discriminate between normal and expanded sinuses was evaluated through fitting a normal distribution to the largest vidian-rotundum distance of the controls, with values calculated to provide estimates of 95% and 99% specificity for an expansile process with a 95% confidence interval. The fit of the control data to a normal distribution was checked using the Shapiro-Wilk test; a significance level of .10 was applied to increase the power of the test to detect differences from normality.

### Results

#### Control Subjects

Of the 72 control subjects, 41 had lateral recess formation on at least one side, with unilateral for-

mation in 21, and bilateral formation in 20. Of the 20 patients with bilateral lateral recess formation, seven had a 1-cm or more increase of the lateral extent of the lateral recesses from side to side. Apparent thinning of the sinus wall was notable in 24 patients, most commonly at the indentation resulting from the internal carotid artery as it passed under the anterior clinoid process (Fig 2). Although there was variation in the configuration of vidian's canal (Fig 3), in no control subject was the margin of vidian's canal or the foramen rotundum flattened or eroded.

The average vidian-rotundum distance is presented in Table 1 for sinuses without lateral recess formation, with unilateral pneumatization on the nonpneumatized and pneumatized sides, and with bilateral pneumatization. Comparing the pneumatized to the nonpneumatized side in patients with unilateral lateral recess formation showed the vidian-rotundum distance was significantly larger on the pneumatized side ( $P=.001$ ). Likewise, when the vidian-rotundum distance was compared between sinuses without lateral recess formation and those with bilateral lateral recess formation, the vidian-rotundum distance was again significantly larger in those with greater pneumatization ( $P=.001$ ). In the control group, asymmetry of the vidian-rotundum distance between the right and left was never greater than 4.5 mm in any subject.

Using a normal distribution fit to the control data, a vidian-rotundum distance of greater than 11.4 mm suggested an expansile process with an estimated specificity of 99% (95% CI, 93%–100%).

#### Patient with Expanded Sinuses

Of the seven patients with expansile lesions, gross or unequivocal sinus expansion was present in three (Figs 4 and 5), wall erosion in three (Figs 4 and 6), wall thinning without focal erosion in three, erosion of the margin of vidian's canal in seven, erosion of the margin of the foramen rotundum in four (Fig 7), and flattening of the foramen rotundum in two (Fig 5). These results are outlined in Table 2. Erosion of vidian's canal appeared either as complete unroofing of the canal, leaving a shallow groove at the site of the nerve (Figs 4 and 5), partial disruption of the bony covering of the canal (Fig 7), or complete loss of canal form and structure (Fig 6).

The distance between the foramen rotundum and vidian's canal for each case is noted in Table 1. The vidian-rotundum distance was greater than 11.4 mm in two of these seven patients, both of whom had unequivocal expansion. The vidian-rotundum distance in the remaining five patients, including one with unequivocal sinus expansion (Fig 4) was less than this threshold. Two patients with bilateral but asymmetric expansion had greater than 5 mm of asymmetry in the vidian-rotundum distance between more and less affected sides, a greater

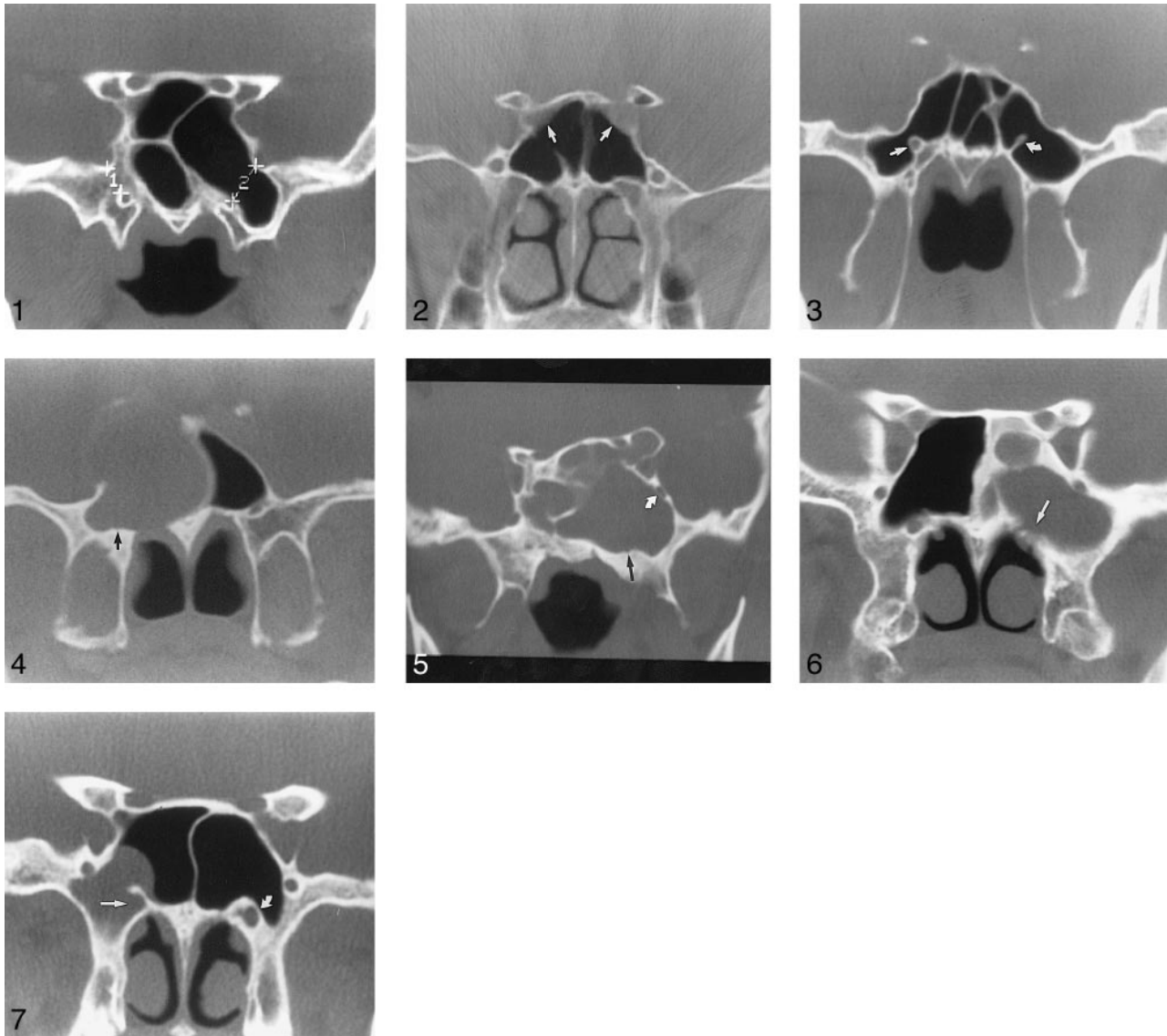


FIG 1. Coronal CT of a control subject. Measurement of the vidian-rotundum distance with electronic calipers shows a nonpneumatized greater sphenoid wing on the right (*caliper 1*), and a pneumatized greater sphenoid wing on the left (*caliper 2*). The vidian-rotundum distance was measured from the nearest bony margin of each canal, whether the foramen rotundum was visible on the coronal image as a semicircle, as noted in this subject, or as a complete ring.

FIG 2. Coronal CT of a control subject. The sinus wall adjacent to the groove for the internal carotid artery (*arrows*) was the most common site of thinning noted in the controls.

FIG 3. Coronal CT of a control subject with bilateral pneumatized greater sphenoid wings. The shape of vidian's canal varied from ovoid or circular in subject with nonpneumatized or slightly pneumatized greater wings (*straight arrow*), to an appearance of an "eye on a stalk" when the wing and pterygoid process were extensively pneumatized (*curved arrow*).

FIG 4. Mucoccele in a 46-year-old man (patient 1). Coronal CT reveals unequivocal expansion of the right sphenoid sinus. The wall of vidian's canal is eroded (*arrow*), as is the sinus roof, right lateral wall, and floor. The left rotundum margins are intact, and the left sphenoid sinus is clear. The vidian-rotundum distance was 7 mm on the affected side, and was best measured on an adjacent section (not shown).

FIG 5. Mucoccele in a 22-year-old woman (patient 3). Coronal CT reveals less pronounced but still unequivocal expansion of the sphenoid sinus, including enlargement of the anterior clinoid process. The margin of vidian's canal is eroded, with only a shallow groove remaining (*straight arrow*), while the foramen rotundum is flattened but not eroded (*curved arrow*). The floor of the sinus medial to vidian's canal was also eroded on an adjacent section (not shown). The vidian-rotundum distance on the affected side measured 16 mm, representing one of two patients with measurements greater than 11.4 mm.

FIG 6. Mucoccele in a 51-year-old woman revealed by coronal CT (patient 7). When unequivocal expansion is not present, as in this patient, erosion of the margin of vidian's canal (*arrow*) and sinus floor medial to canal (on adjacent section, not shown) suggest mucoccele rather than simple chronic sinusitis. The left foramen rotundum appears slightly thinned on this section, but did not demonstrate definite erosion on any adjacent image.

FIG 7. Mucoccele of lateral recess in a 46-year-old woman revealed by coronal CT (patient 2). Erosion of the lateral aspect of vidian's canal (*straight arrow*) and inferior foramen rotundum (*arrowhead*) represents the only features differentiating this mucoccele of the lateral recess of the sinus from a polyp or retention cyst. Compare eroded canal with normal contralateral canal (*curved arrow*). This very early surgically proven mucoccele had not yet resulted in unequivocal expansion or other areas of sinus wall erosion.

**TABLE 1: Control subjects: largest distance between vidian's canal and the foramen rotundum**

Subjects with:	Distance (mm)				Average Side-to-Side Asymmetry $\pm$ SD
	Mean (SE)	No. (n = 72)	Range		
No lateral recesses	4.5 (0.3)	31	0.4–8.5		1.0 $\pm$ 0.8
Unilateral lateral recess	6.0 (0.3)	21	0.3–9.2		2.2 $\pm$ 1.3
Bilateral symmetric lateral recesses	8.8 (0.4)	13	6.9–11.7		1.7 $\pm$ 1.0
Bilateral asymmetric lateral recesses	8.0 (0.6)	7	5.2–9.5		2.0 $\pm$ 0.4

degree of asymmetry in this measurement than that observed in any of the control subjects.

### Discussion

Asymmetry of the paranasal sinuses may reflect normal development, hypoplasia, aplasia, or pathologic enlargement. Actual expansion of a paranasal sinus is marked by remodeling of the sinus wall, and may occur with mucocele (3, 4), polyposis (5), slowly growing benign or malignant neoplasms (6), and pneumosinus dilatans (7). In clear, normally aerated sinuses, asymmetry is readily interpreted as incidental and is rarely noted. Nonetheless, asymmetry combined with sinus opacification can suggest pathologic dilatation of the sinus by tumor, polyposis, or, most commonly, mucocele. In addition, an opacified globally enlarged sphenoid sinus might occasionally be seen with pneumosinus dilatans in the presence of associated inflammatory changes (7).

The sphenoid sinuses are typically asymmetric, variably occupying the body and peripheral processes of the sphenoid bone. The body of the sphenoid bone develops from two paired ossification centers, the presphenoidal anteriorly, and the posts-

phenoidal posteriorly (8, 9). Laterally located ossification centers form the lingular and orbitotemporal portions of the sphenoid, the greater and lesser wings, and pterygoid processes (8, 9). Pneumatization of the sphenoid progresses from front to back (from the presphenoidal to the postsphenoidal centers), forming the main sphenoid sinus cavity that occupies the body of the sphenoid bone and occasionally extends into the dorsum sellae and posterior clinoid processes. Aeration of the more peripheral ossification centers result in pneumatization of the greater and lesser wings, and the anterior clinoid and pterygoid processes. The lines of fusion between the various ossification centers are thought to be zones of relative resistance to pneumatization. Persistence of bony ridges and crests as residua of the fusion lines accounts for the complex internal septations of the sphenoid sinus (10). Because the "flowing" pneumatization may take many different pathways from one ossification nucleus to the adjacent center, the internal septations demonstrate marked variability in size, orientation, and location with right and left sinuses typically asymmetric (11). Several excellent reviews are available outlining the normal development from a primitive, or undeveloped sinus, normal in newborns, to the sellar configuration with pneumatization of the postsphenoidal center, which occurs in the majority (71%–86%) of adults (12–16).

The lateral recess air cells extend into the greater wing of the sphenoid by passing above vidian's canal and below the foramen rotundum, separating these two neural canals by a variable distance. In those bones with the smallest values for vidian-rotundum distance, the cortical rims of the canals are often contiguous. For larger vidian-rotundum distances in nonpneumatized greater wings, cancellous bone is interposed between the two neural canals (Fig 1).

Examination of the results of the control subjects showed that pneumatization of the greater wing of the sphenoid bone, forming a lateral recess, is seen in the majority of subjects. In addition, 28 of the

**TABLE 2: Patients with sinus expansion: imaging findings and vidian's canal-foramen rotundum measurements**

Patient No.	1	2	3	4	5	6	7
Age (years)	46	46	22	12	38	29	51
Diagnosis	Mucocele	Mucocele	Mucocele	Mucocele	Mucocele	Polyposis	Mucocele
VC*	E†	E	E	E	E	E	E
FR‡	E	§F	F	F	F	E	NL
Wall Erosion or thinning	E	...	¶T	T	T	E	E
Unequivocal Expansion	yes	no	yes	yes	no	no	no
VC-FR (mm)							
Affected side	7	10	16	25	8	5	11
Unaffected side	4	7	8**	10**	4**	5	8
Affected minus unaffected VC-FR (mm)	3	3	8	15	4	0	3

\* VC = Vidian's canal, † E = erosion, ‡ FR = foramen rotundum, § F = flattening, ¶ T = thinning, || NL = normal, \*\* = less affected side with bilateral sinus expansion.

41 subjects with greater wing pneumatization had significant asymmetry, with either unilateral lateral recess formation or bilateral lateral recess formation with greater than 10-mm asymmetry in lateral extent. These results concur with the clinical observation that asymmetry of sphenoid sinuses is very common, confirming that asymmetry alone is unhelpful in assessment of sinus expansion. In addition, the results demonstrate dependence of the vidian-rotundum distance on the presence or absence of pneumatization, with a significantly larger vidian-rotundum distance in the presence of greater wing pneumatization.

Use of the vidian-rotundum distance to detect pathologic sinus expansion presents a method of questionable usefulness. Statistical analysis demonstrates a very high specificity for enlargement of this value, with an estimated specificity of 99% for distances of greater than 11.4 mm. Given the size of the control population, this value appears to have statistical power, with a relatively narrow 95% confidence interval. The limited use of this measurement, however, can be inferred by the observation that only two of the seven patients with expansile lesions demonstrated enlargement beyond this threshold (Fig 3), with five of seven patients showing vidian-rotundum distances within the normal range. This included one of the remaining three patients in whom unequivocal sinus expansion was present (Fig 2). Within the control population, one of the 144 vidian-rotundum measurements in the 72 subjects would suggest sphenoid sinus disease by this criterion. It is unlikely that greater than 11.4-mm widening would be produced by an expansile lesion in a patient without unequivocal bone erosion. Similarly, asymmetry of the vidian-rotundum distance was never greater than 4.5 mm in the control group, but was greater than 4.6 mm in two of the seven patients with mucoceles. Again, while this finding may be specific, this is again of limited use as it was seen in only two of seven affected patients, and coexisted with other findings such as unequivocal expansion and erosion of the margin of vidian's canal.

One sign of expansile disease that appears more diagnostically useful is erosion or flattening of the rim of vidian's canal or the foramen rotundum. Erosion of the margin of vidian's canal was present in all seven of the patients, but was absent in all control subjects. This suggests that this finding is highly specific for an expansile lesion in this area. Erosion or flattening of the foramen rotundum was also noted in six of the seven patients and in no controls, and may also provide a useful indicator for expansile disease. The small sample size of affected patients, however, precludes statistically significant determination of the sensitivity of these findings.

Another useful observation in the control data is that apparent thinning of the sinus wall was seen in 24 of the normal subjects, typically at the groove for the internal carotid artery (Fig 2). This finding

can be ascribed to a combination of normal anatomic thinning, which has previously been noted in anatomic specimens in locations including the grooves for the internal carotid arteries, the optic nerve canals, and vidian's canal (8, 16, 17). It can also be ascribed to partial volume effects at sites in which the normal but thin sinus wall has an oblique course through the imaging plane. In contrast to controls, six of the seven patients with expansile lesions had either gross and unequivocal wall erosion or thinning of the walls of the sphenoid sinus at sites not explainable by partial volume artifact or normal anatomic variation. These findings included the floor of the sinus medial to vidian's canal (Fig 4). It is an interesting but inexplicable observation that the patients with bilateral expansile lesions represented the only three in this group who had wall thinning without unequivocal erosion.

### Conclusion

These results confirm that asymmetry in the lateral development of the paired sphenoid sinuses is normal. Without concurrent bone remodeling or erosion, an increased vidian-rotundum distance likely represents normal development. In addition, apparent wall thinning at the level of the carotid artery groove is a common finding in the normal population, and should not be interpreted as pathologic wall erosion. Enlargement of the vidian-rotundum distance greater than 11.4 mm should be a highly specific sign for an expansile lesion; however, this measurement was not useful in this patient population, in which the only affected patients with this finding presented other obvious signs of expansion. Finally, erosion or flattening of the margins of vidian's canal or the foramen rotundum appears to represent a highly specific sign of an expansile process, and should be sought when confronted with questionable expansion of a sphenoid sinus.

### References

1. Froehlich P, Remond J, Morgon A. **Imaging case study of the month mucocele of the sphenoid sinus in a child.** *Ann Otol Rhinol Laryngol* 1995;4:738-740
2. Nicolai P, de Zinis LOR, Tomenzoli D, Maroldi R, Antonelli AR. **Sphenoid mucocele with intracranial invasion secondary to nasopharyngeal acinic cell carcinoma.** *Head Neck* 1991;13:540-544
3. Minagi H, Margolis MT, Newton TH. **Tomography in the diagnosis of sphenoid sinus mucocele (SSM).** *AJR Am J Roentgenol* 1972;115(3):587-591
4. Roberson GH, Patterson AK, El Deeb M, Maisel RH, Bone RC. **Sphenoethmoidal mucocele: radiographic diagnosis.** *AJR Am J Roentgenol* 1976;127:595-599
5. Winestock DP, Bartlett PC, Sondheimer FK. **Benign nasal polyps causing bone destruction in the nasal cavity and paranasal sinuses.** *Laryngoscope* 1978;88:675-679
6. Dubois PJ, Schultz JC, Perrin RL, Dastur KJ. **Tomography in expansile lesions of the nasal and paranasal sinuses.** *Radiology* 1977;125:149-158
7. Reicher MA, Bentson JR, Halbach VV, Lufkin R, Hepler RS. **Pneumosinus dilatans of the sphenoid sinus.** *AJNR Am J Neuroradiol* 1986;7:865-868

8. Cope VZ. **The internal structure of the sphenoidal sinus.** *J Anatomy* 1917;51:127-136
9. Vidic B, Stom DR. **The postnatal development of the sphenoidal sinus and its spread into the dorsum sellae and posterior clinoid processes.** *AJR Am J Roentgenol* 1968;104:177-183
10. Fujoika M, Young LW. **The sphenoidal sinuses: radiographic pattern of normal development and abnormal findings in infants and children.** *Radiology* 1978;129:133-136
11. Krmptotic-Nemanic J, Vinter I, Hat J, Jalsovec D. **Variations of the ethmoid labyrinth and sphenoid sinus and CT imaging.** *Eur Arch Otorhinolaryngol* 1993;250:209-212
12. Szolar D, Preidler K, Ranner G, Braun H, Kugler C, Wolf G, Stammberger H, Ebner F. **The sphenoid sinus during childhood: establishment of normal developmental standards by MRI.** *Surg Radiol Anat* 1994;16:193-8
13. Hammer G, Radberg C. **The sphenoidal sinus.** *Acta Radiologica* 1961;56:401-422
14. Banna M, Olutola PS. **Patterns of pneumatization and septation of the sphenoidal sinus.** *J Can Assoc Radiol* 1983;34:-291
15. Elwany S, Yacout YM, Talaat M, El-Nahass M, Gunied A, Talaat M. **Surgical anatomy of the sphenoid sinus.** *J Laryngol Otol* 1983;97:227-241
16. Rothman SLG, Kier EL, Kirchner JA, Allen WE III. **Preoperative laminagraphic evaluation of the sphenoid sinus for trans-sphenoidal surgery.** *Laryngoscope* 1975;85:1986-1998
17. Renn WH, Rhoton AL. **Microsurgical anatomy of the sellar region.** *J Neurosurg* 1975;43:288-298