

Are your **MRI contrast agents** cost-effective?

Learn more about generic **Gadolinium-Based Contrast Agents**.



FRESENIUS
KABI

caring for life

AJNR

Selective Infusion of Urokinase and Thrombectomy in the Treatment of Acute Cerebral Sinus Thrombosis

Zina Novak, Douglas M. Coldwell and Kerry E. Brega

AJNR Am J Neuroradiol 2000, 21 (1) 143-145

<http://www.ajnr.org/content/21/1/143>

This information is current as of April 17, 2024.

Selective Infusion of Urokinase and Thrombectomy in the Treatment of Acute Cerebral Sinus Thrombosis

Zina Novak, Douglas M. Coldwell, and Kerry E. Brega

Summary: Acute cerebral sinus thrombosis caused a patient to decompensate rapidly and required immediate relief of her venous thrombosis as a life-saving procedure. The thrombus was laced with urokinase and removed from the sinuses with thrombectomy catheters. This reinstated flow and she recovered full neurologic function within 4 hours.

Cerebral sinus thrombosis has a mortality of 5% to 70%, depending on the acuity and extent of the thrombosis. The major causes of this condition include infection, pregnancy, oral contraceptives, dehydration, and cardiac disease, and it most commonly affects the superior sagittal sinus and left transverse sinus, but multiple sinuses are involved in over 70% of cases (1, 2). Although anticoagulation with heparin is usually successful if the therapy is instituted before the patient is moribund, cases with acute and rapid decompensation need aggressive therapy. We present a case of such a thrombosis that was treated successfully with thrombolytics and balloon thrombectomy.

Case Report

A 25-year-old woman, who was 2 months postpartum, had recommenced oral contraceptive use 1 month previously, and began having headaches 3 days prior to admission. The headaches, which started over the posterior cervical region and extended to the frontal area, steadily worsened. On the morning of admission, she had a generalized seizure and was brought to the emergency department where she was found to be somnolent but conscious when aroused. On admission, her Glasgow Coma Scale score was 11. Over the next 30 minutes, however, she became comatose and was intubated emergently before she was taken to the CT scanner. A second grand mal seizure occurred while the CT scan was being performed. The CT scan showed complete thrombosis of both transverse sinuses and the sagittal sinus with an "empty delta" sign. No evidence of cerebral infarction was present. Anticoagulants, heparin and aspirin, and anticonvulsants were administered immediately, and the patient was taken emergently to the interventional radiology suite where right femoral arterial and bilateral retrograde internal jugular venous punctures were

performed. Five-French (5F) Glidecaths (Medi-tech; Watertown, MA) were placed bilaterally through the 5F sheaths via the internal jugular vein and the transverse sinuses, then into the sagittal sinus (Fig 1A). The thrombus was laced with 1 million units of Urokinase (Abbott; Lake Bluff, IL) by placing the tip of the catheters distally in the clot and injecting urokinase through the catheters as they were withdrawn carefully. Complete lysis of the clot did not occur (Fig 2A). Attempts were made to aspirate the thrombus through the catheters but were unsuccessful. The Glidecaths were exchanged for 4F "over-the-wire" Fogarty catheters (Baxter, Minneapolis, MN), which were placed into both transverse sinuses. Care was taken to select a balloon that was smaller than the smallest diameter of the sinus, as measured on the CT scans—a 4-mm balloon within a 12-mm sinus. The balloon was filled with diluted contrast material to ensure opacification and, as the clot was removed, the deformation of the balloon was followed by fluoroscopy (Fig 2B). The catheter was pulled back gently so that the balloon was never distorted significantly, as the clot, which had been laced with urokinase, was removed. The Fogarty catheter was placed initially approximately midway through the transverse sinus, inflated, then gently withdrawn. The catheter was deflated, then gently readvanced until the torcula Herophili was reached. Three passes with the Fogarty catheter were sufficient to clear each transverse sinus clot. This deflated Fogarty catheter then was placed into the sagittal sinus, and serial advances and inflated withdrawals were made in a similar manner to clear the sagittal sinus as far rostrally as the coronal suture. Flow through the sinuses immediately returned. The patient's oxygen saturation was monitored continually and did not change when the thrombus was released into the venous circulation. The Fogarty catheters were removed, and a single angiographic catheter was left in place in the sagittal sinus where urokinase was infused at 125,000 units per hour for 4 hours. A follow-up venogram of the sagittal sinus was performed to check for its patency. Injection through the existing catheter showed both the transverse and sagittal sinuses to be essentially free of clots, with excellent blood flow (Fig 3A). The patient at this time was awake, and manifested only a minor deficit in gaze, with resultant double vision, after commands. The catheters and sheaths were removed from the patient's neck. The next day, a follow-up arteriogram revealed normal flow through the cerebral circulation, with normal venous washout (Fig 3B). She was discharged from the hospital after a stay of 6 days, and was placed on warfarin, aspirin, and dilantin. A neurologic examination at discharge showed diminishing double vision and minor headaches over the left temporal region. Follow-up clinic appointments over the next 3 months showed no further seizure activity or severe headaches, and an improving neurologic examination. At the present time, 9 months later, she has no neurologic deficits.

Discussion

Clinically, headaches, nausea, vomiting, seizures, hemiparesis, and papilledema are seen in most cases of acute cerebral sinus thrombosis (3). The anterior one third of the superior sagittal sinus,

Received April 7, 1999; accepted after revision July 14.

From the Department of Radiology (Z.N., D.M.C.) and Neurosurgery (K.E.B.), Denver Health Medical Center, Denver, CO.

Address reprint requests to Douglas M. Coldwell, PhD, MD, Director, Interventional Radiology, University of Maryland Medical System, 22 South Greene St., Baltimore, MD 21201.

© American Society of Neuroradiology

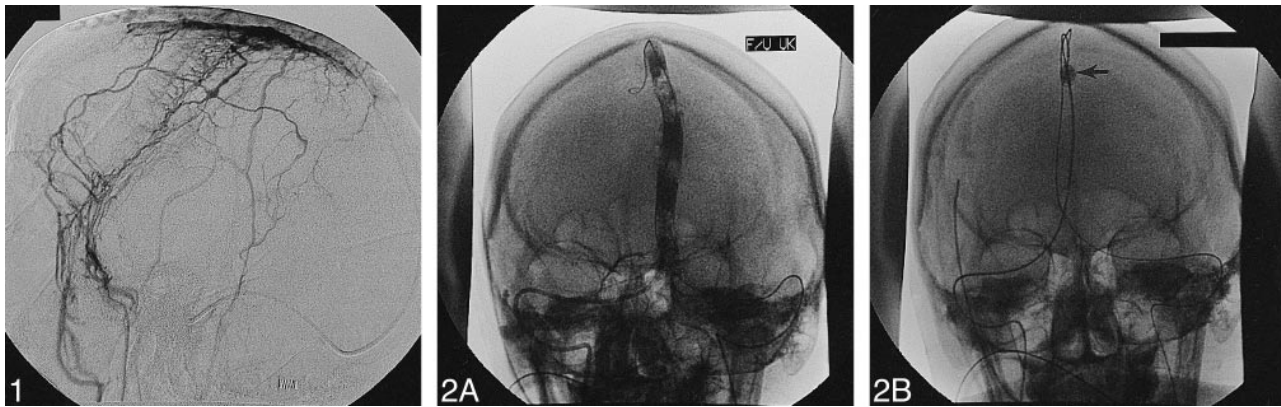


FIG 1. Lateral view of venogram of superior sagittal sinus shows lack of flow through superior sagittal sinus or within transverse sinuses. Catheter tip is in midsagittal sinus.

FIG 2. A, Town's view of injection of catheter in superior sagittal sinus shows extensive thrombus present after administration of initial urokinase lacing thrombus.

B, Over-the-wire Fogarty catheter is present in superior sagittal sinus (arrow).

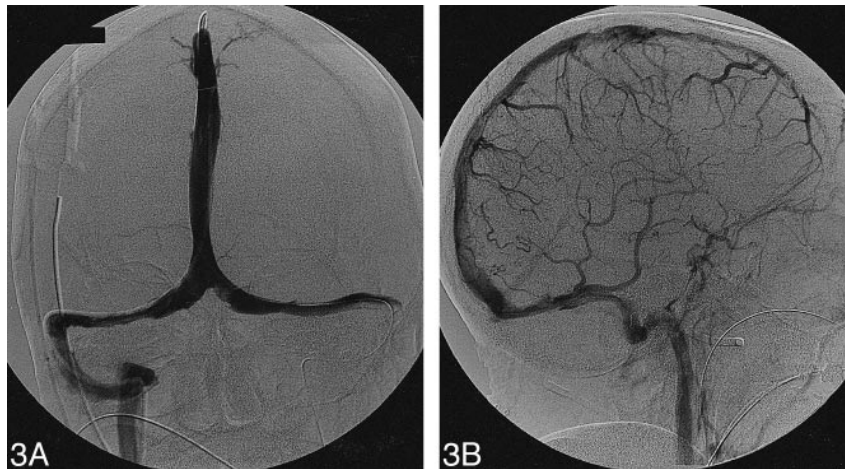


FIG 3. A, Injection of catheter within superior sagittal sinus demonstrates that, after clot removal from superior sagittal sinus and transverse sinuses, flow was resumed and little evidence of residual thrombus was present.

B, Lateral view of venous phase of follow-up in left common carotid arteriogram, 4 hours after the patient was started on urokinase infusion, demonstrates free flow of contrast through superior sagittal sinus.

anterior to the rostral vein, may occlude without sequelae; however, posterior to this point, the risk of venous cerebral infarcts increases. Occlusion of the mid-portion of the superior sagittal sinus results in increased muscle tone, with potential hemiparesis or decerebrate posturing. Patients with posterior sagittal sinus occlusion commonly will manifest visual field cuts, cortical blindness, or massive stroke. The overall mortality is approximately 30%, but ranges from 5% to 70% (3). Poor prognostic signs include coma, rapid neurologic deterioration, focal signs, and extreme symptoms of aging.

The diagnosis may be made on enhanced CT scans of the brain with the "empty delta sign" occurring at the torcula Herophili. This is the enhancement of the dura around the sinus (4). Such reduction of venous outflow from the brain causes white matter edema and hemorrhage; however, the

venous collaterals are highly variable and extensive, so the predictability of injury is uncertain.

In stable patients, who obviously have good collateral venous circulation, the usual treatment is heparinization to therapeutic levels. Over time, the thrombosis will lyse, and the patient will heal without sequelae. This situation occurs in most patients. In more unstable patients, however, much more aggressive therapy is warranted, because recovery of the brain is greater for venous occlusion than arterial occlusive disease (5). Catheter-directed IV administration of urokinase has been reported to be the treatment of choice for such sinus thrombosis (6, 7). These reports detail the use of direct infusion of the urokinase into the thrombus over several hours to days to lyse the thrombus. Such patients must be reasonably stable and not in an immediately life-threatening situation.

Owing to the patient's clinical situation, the recent onset of symptoms, and the young age of the

clot, the aggressive treatment of urokinase lacing of the clot and the use of the Fogarty catheter was indicated. Care was taken to prevent the probable fatal complication of puncture or rupture of the sinuses through the selection of a balloon size that was smaller than the diameter of the sinuses and to remove the clot by using only very gentle traction. The over-the-wire Fogarty balloon thrombectomy catheter was used because of its soft balloon, and the associated guidewire ensured that multiple passes could be made through the sinuses without having to renegotiate the sinuses, accelerating the procedure. Because of the shorter length of these catheters, it was necessary to make antegrade jugular punctures to place these catheters into the sinuses. A similar device, not designed for over-the-wire use, would not have been appropriate because the risk of perforation and the required time to place the catheter in the superior sagittal sinus would have been prohibitive. Bilateral sinus thrombectomies were performed to increase the flow of the sagittal sinus to reverse the patient's rapidly deteriorating condition as quickly as possible. Initially, both jugular veins were punctured, as it was not known which would be easier or more direct to remove the thrombus. The final venogram showed that the flow was preferentially through the right transverse sinus (Fig 3). When that was noted, the procedure was stopped, and no further efforts were made to reopen the left side.

A distinct risk of symptomatic pulmonary embolus accompanied removing this clot burden from the sinuses and releasing it into the systemic venous circulation was present. Nevertheless, we elected to proceed with thrombectomy owing to the rapid deterioration of the patient and, because the thrombus was laced with urokinase, we anticipated lysis in a relatively short time. Our opinion was that the amount of thrombus released during this case was qualitatively similar to that released to the venous circulation during dialysis graft thrombolysis/thrombectomy procedures. Because few symptomatic pulmonary emboli are noted in the latter procedures, we felt that the procedure described herein was safe to perform in this patient.

References

1. Symonds CP. **Otitic hydrocephalus.** *Brain* 1931;54:55-71
2. Shende MC, Lourie H. **Sagittal sinus thrombosis related to oral contraceptives.** *J Neurosurg* 1970;33:714-717
3. Estanol B, Rodriguez A, Conte G, et al. **Intracranial venous thrombosis in young women.** *Stroke* 1979;10:680-684
4. Virapongse C, Cazenave C, Quisling R, et al. **The empty delta sign: frequency and significance in 76 cases of dural sinus thrombosis.** *Radiology* 1987;162:779-785
5. Cipri S, Gangemi A, Campolo C, Cafarelli F, Gambardella G. **High-dose heparin plus warfarin administration in non-traumatic dural sinuses thrombosis. A clinical and neuroradiological study.** *J Neurosurg Sci* 1998;42:23-32
6. Horowitz M, Purdy P, Unwin H, et al. **Treatment of dural sinus thrombosis using selective catheterization and urokinase.** *Ann Neurol* 1995;38:58-67
7. Kuether TA, O'Neill O, Nesbit GM, Barnwell SL. **Endovascular treatment of traumatic dural thrombosis.** *Neurosurg* 1998;42:1163-1167