

Are your **MRI contrast agents** cost-effective?

Learn more about generic **Gadolinium-Based Contrast Agents**.



FRESENIUS
KABI

caring for life

AJNR

**Optimized Activation of the Primary
Sensorimotor Cortex for Clinical Functional MR
Imaging**

Karsten Papke, Peter Reimer, Bernhard Renger, Gerhard
Schuierer, Stefan Knecht, Matthias Schulz and Walter Heindel

This information is current as
of April 19, 2024.

AJNR Am J Neuroradiol 2000, 21 (2) 395-401
<http://www.ajnr.org/content/21/2/395>

Optimized Activation of the Primary Sensorimotor Cortex for Clinical Functional MR Imaging

Karsten Papke, Peter Reimer, Bernhard Renger, Gerhard Schuierer,
Stefan Knecht, Matthias Schulz, and
Walter Heindel

BACKGROUND AND PURPOSE: One application of functional MR imaging is to identify the primary sensorimotor cortex (M1 and S1) around the central sulcus before brain surgery. However, it has been shown that undesirable coactivation of nonprimary motor areas, such as the supplementary motor area and the premotor area, can interfere with the identification of the primary motor cortex, especially in patients with distorted anatomic landmarks. We therefore sought to design a simple functional MR imaging paradigm for selective activation of the primary sensorimotor cortex.

METHODS: Different paradigms using finger tapping for motor activation were examined and compared with respect to the distribution of activated voxels in primary and nonprimary cortical areas. Studies were conducted in 14 healthy volunteers using a blood oxygen level-dependent multislice echo-planar imaging sequence.

RESULTS: The most selective activation of the primary sensorimotor cortex was obtained with a paradigm combining right-sided finger tapping as the activation condition with left-sided finger tapping as the control condition. Analysis of the signal time course of primary and nonprimary areas revealed that the highly selective primary motor activation was due to it being restricted to contralateral finger movements, as opposed to the nonprimary motor areas, which were activated by ipsilateral, contralateral, and bilateral finger movements alike.

CONCLUSION: When performing functional MR imaging to determine the location of the primary sensorimotor cortex, one should compare unilateral voluntary movements as the activation condition with contralateral movements as the control condition to accentuate activation of the primary motor area and to suppress undesirable coactivation of nonprimary motor areas.

The basis of functional MR imaging is the so-called blood oxygen level-dependent (BOLD) technique, which is sensitive to local changes of blood flow and oxygen saturation in the microvasculature, mediated by the mechanism of neurovascular coupling (1–4). A statistical comparison of images obtained during an activated state (eg, limb motion) with images obtained during a control condition (eg, rest) can reveal activated cortical areas by showing

local signal changes in relation to the respective activation task (5, 6).

Previous studies of the technical feasibility of performing functional MR imaging with conventional clinical MR imaging systems at 1.5 T (7–9) and even at 1.0 T (10–12) have stimulated the clinical application of functional MR imaging. The technique has been used to identify eloquent cortical areas in order to preserve their function during resective surgery (13–16) or radiation therapy (17–19). In terms of the motor system, different anatomic landmarks have been used to identify the primary sensorimotor cortex on morphologic MR images (20, 21). However, anatomic localization may be difficult in patients with a distorted cortical anatomy; identification of eloquent cortical areas based on anatomic landmarks has been found unreliable in 35% of patients and in 16% of healthy subjects (22). Therefore, functional MR imaging is a valuable supplement to the anatomic procedures that have been described to identify the central sulcus and the adjacent primary sensorimotor cortex.

Received June 7, 1999; accepted after revision August 30.

From the Departments of Clinical Radiology (K.P., P.R., B.R., G.S., S.S., W.H.) and Neurology (S.K.), University of Münster, Germany.

Presented in part at the annual meeting of the European Society of Magnetic Resonance in Medicine and Biology, September 1998, Geneva, and at the European Congress of Radiology, March 1999, Vienna.

Address reprint requests to Dr. K. Papke, Department of Clinical Radiology, University of Münster, Albert-Schweitzer-Str. 33, D-48129 Münster, Germany.

Functional motor studies are often based on a comparison of some kind of limb (eg, hand, finger, or toe) movement as the activation condition versus rest as the control condition (4, 7–10). However, this approach not only yields activation of the primary sensorimotor areas but also of other cortical regions that are directly or indirectly linked to motor function (23, 24). Among the different nonprimary motor areas known from studies using functional MR imaging (23, 25) and positron emission tomography (24, 26, 27), the premotor area (PMA) and the supplementary motor area (SMA) have been shown to be located especially close to the primary sensorimotor cortex. Activation of these nonprimary areas may therefore severely interfere with a reliable identification of the primary sensorimotor cortex. To minimize any ambiguities, we attempted to optimize the functional MR imaging protocol for selective activation of the primary sensorimotor cortex. Our study was based on a comparison of activation maps obtained from different motor paradigms and on an analysis of functional MR imaging time courses from selected anatomic regions.

Methods

Subjects

Functional MR imaging studies were performed in 14 right-handed healthy volunteers (nine men and five women) 23 to 32 years old. Informed consent was obtained from all subjects after the nature of the procedure had been fully explained.

Imaging Procedure

All functional MR imaging studies were performed on a 1.5-T scanner. A BOLD-sensitive single-shot multislice echo-planar imaging technique was used with parameters of 3000/66 (TR/TE), a 210 × 210-mm field of view (FOV), and a 64 × 128 acquisition matrix. Ten axial sections were selected parallel to the skull base with the upper slice oriented tangentially to the brain convexity with a slice thickness of 3 mm and an interslice factor of 0.25. For anatomic correlation, a T1-weighted spin-echo sequence (350/15 [TR/TE]) with a 256 × 256 matrix and identical FOV and slice parameters was used.

The head was fixed tightly between two foam pads within the standard head coil to minimize head motion during the study. During the short examination time of 5 minutes, which included acquisition of anatomic images, this fixation was well tolerated by all subjects. To further minimize head motion, subjects were instructed to relax and keep their eyes closed during the scanning procedure, and, if necessary, to swallow between acquisitions, with as little head motion as possible. They were also instructed to move only their fingers during execution of the motor task, with their forearms resting comfortably on their thighs.

Activation Paradigms

Each stimulation run consisted of three epochs, comprising 10 acquisitions of the activation condition and 10 acquisitions of the control condition. Given a TR of 3000, this resulted in a total acquisition time of 3 minutes per run.

The motor task consisted of a sequential opposition of each finger to the thumb in a repetitive manner, as described in several previous studies (4, 7–10). The movement was self-paced following the instruction to move the fingers as fast as

comfortably possible without exerting extra force. For each subject, four different paradigms (activation condition versus control condition) were investigated: paradigm 1, right-sided finger tapping versus rest; paradigm 2, left-sided finger tapping versus rest; paradigm 3, simultaneous bilateral finger tapping versus rest; paradigm 4, right-sided versus left-sided finger tapping.

All four paradigms were examined in consecutive runs within a single session in a randomized order. The beginning and end of each period were announced via the microphone during an interval of silence between two acquisitions using the commands left, right, and stop.

Postprocessing

Postprocessing was performed off-line on a workstation using the software package Stimulate (28).

Period Cross Correlation.—Correlation coefficient maps were generated on the basis of the correlation of each voxel's time course with a reference function. This reference function was derived from a boxcar function reflecting the time course of the paradigm. To take into account the typical time characteristic of the BOLD response to activation (4, 5), the reference function had a temporal shift of 3 seconds (comparable to the time course of the paradigm) and a finite slope from rest to full activation (and back) of over 6 seconds.

Assessment of Motion Artifacts.—To detect bulk head motion, functional data sets were carefully reviewed in a cine mode. Head motion during the scan was further assessed by a center-of-mass analysis, which expresses the spatial image-to-image shifts in the *x*-, *y*-, and *z*-directions over time. An examination was excluded from further analysis if center-of-mass motion in excess of 0.5 voxel dimensions occurred.

Comparison of Different Paradigms.—To compare the activation results of the different experimental paradigms, the anatomic data sets were manually segmented by two neuro-radiologists in consensus. The central sulcus and the adjacent gyri were identified according to anatomic landmarks published previously (20, 21). Regions of interest (ROIs) were created for the pre- and postcentral gyrus and the central sulcus. Activation maps were then generated, highlighting all voxels with a map value above the 99th percentile of the correlation coefficient distribution. Activation maps were superimposed on the corresponding anatomic slices. For each ROI, the percentage of activated voxels within this ROI was determined and related to the total number of activated voxels in the examined brain volume.

Time Course Analysis.—Signal time courses from different anatomically defined regions were analyzed to directly compare the task-related signal changes in these regions. Additional ROIs for the SMA, the PMA, and the primary sensorimotor cortex along the central sulcus were generated by two neuro-radiologists in consensus and with the aid of both morphologic landmarks and functional maps. To avoid a bias by the activation map chosen, the ROIs were sized such that they included all voxels being activated by either paradigm in the respective anatomic region. Therefore, the map results of all four paradigms contributed equally to the ROI formation. Signal time courses derived from these ROIs were averaged across subjects.

Results

In two (14%) of the 14 healthy subjects, a confident identification of the central sulcus based on at least two independent anatomic landmarks in both hemispheres was not possible. These subjects were excluded from further analysis, although functional MR imaging clearly showed the location of the primary sensorimotor cortex in both subjects.

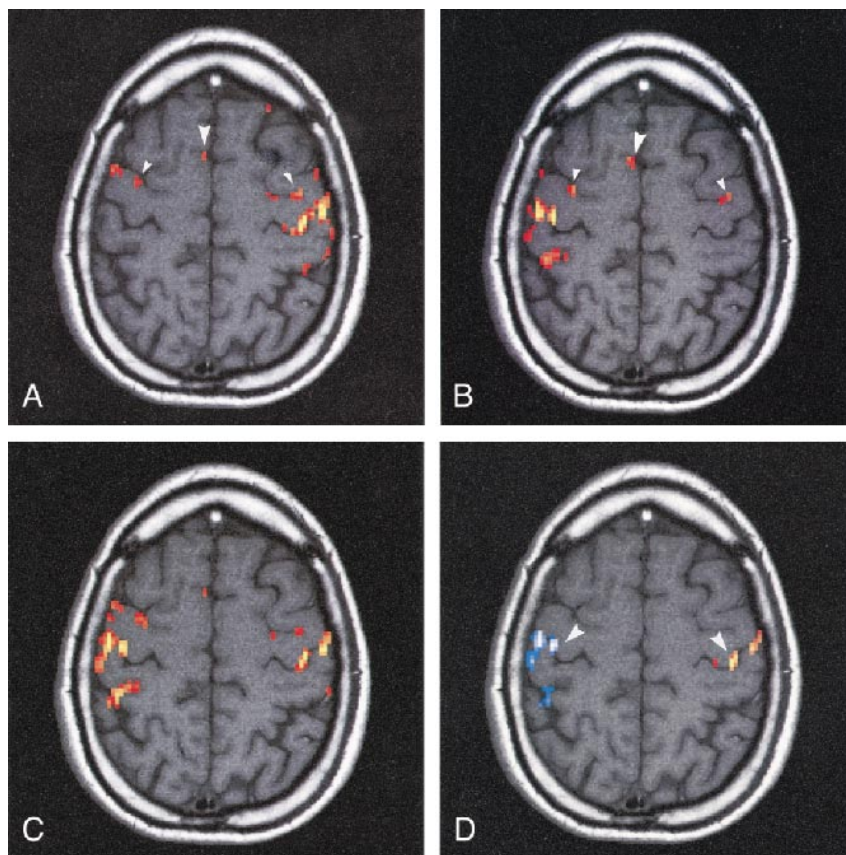


FIG 1. Correlation coefficient maps of a representative subject show the activation patterns elicited by the four different paradigms.

A and B, In paradigms 1 (A) and 2 (B), unilateral finger tapping is compared with rest (right hand versus rest and left hand versus rest, respectively). Maximal activation is located contralateral to the side of motion in the left (paradigm 1) and right (paradigm 2) hemisphere, respectively. However, ipsilateral activation is also in the PMA (*small arrowheads*) and SMA (*large arrowhead*) (the SMA is only marginally met in the selected slice).

C, In paradigm 3 (both hands versus rest), activity is distributed nearly symmetrically between the two hemispheres. Primary as well as nonprimary motor areas are activated, making the precise identification of the central sulcus difficult.

D, In paradigm 4, right-handed motion is compared with left-handed motion (*red* indicates positive correlation of the voxels' signal time course with the task-derived reference function; *blue*, negative correlation). Functional activity is focused on the primary sensorimotor cortex around the central sulcus near the motor knob (*arrowheads*), reflecting the primary motor hand area (20).

In the remaining 12 subjects, a total of five of 48 examination runs had to be excluded from further analysis because of head motion above the limit of 0.5 voxel dimensions.

Comparison of Activation Maps

In all 12 of the remaining subjects, activity-correlated signal changes were detectable in the cortex of the pre- and postcentral gyrus along the central sulcus, reflecting activation of the primary sensorimotor cortex (M1 and S1). In accordance with the somatotopy of the primary motor cortex known as the homunculus of Penfield and Boldrey (29), maximal functional activity was located over the convexity of the primary motor cortex, primarily in the hemisphere contralateral to the side of finger movement. However, in paradigms 1 and 2, in which unilateral movements were compared with rest, ipsilateral activation was also noted (Fig 1A and B). Averaged across subjects, the percentage of contralaterally versus ipsilaterally activated voxels was 86% versus 14% in paradigm 1 (right-hand movement versus rest) and 81% versus 19% in paradigm 2 (left-hand movement versus rest). In paradigm 3 (bilateral movement versus rest) and paradigm 4 (right-hand versus left-hand movement), activated voxels were nearly equally distributed between the two hemispheres (49% versus 51% and 43% versus 57%, respectively) (Figs 1C and D and 2).

In addition to the primary sensorimotor cortex, nonprimary cortical areas were also activated to an extent that depended on the paradigm chosen. Comparing the amount of extracentral activation among the different paradigms, paradigms 1 and 2 (unilateral movement versus rest) exhibited the highest percentage of activated voxels outside the central region. The hemisphere contralateral to the side of finger movement showed up to 25% of activated voxels in an extracentral location. Within the ipsilateral hemisphere, more voxels were activated outside than within the central region (Fig 2A and B). In paradigm 3 (bilateral movement versus rest), the amount of extracentral activation was lower (12%), but still higher than in paradigm 4 (right versus left), which yielded the lowest amount of extracentral activation, with an average of less than 5% activated voxels outside the central region.

A closer analysis of the activation pattern in paradigms 1 through 3 (in which rest was used as the control condition) revealed three major areas of activation besides the central sulcus region:

1) In all subjects, activation of the SMA was present, which usually appeared as a cluster of activated voxels above the cingulate sulcus anteriorly to the precentral sulcus. SMA activation usually extended symmetrically from the midline to the adjacent cortex of both hemispheres, irrespective of the side of finger movement. The consistent observation of SMA activation was in line with a pre-

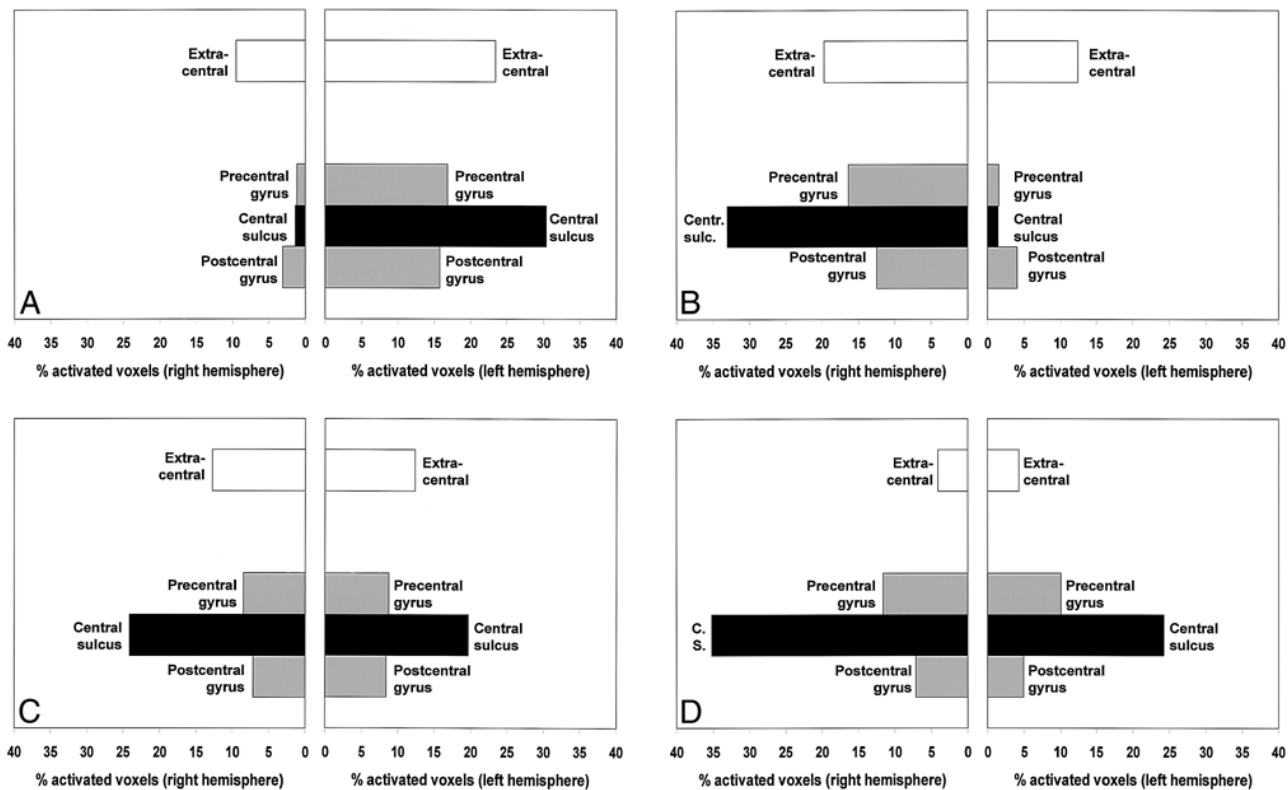


FIG 2. Distribution of activated voxels among the different areas of interest, expressed as a percentage in relation to the total number of activated voxels in the examined brain volume, averaged across subjects.

- A, Paradigm 1 (right hand versus rest).
 B, Paradigm 2 (left hand versus rest).
 C, Paradigm 3 (both hands versus rest).
 D, Paradigm 4 (right versus left hand).

Whereas in paradigms 1 through 3, 12% to 25% of activated voxels are located outside the central region, the amount of extracentral activation is lowest in paradigm 4 (<5%). In contrast, paradigm 4 yields the highest proportion of activated voxels in the primary sensorimotor cortex along the central sulcus, facilitating its reliable identification.

vious study in which it was reported that the SMA was not only involved in complex motor tasks but also in simple self-paced finger tapping (23).

2) In 10 subjects, dissociated clusters of activated voxels were found along the anterior and posterior bank of the precentral sulcus, lateral to its junction with the superior frontal sulcus, reflecting activation of the PMA.

3) In eight subjects, sparse activation was seen along the postcentral sulcus where it merges with the intraparietal sulcus, most likely reflecting non-primary somatosensory coactivation.

Ipsilateral activation in paradigms 1 and 2 (in which unilateral finger tapping was compared with rest) was mainly due to SMA and PMA activation. This observation is also illustrated in Figure 1A and B; activation in the hemisphere ipsilateral to the side of finger movement is only seen in the PMA and SMA, but not in the primary sensorimotor cortex along the central sulcus.

Further analysis of the distribution of activated voxels within the central region revealed that in paradigm 4 (right versus left hand), activated voxels were clustered along the central sulcus close to the so-called motor knob, a morphologic landmark that has been shown to correspond to the primary

motor hand area (20). In relation to the total number of activated voxels within the hemisphere, nearly 60% of voxels were aligned along the central sulcus, compared with only 35% to 40% in paradigms 1 and 2 (hemisphere contralateral to the side of finger tapping) and 40% to 45% in paradigm 3.

Comparison of Functional Time Courses

Findings were further analyzed by changes in signal time courses derived from primary and non-primary cortical motor areas. Signal time courses (averaged across subjects) of the left primary motor cortex along the central sulcus, PMA, and SMA are shown in Figure 3 in relation to motor activity. The primary sensorimotor cortex around the central sulcus exhibits a strong laterality of activation; functionally related signal changes are almost entirely restricted to the hemisphere contralateral to finger movement, reaching an average of 3% signal increase, whereas they are hardly detectable in the ipsilateral hemisphere (below 0.5%).

In contrast, the SMA is equally active during right-sided, left-sided, and bilateral finger movements (approximately 1.5% task-related signal change). As a result, no signal changes in the SMA

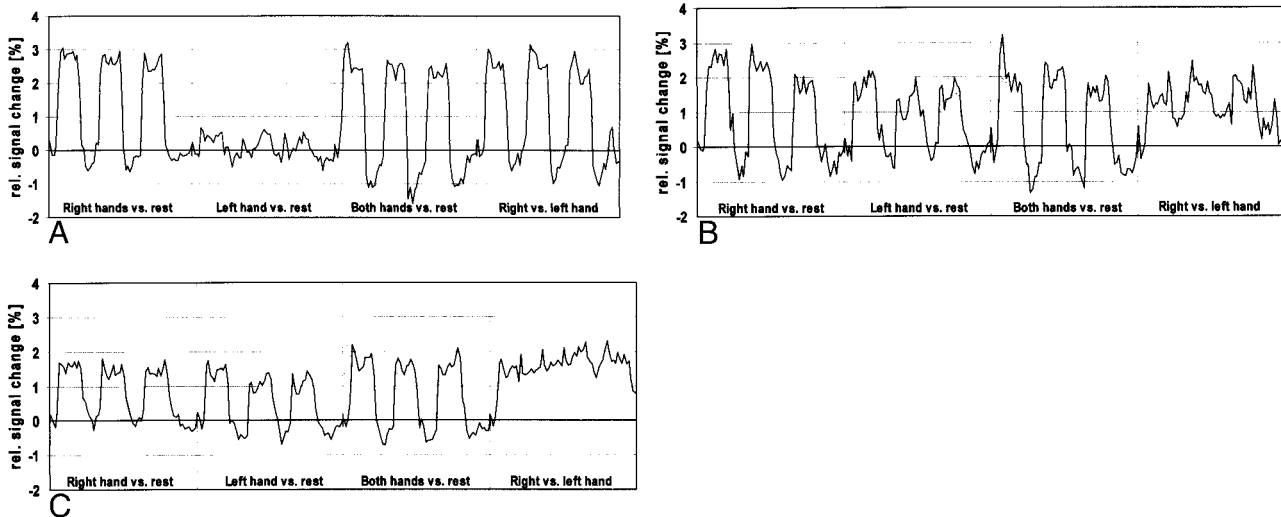


FIG 3. A–C, Signal time courses of the left primary sensorimotor cortex around the central sulcus (A), the PMA (B), and the SMA (C), averaged across subjects. Task-related signal changes along the central sulcus are highly specific to contralateral hand motion (A), whereas the nonprimary motor areas are activated by ipsilateral and contralateral hand motion alike. This holds particularly true for the SMA, in which there was no significant difference between the signal changes induced by unilateral or bilateral hand motion. As a result, no task-related signal changes can be observed in paradigm 4 (right versus left-handed finger tapping), apart from small signal peaks associated with changing the side of hand motion.

were observed during the comparison of right versus left finger tapping (paradigm 4), apart from a small signal peak induced by changing the side of hand motion. To a lesser degree, this also held true for PMA activation. When rest was used as the control condition, signal changes in the left PMA were only slightly more pronounced during contralateral finger tapping (2%) than during ipsilateral finger tapping (1.5%). As a result, functionally related signal changes in the left PMA were below 1% in paradigm 4, in which right versus left finger tapping was compared.

Discussion

Even in healthy subjects, functional MR imaging results do not always coincide with the anatomic prediction of the primary sensorimotor cortex; in one study, a mismatch between the results of functional and anatomic MR imaging was observed in two of 11 healthy volunteers (22). This is in good agreement with our findings, in which a precise anatomic identification of the central sulcus was not possible in two of 14 subjects.

In our experience, ambiguities in identifying the primary sensorimotor cortex in functional MR imaging derive, above all, from the coactivation of nonprimary motor areas. It was therefore the aim of our study to optimize a motor paradigm for maximum activation of the primary sensorimotor cortex. To ensure the full applicability of the examination protocol in a routine clinical setting, self-paced finger tapping was used for motor stimulation in a simple block paradigm (30 seconds of activation followed by 30 seconds of rest, repeated three times). This task is easy to perform, and no additional hardware installations are required.

The first two paradigms examined in our study (right finger tapping versus rest and left finger tapping versus rest) are comparable to the experimental setup of numerous previous studies in which the basic principle was to compare some kind of limb movement with a resting condition. As expected, the activation results of these paradigms were in good agreement with previous studies (4, 7–10, 23, 25). However, in comparisons of unilateral movement versus rest, activation of the SMA, the PMA, and other nonprimary motor areas close to the central region may interfere with the correct identification of the primary sensorimotor area, particularly in a brain with pathologically altered anatomic landmarks. Therefore, two additional paradigms were tested and their results compared with the first two paradigms.

In a third paradigm, simultaneous bilateral finger tapping was compared with rest. Activation results were nearly symmetric in this paradigm; that is, a similar number of activated voxels was found in the right and left hemispheres. This paradigm has the advantage of only one examination being necessary for the reliable detection of motor activation in both hemispheres. However, also in this paradigm, a high degree of nonprimary activation was found, especially in the SMA and PMA, bearing the risk of being misinterpreted as primary motor activation in patients with a distorted cortical anatomy.

To overcome this problem of nonprimary motor activation in paradigms in which rest is used as a control condition, we compared right finger tapping (activation condition) with left finger tapping (control condition) in paradigm 4. This paradigm led to a drastic reduction of extracentral activation, with an average of less than 5% of activated voxels lo-

cated extracentrally. Our results demonstrate that the comparison of homologous movements alternating between the right and left side in a single paradigm may solve the initial problem of a possibly misleading coactivation of nonprimary motor areas.

These findings need further explanation. Comparing left- and right-sided movements in a functional MR imaging paradigm reduces the difference between the two activation states (and hence the activation appearing in the functional correlation coefficient map) and the voxels that are selectively activated by either left- or right-sided motor function. It can be seen from the averaged time courses (Fig 3A) that this holds particularly true for the primary sensorimotor cortex around the central sulcus. In contrast, activation of the PMA and SMA is far less specific to the side of motion, which means that unilateral motor activity leads to both contralateral and ipsilateral activation of nonprimary motor areas. While both primary and nonprimary activation show up in a paradigm in which rest is the control condition, nonprimary activation escapes detection in the statistical comparison between left- and right-sided motion. Therefore, comparing right- and left-sided movements within a single paradigm highlights the side-specific activation of the primary sensorimotor cortex whose activation is nearly entirely restricted to contralateral finger tapping. In contrast, activation of areas involved in ipsilateral and contralateral motion alike (eg, SMA and PMA) is suppressed, because it does not produce a signal difference in the statistical comparison of right versus left hands. This assumption was also supported by comparing the activation maps obtained with the different paradigms; the nonprimary motor activation in the SMA and PMA in paradigms 1 and 2 (unilateral motion versus rest) tended to be symmetrically distributed between the left and right hemispheres, as opposed to the activation of primary motor areas (Fig 1A and B).

A further methodologic advantage of a paradigm comparing unilateral with contralateral finger tapping is that it overcomes the problem of using rest as the control condition. This is a critical issue, even in motor paradigms, for it is known that even the thought of motion is able to cause MR signal changes in primary cortical motor areas (30). Thus, the uncontrolled thought of motion during rest in the control condition may diminish the signal difference between activation and rest, and thus degrade the functional contrast-to-noise ratio.

Besides their relevance for clinical functional MR imaging, our observations contribute to the discussion on the anatomy of crossed and uncrossed corticospinal fibers in humans. The assumption of ipsilateral corticospinal projections serving motor function is supported in numerous publications reviewed by Wassermann et al (31). However, the precise origin and topography of these projections are still a matter of debate. In a

review of previous studies using direct electrical stimulation of the cortex in primates, Bucy and Fulton (32) described an area just anterior to the primary motor cortex that appeared to contain a motor representation of the ipsilateral limbs. This location would match well with the premotor activation we observed contralateral and ipsilateral to the side of finger movement.

The distribution of motor activation between the ipsilateral and contralateral hemispheres (14% activated voxels in the right hemisphere, 19% in the left hemisphere in ipsilateral finger tapping) is in good keeping with anatomic studies, in which it has been reported that, overall, 10% to 15% of the descending corticospinal fibers remain uncrossed in humans (33). Therefore, ipsilateral activation observed in our study might well reflect activity of neurons with uncrossed projections. Given the high percentage of activated voxels located extracentrally in the ipsilateral hemisphere (64% in the right hemisphere in right finger tapping, 60% in the left hemisphere in left finger tapping), our results suggest that neurons subserving ipsilateral motor function are located primarily outside the central region (eg, in the SMA and PMA). However, our technique does not permit us to discern whether these neurons possess direct corticospinal projections or whether they participate in ipsilateral motor function by transcallosal connections to the contralateral sensorimotor cortex. Concerning the location of ipsilateral cortical representations, Wassermann et al (31) drew other conclusions using noninvasive transcranial magnetic stimulation of the human cortex. These authors observed ipsilateral evoked motor responses in a hand muscle when applying the magnetic stimulus to the scalp site overlying the cortical representation of the contralateral facial muscles. They therefore hypothesized an ipsilateral cortical representation of the hand within the primary motor area subserving contralateral facial motor function (ie, lateral to the cortical area representing the homologous contralateral hand muscles).

Conclusion

When performing a functional MR imaging study to determine the location of the primary sensorimotor cortex, an examination protocol combining unilateral motion as the activation condition with contralateral motion as the control condition is recommended; rest should be avoided as a control condition. Use of this kind of paradigm accentuates the activation of eloquent cortical structures along the central sulcus and suppresses undesirable coactivation of nonprimary motor areas. The optimized functional contrast-to-noise ratio allows a robust demonstration of the primary sensorimotor cortex in both hemispheres within a scan time of 3 minutes; functionally related signal changes are sufficiently high to be detected by simple postprocessing algorithms (eg, correlation with a boxcar

reference function or z-score analysis) that can be easily implemented in the scanner software for clinical application without time-consuming off-line analysis. The execution of the task in a simple block type paradigm does not make high demands on the patient's ability to cooperate.

Our findings contribute to the discussion on the anatomy of uncrossed corticospinal fibers in humans and support the hypothesis that ipsilateral corticospinal projections originate mainly from nonprimary motor areas.

References

- Belliveau JW, Kennedy DN, McKinsty RC, et al. **Functional mapping of the human visual cortex by magnetic resonance imaging.** *Science* 1991;254:716-719
- Kwong KK, Belliveau JW, Chesler DA, et al. **Dynamic magnetic resonance imaging of human brain activity during primary sensory stimulation.** *Proc Natl Acad Sci USA* 1992;89:5675-5679
- Ogawa SD, Tank DW, Menon RS, et al. **Intrinsic signal changes accompanying sensory stimulation: functional brain mapping using MRI.** *Proc Natl Acad Sci USA* 1992;89: 5951-5955
- Turner R, Jezzard P, Wen H, et al. **Functional mapping of the human visual cortex at 4 and 1.5 T using deoxygenation contrast EPI.** *Magn Reson Med* 1993;29:277-279
- Bandettini PA, Wong EC, Hinks RS, Tikofsky RS, Hyde JS. **Time course EPI of human brain function during task activation.** *Magn Reson Med* 1992;25:390-397
- Bandettini PA, Jesmanowicz A, Wong EC, Hyde JS. **Processing strategies for time-course data sets in functional MRI of the human brain.** *Magn Reson Med* 1993;30:161-173
- Connelly A, Jackson GD, Frackowiak RSJ, Belliveau JW, Vargha-Khadem F, Gadian DG. **Functional mapping of activated human primary cortex with a clinical MR imaging system.** *Radiology* 1993;188:125-130
- Cao Y, Towle VL, Levin DN, Balter JM. **Functional mapping of human motor cortical activation with conventional MR Imaging at 1.5 T.** *J Magn Reson Imaging* 1993;3:869-875
- Schad LR, Trost U, Knopf MV, Müller E, Lorenz WJ. **Motor cortex stimulation measured by magnetic resonance imaging on a standard 1.5 T clinical scanner.** *Magn Reson Imaging* 1993; 4:461-464
- Santosh CG, Rimmington JE, Best JJ. **Functional magnetic resonance imaging at 1 T: motor cortex, supplementary motor area and visual cortex activation.** *Br J Radiol* 1995;68:369-374
- Lundervold A, Ersland L, Gjesdal KI, et al. **Functional magnetic resonance imaging of primary visual processing using a 1.0 Tesla scanner.** *Int J Neurosci* 1995;81:151-168
- Papke K, Hellmann T, Renger B, et al. **Clinical applications of functional MRI at 1.0 T: motor and language studies in healthy subjects and patients.** *Eur Radiol* 1999;9:211-220
- Jack CR, Thompson RM, Kim Butts R, et al. **Sensory motor cortex: correlation of presurgical mapping with functional MR imaging and invasive cortical mapping.** *Radiology* 1994;190: 85-92
- Yousry T, Schmid UD, Schmidt D, et al. **Cortical motor hand area: validation of functional magnetic resonance imaging by intraoperative cortical stimulation mapping.** *Radiologe* 1995; 35:252-255
- Atlas SW, Howard RS, Maldjian J, et al. **Functional magnetic resonance imaging of regional brain activity in patients with intracranial gliomas: findings and implications for clinical management.** *Neurosurgery* 1996;38:329-338
- Mueller WM, Yetkin FZ, Hammcke TA, et al. **Functional magnetic resonance imaging mapping the motor cortex in patients with cerebral tumors.** *Neurosurgery* 1996;39:515-521
- Pardo FS, Aronen HJ, Kennedy D, et al. **Functional cerebral imaging in the evaluation and radiotherapeutic treatment planning of patients with malignant glioma.** *Int J Radiat Oncol Biol Phys* 1994;30:663-669
- Schad LR, Bock M, Baudendistel K. **Improved target volume definition in radiosurgery of arteriovenous malformations by stereotactic correlation of MRA, MRI, blood bolus tagging, and functional MRI.** *Eur Radiol* 1996;6:38-45
- Hamilton RJ, Sweeney PJ, Pelizzari CA, et al. **Functional imaging in treatment planning of brain lesions.** *Int J Radiat Oncol Biol Phys* 1997;37:181-188
- Yousry TA, Schmid UD, Jassoy AG, et al. **Topography of the cortical motor hand area: prospective study with functional MR imaging and direct motor mapping.** *Radiology* 1995;195: 23-29
- Naidich TP, Valavanis AG, Kubik S. **Anatomic relationships along the low-middle convexity, 1: normal specimens and magnetic resonance imaging.** *Neurosurgery* 1995;36:517-532
- Yetkin FZ, Papke RA, Leighton PM, Daniels DL, Mueller WM, Haughton VM. **Location of the sensorimotor cortex: functional and conventional MR compared.** *AJNR Am J Neuroradiol* 1995; 16:2109-2113
- Boecker H, Kleinschmidt A, Requart M, Hänicke W, Merboldt KD, Frahm J. **Functional cooperativity of human cortical motor areas during self-paced simple finger movements: a high resolution MRI study.** *Brain* 1994;117:1231-1239
- Fink GR, Frackowiak RSJ, Pietrzyk U, Passingham RE. **Multiple nonprimary motor areas in the human cortex.** *J Neurophysiol* 1997;77:2156-2174
- Van Oostende S, van Hecke P, Sunaert S, Nuttin B, Marchal G. **fMRI studies of the supplementary motor area and the pre-motor cortex.** *Neuroimage* 1997;6:181-190
- Wessel K, Zeffiro T, Toro C, Hallet M. **Self-paced versus metronome-paced finger movements: a positron emission tomographic study.** *J Neuroimaging* 1997;7:145-151
- Remy P, Zilbovicius M, Leroy-Willig A, Syrota A, Samson Y. **Movement- and task-related activations of motor cortical areas: a positron emission tomographic study.** *Ann Neurol* 1994; 3:19-26
- Strupp JP. **Stimulate: a GUI based fMRI analysis software package.** *Neuroimage* 1996;3:S607
- Penfield W, Boldrey E. **Somatic motor and sensory representation in the cerebral cortex of man studied by electrical stimulation.** *Brain* 1938;15:389-443
- Porro CA, Francescato MP, Cettolo V, et al. **Primary motor and sensory cortex activation during motor performance and motor imagery: a functional magnetic resonance imaging study.** *J Neurosci* 1996;16:7688-7698
- Wassermann EM, Pascual-Leone A, Hallet M. **Cortical motor representation of the ipsilateral hand and arm.** *Exp Brain Res* 1994;100:121-132
- Bucy P, Fulton JF. **Ipsilateral representation in the premotor cortex of monkeys.** *Brain* 1933;56:318-342
- Nyberg-Hansen R, Rinvik E. **Some comments on the pyramidal tract, with special reference to its individual variations in man.** *Acta Neurol Scand* 1963;39:1-30