

Are your MRI contrast agents cost-effective?

Learn more about generic Gadolinium-Based Contrast Agents.



**FRESENIUS
KABI**

caring for life

AJNR

Treatment of an Aneurysmal Bone Cyst of the Spine by Radionuclide Ablation

Charles H. Bush and Walter E. Drane

AJNR Am J Neuroradiol 2000, 21 (3) 592-594

<http://www.ajnr.org/content/21/3/592>

This information is current as
of April 19, 2024.

Case Report

Treatment of an Aneurysmal Bone Cyst of the Spine by Radionuclide Ablation

Charles H. Bush and Walter E. Drane

Summary: We report the nonoperative treatment of a recurrent, multilevel spinal aneurysmal bone cyst by injection of ^{32}P chromic phosphate colloid into the cyst. The patient was then followed up with serial CT examinations, which showed stabilization and progressive ossification within the lesion. The rationale, alternatives, and possible contraindications to radionuclide ablation of spinal aneurysmal bone cysts are discussed.

An aneurysmal bone cyst, a blood-filled, endothelial-lined, fibrocystic lesion occurring mainly in patients younger than 20 years, often shows locally aggressive behavior. Aneurysmal bone cysts have an overall incidence of approximately 1% of primary bone tumors, with 15% of these lesions arising in the spine, where they have a predilection for the neural arch (1). Treatment of spinal aneurysmal bone cysts is controversial, with the main surgical options being curettage and wide resection. The surgical management of spinal aneurysmal bone cysts is frequently complicated by kyphoscoliosis and compression of the spinal cord and nerve roots. Deformity is frequently worsened by the heroic surgical procedures often needed for control of these lesions, which can involve more than one level. Therefore, management of spinal aneurysmal bone cysts has been attempted by intralesional injection of alcoholic zein, which is a biodegradable corn protein (2), or by multiple injections of calcitonin into the cyst (3). Particulate embolization (4), radiotherapy alone (5), and radiotherapy in concert with surgery (6, 7) have also been used to control this lesion. The radiosensitivity of aneurysmal bone cysts led us to speculate that its cellular lining might respond to radionuclide injection, akin to the successful use of radionuclides in treating hypertrophied synovium in patients with hemophilia and rheumatoid arthritis. We, however, were unable to find mention of such an attempt in the literature.

Case History

A 14-year-old girl originally presented to our institution with a destructive aneurysmal bone cyst of T12 with a pathologic fracture. Preoperative angiography and embolization of the lesion was followed by a lengthy, two-stage surgical procedure consisting of a posterior fusion, T12 corpectomy, and anterior fusion with a humeral allograft. A pathologic examination of the lesion showed no evidence of an underlying neoplasm stimulating the growth of the cyst. The patient went home after an uneventful postoperative course but again presented 1 year later with an extensive tumor recurrence. The lesion was then observed to involve adjacent portions of the bodies of T11 and L1 and had begun to erode the allograft (Fig 1A-B). Reoperation was thought to be too risky to merit consideration, and the patient and her mother gave informed consent to the option of radionuclide lesion ablation.

The lesion was localized by unenhanced CT sections obtained with the patient prone. Monitored conscious sedation was provided throughout this procedure. Local anesthesia was achieved with 1% lidocaine. Under CT guidance, an 18-gauge blunt needle was advanced into the lesion via a right paraspinous oblique approach. Fifty milliliters of sanguinous fluid was easily aspirated from the cyst. A 4F pigtail catheter with multiple side holes was advanced into the lesion over a guide-wire (Fig 1C), and 12 mL of nonionic iodinated contrast material was injected through the catheter into the cyst. After 1 hour, additional CT sections through the lesion confirmed free passage of the contrast material throughout the lesion (Fig 1D), with no evidence of paraspinal contrast extravasation or leakage into the thecal sac. Ten milliliters of fluid was then aspirated from the cyst through the catheter, and 2 mCi of ^{32}P chromic phosphate colloid was injected, with the radiopharmaceutical being flushed by 10 mL of normal saline. The catheter was then removed, and prompt hemostasis was obtained. The patient was observed in our holding area and was then discharged home.

The dosage to the wall of the cyst was estimated by extrapolating from a dosimetry nomogram used in a study of cystic grade IV astrocytomas treated with intralesional instillation of ^{32}P chromic phosphate colloid (8). We assumed that there was complete, homogeneous mixing of the radionuclide within the cyst. Using tumor dimensions from the preoperative MR examination, an approximate volume of 115 cm³ for the aneurysmal bone cyst was calculated, yielding a dose of 6300 rad for the wall of the lesion.

A follow-up MR examination performed 7 months after the procedure showed a decrease in the number of fluid-fluid levels in the lesion (Fig 1E). Subsequent serial CT examinations at 2- and 4-month intervals showed progressive ossification within the lesion, with reconstitution of an intact cortical margin and no increase in its size (Fig 1F). The patient experienced occasional episodes of thoracolumbar pain but remained entirely intact neurologically in her lower extremities and remained otherwise asymptomatic 22 months after the procedure.

Received July 21, 1999; accepted after revision October 21.

From the Department of Radiology, University of Florida College of Medicine, Gainesville, FL.

Address reprint requests to Charles H. Bush, MD, University of Florida College of Medicine, P.O. Box 100374, Gainesville, FL 32610-0374.

© American Society of Neuroradiology

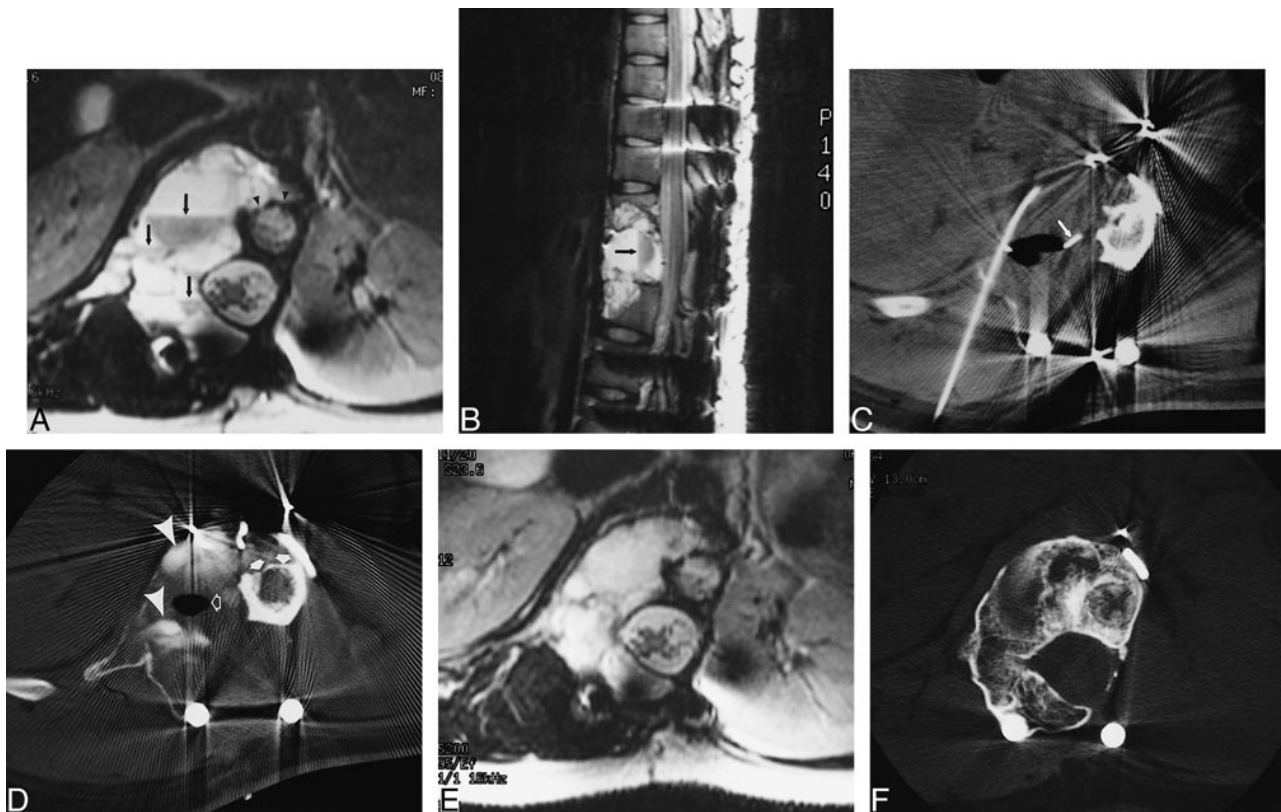


FIG 1. Images of a 15-year-old girl with a recurrent aneurysmal bone cyst involving T11–L1.

A, Axial T2-weighted MR image shows a large, expansile spinal lesion with multiple fluid-fluid levels (*arrows*), typical for an aneurysmal bone cyst. The dependent fluid layers in the cyst appear hypointense to the supernatant layers because of T2 shortening from intracellular deoxyhemoglobin in erythrocytes. This locally aggressive lesion has eroded the cortical allograft (*arrowheads*) placed during the T12 corpectomy for the original lesion. T1-weighted enhanced sequences obtained after the IV administration of gadolinium-based paramagnetic contrast material (not shown) showed no evidence of a solid component within this lesion.

B, Sagittal-view T2-weighted MR image, showing fluid-fluid level.

C, CT section obtained during the ablation shows a pigtail catheter in place within the lesion (*arrow*).

D, CT section obtained through the lesion at approximately the same level as that shown in *panel A* 1 hour after intralesional injection of iodinated contrast material shows opacification of its multiple cystic spaces (*arrowheads*), as well as an air bubble from the injection (*open arrow*). Note, again, the erosion of the cortical allograft (*solid arrows*).

E, Axial T2-weighted MR image obtained through the lesion 7 months after treatment shows replacement of the cystic spaces of the lesion with tissue of intermediate to high signal intensity.

F, CT section obtained through the lesion 22 months after radionuclide ablation shows ossification within the tumor, with incorporation of the cortical allograft.

Discussion

The radioisotopes used for radiosynovectomy decay by beta emission (9). The beta particle ablates the hypertrophic synovium of the affected joint but, unlike the much higher energy gamma radiation used in external beam irradiation, causes negligible dosage to periarticular structures. As the tendency of injected substances to diffuse out of a joint is inversely proportional to the size of its particles, the radiopharmaceuticals used in radiosynovectomy are colloids. Phosphorus-32 is desirable for radiosynovectomy because of its long half-life of 14 days, which results in a more gradual radiation dose to tissues. This isotope, a ^{32}P chromic phosphate, forms a large particle colloid in which extrasynovial diffusion is minimized. These properties also make ^{32}P chromic phosphate a reasonable choice for its use in ablation of the lining of an aneurysmal bone cyst while minimizing the radiation dose to surrounding tissues.

The large physical differences between an aneurysmal bone cyst and an inflamed joint raise many concerns about radionuclide ablation. The aneurysmal bone cyst has been likened to an arteriovenous malformation in bone, which may allow an injected radioisotope to egress the lesion rapidly via draining veins, potentially irradiating distant structures. We injected contrast material before injecting the radionuclide to verify filling of all of the cystic spaces of the aneurysmal bone cyst, and we planned to abort the ablation if the contrast material was cleared from the cyst during the time of observation. Aneurysmal bone cysts in their period of rapid growth often contain areas of fibroblastic proliferation, with spindle cells, osteoid, and osteoclast-like giant cells (1). The deeper regions of these solid regions of the tumor would likely prove refractory to the poorly penetrating beta particles of the radioisotope. Thus, only thinly septated lesions with a purely cystic character on cross-section

tional imaging would be expected to respond to radionuclide ablation. Last, by their very nature, other spinal tumors giving rise to secondary aneurysmal bone cysts, such as giant cell tumor and osteoblastoma, are not candidates for radionuclide ablation or any other nonsurgical treatment that affects only surfaces.

The technique of radionuclide ablation may have advantages over other nonsurgical treatments for spinal aneurysmal bone cysts. Catheter embolization is a time-consuming procedure in which ischemic insult to neural structures is an ever-present danger. In the case described by Koci et al (4), a large upper thoracic aneurysmal bone cyst that involved the epidural space required four embolization sessions for control of the lesion because of concern that tumor necrosis from too-rapid embolization would result in swelling and spinal cord compromise. Similar safety concerns apply to intralesional injection of calcitonin in that the multiple injections of the hormone are deemed necessary (3). In our case, although the tumor partly surrounded the spinal cord, the intact dura and CSF layer surrounding the cord provided an effective barrier to the beta particles of the radiopharmaceutical, which have an estimated mean range in soft tissue of only 2.8 mm (9). The late development of radiation-induced malignancies would logically be expected to be the main side effect from radiosynovectomy; one of the first proven radiation-induced malignancies was osteosarcoma caused by strontium-90, a beta-emitting radionuclide occurring in nuclear fallout. This complication does not seem to occur, based on experience with more than 5000 cases treated with ^{32}P chromic phosphate colloid that have been followed up since the early 1970s (10), possibly because of the lack of tissue deposition of the radiocolloid. In contrast, treatment of aneurysmal bone cyst by external beam radiotherapy is associated with occasional cases of myelopathy (4) and radiation-induced sarcomas (4, 6, 7). It should be noted that the lack of evident malignant transformation from radiosynovectomy might in part be attributed to the relative radioresistance of synovium rather than a greater

safety factor for beta-emitting radionuclides over gamma radiation. The typical patient with an aneurysmal bone cyst is younger than 20 years, and the appearance of radiation-induced malignancies can take several decades. Some beta-emitting radiopharmaceuticals used for radiosynovectomy have been shown to cause chromosomal changes in lymphocytes, presumably either because of joint leakage and uptake of the radionuclides by regional nodes or irradiation of the lymphocytes during circulation through the hypervascular synovium (11). Nevertheless, it is expected that additional candidate cases of spinal aneurysmal bone cyst for radionuclide ablation will present at our institution, considering that the spine is one location for this tumor where surgical intervention is not always practical or possible.

References

1. Mirra JM. **Cysts and cyst-like lesions of bone.** In: Mirra JM. *Bone Tumors: Clinical, Radiologic, and Pathologic Correlations.* Philadelphia: Lea & Febiger, 1989:1267-1311
2. Guibaud L, Herbreteau D, Dubois J, et al. **Aneurysmal bone cysts: percutaneous embolization with an alcoholic solution of zein.** *Radiology* 1998;208:369-373
3. Szendroi M, Antal I, Liszka G, Kónya A. **Calcitonin therapy of aneurysmal bone cysts.** *J Cancer Res Clin Oncol* 1992;119: 61-65
4. Koci TM, Mehringer CM, Yamagata N, Chiang F. **Aneurysmal bone cyst of the thoracic spine: evolution after particulate embolization.** *AJNR Am J Neuroradiol* 1995;16:857-860
5. Nobler MP, Higinbotham NL, Phillips RF. **The cure of aneurysmal bone cyst: irradiation superior to surgery in an analysis of 33 cases.** *Radiology* 1968;90:1185-1192
6. Vergel De Dios AM, Bond JR, Shives TC, McLeod RA, Unni KK. **Aneurysmal bone cyst: a clinicopathologic study of 238 cases.** *Cancer* 1992;69:2921-2931
7. Papagelopoulos PJ, Currier BL, Shaughnessy WJ, et al. **Aneurysmal bone cyst of the spine: management and outcome.** *Spine* 1998;23:621-628
8. Taasan V, Shapiro B, Taren JA, et al. **Phosphorus-32 therapy of cystic grade IV astrocytomas: technique and preliminary application.** *J Nucl Med* 1985;26:1335-1338
9. Siegel ME, Siegel HJ, Luck JV, Jr. **Radiosynovectomy's clinical applications and cost effectiveness: a review.** *Semin Nucl Med* 1997;27:264-371
10. Rivard GE, Girard M, Bélanger R, Jutras M, Guay JP, Marton D. **Synoviorthesis with colloidal P-32 chromic phosphate for the treatment of hemophilic arthropathy.** *J Bone Joint Surg Am* 1994;76:482-487
11. Winston MA, Bluestone R, Cracchiolo A, III, Bland WH. **Radioisotope synovectomy with ^{32}P chromic phosphate-kinetic studies.** *J Nucl Med* 1973;14:886-889