

Are your **MRI contrast agents** cost-effective?

Learn more about generic **Gadolinium-Based Contrast Agents**.



FRESENIUS
KABI

caring for life

AJNR

Orbital Doppler Sonography Findings in Cases of Brain Death

Kamil Karaali, Can Çevikol, Utku Senol, Gülbin Arici, Adnan Kabaalioglu, Atilla Ramazanoglu and Oguz Bircan

AJNR Am J Neuroradiol 2000, 21 (5) 945-947

<http://www.ajnr.org/content/21/5/945>

This information is current as of April 16, 2024.

Orbital Doppler Sonography Findings in Cases of Brain Death

Kamil Karaali, Can Çevikol, Utku Şnol, Gıbin Arıcı, Adnan Kabaalıoğlu, Atilla Ramazanoğlu, and Oğuz Bircan

Summary: In this study, we investigated the blood flow velocity changes in orbital arteries by using Doppler sonography in eight patients with brain death. Peak-systolic and end-diastolic velocities and resistive indices of the ophthalmic and central retinal arteries were evaluated. We observed the absence or reversal of end-diastolic blood flow in these arteries. To our knowledge, this finding has not been previously reported to be associated with brain death.

Brain death is defined as the “irreversible cessation of all functions of the entire brain, including the brain stem.” The diagnosis can usually be made based on a physical examination. Clinically, there is deep coma. Brain stem reflexes, such as pupillary light, corneal, oculocephalic, oculovestibular, oropharyngeal, and respiratory reflexes, are absent (1, 2). Confirmatory studies may be required if these reflexes cannot be assessed adequately. Conventionally, EEG has been used to confirm the diagnosis by showing electrocerebral silence (2). Other confirmatory methods are based on the evaluation of cerebral blood flow alterations. Doppler sonography is one of these methods that reveals blood flow velocity changes of the carotid arteries and internal cerebral circulation (3–5). Orbital Doppler sonography is a relatively new method. Normal and abnormal Doppler flow patterns of orbital vessels were first described in 1989 (6). Since then, many Doppler sonographic studies showing orbital blood flow changes in various disorders have been published.

In this study, we present the orbital Doppler sonographic findings of patients with brain death. We observed the absence or reversal of end-diastolic blood flow in the ophthalmic and central retinal arteries.

Description of the Technique

Between July 1998 and May 1999, all of the patients with a confirmed diagnosis of brain death in the intensive care unit at our institution were included in the study. Eight patients

were evaluated. Patient age and gender and causes of brain death are presented in Table 1. The diagnosis of brain death was based on clinical (deep coma status, absence of spontaneous breathing, and brain stem reflexes) and EEG (electrocerebral silence) findings.

Orbital Doppler sonographic examinations were performed with a Toshiba SSA-270A color Doppler sonographic unit and a 7.5-MHz linear probe. Sterile coupling gel was applied to closed eyelids, and all of the settings of the machine were adjusted to low-flow determination (low pulse-repetition frequency, high Doppler gain). Real-time gray-scale and color-flow images were obtained. The color Doppler images of the vessels were obtained in axial or oblique planes. Flow toward the transducer was selected as red. To obtain pulsed Doppler spectra, a sample volume of minimum size was placed on the color Doppler images of the arteries. In pulsed Doppler mode, in situ peak temporal average intensity was 60 mW/cm². Care was taken not to apply pressure on the globes with the probe. Central retinal arteries were found within the distal 5-mm part of the optic nerves. The ophthalmic artery was traced in the deeper parts of the orbita, lateral to the optic nerve, as it enters the orbit. For each artery, peak-systolic and end-diastolic velocities and resistive indices were recorded. Because of the patients' clinical status and the presence of several support and monitoring devices around the patients, it was technically difficult to place the probe and operate the Doppler machine simultaneously. For that reason, all Doppler examinations were performed by two operators. Doppler spectral analysis lasted approximately 1 minute for each eye. The total examination time was 5 to 10 minutes for each patient. During the Doppler examinations, systolic blood pressures of the patients were 80 mm Hg or higher. One patient (a 61-year-old male patient) was receiving a cardiopressor agent (IV administered dobutamine) in addition to the other drugs. All of the patients were receiving mechanical ventilation.

Results

Measurements of peak-systolic and end-diastolic velocities and resistive indices are presented in Table 2. Diastolic flow reversal (resistive index >1) was observed in 14 of 16 (87.5%) of ophthalmic arteries (Fig 1) and six of 16 (37.5%) central retinal arteries (Fig 2). In the remaining ophthalmic and central retinal arteries, end-diastolic velocities were 0 and resistive indices were 1 (Fig 3).

Discussion

The arrest of cerebral blood flow is a secondary but important phenomenon of brain death. The development of vascular obstruction in patients with brain death due to anoxic injury has been attributed to compression of the vascular lumen by cell swelling. This obstruction causes further ischemia and

Address reprint requests to Kamil Karaali, MD, Akdeniz Üniversitesi, Tıp Fakültesi, Radyoloji ABD, 07070 Antalya, Turkey.

TABLE 1: Ages, gender, and causes of brain death of patients

Patient No.	Age (y)/Sex	Cause of Brain Death
1	24/F	Cerebral hypoxia due to cardiac arrest
2	34/M	Head injury, intracranial hemorrhage
3	24/M	Head injury, intracranial hemorrhage
4	16/F	Acute myelogenous leukemia, intracranial hemorrhage
5	17/M	Head injury, intracranial hemorrhage
6	24/M	Intracranial mass, intracranial hemorrhage, hydrocephalus
7	61/M	Cerebral hypoxia due to cardiac arrest
8	69/F	Cerebral hypoxia due to cardiac arrest

increases the swelling of the brain cells, and intracranial pressure is heightened (7). If the underlying pathologic abnormality is a space-occupying lesion, such as a large intracranial hemorrhage, CSF, venous blood, and arterial blood may be compressed out of the skull cavity before the cell swelling occurs. In both conditions, elevated intracranial pressure decreases cerebral blood flow. If the intracranial pressure is higher than the end-diastolic pressure of the cerebral arteries, diastolic flow reversal occurs. If the intracranial pressure exceeds systolic pressure, blood flow is entirely ceased with complete and irreversible loss of brain function.

Among the techniques for evaluating cerebral blood flow, conventional angiography of the four cerebral arteries is the reference standard for imaging brain death (8). Nevertheless, angiography has some limitations, such as invasiveness (9). Radionuclide imaging, two-phase spiral CT, MR imaging, and MR angiography are noninvasive techniques that allow confirmation of brain death by showing decreased cerebral blood flow (7–10).

The need for transportation, unavailability, and technical difficulties in scanning patients with several support and monitoring devices are the limitations of all of these imaging methods.

Flow patterns of carotid arteries and intracerebral arterial circulation in cases of brain death have been documented by Doppler studies. End-diastolic blood flow velocity of the common carotid arteries was found to have a sensitivity and specificity of 100% for brain death diagnosis (3). Transcranial Doppler studies have shown that the absence or reversal of diastolic flows and the marked increase in resistive indices in intracranial arteries are highly specific and sensitive (4, 5).

The ophthalmic artery is the first intracranial branch of the internal carotid artery. It enters the orbit through the optic canal as the main artery. Most of its branches, including the central retinal artery, arise within the posterior third of the orbit. The central retinal artery enters the optic nerve distal to the optic canal and ends in the retina (6). Because the ophthalmic artery is the first intracranial branch of the internal carotid artery, it may reflect intracranial blood flow alterations. In our study, we observed the reversal or absence of diastolic flow in ophthalmic arteries and central retinal arteries. We think that these findings are the result of cerebral blood flow alterations reflected through the ophthalmic arteries and that this artery may be used as an acoustic window for internal cerebral blood flow evaluation.

Because of technical difficulty, this technique does not seem to be practical for routine application. Nonetheless, it may be used as an alternative noninvasive method when Doppler studies of the carotid arteries are not adequately performed because of limiting conditions, such as open wounds,

TABLE 2: Peak-systolic and end-diastolic velocities, and resistive indices of the arteries

Patient No.	Eye	Ophthalmic Artery			Central Retinal Artery		
		PSV	EDV	RI	PSV	EDV	RI
1	R	7	-3	1.43	4	0	1
	L	9	-5	1.8	6	-3	1.5
2	R	10	-3	1.3	3	0	1
	L	15	-5	1.33	11	-2	1.18
3	R	39	-6	1.15	5	-2	1.4
	L	18	-2	1.11	4	0	1
4	R	5	-4	1.8	6	0	1
	L	4	-5	2.25	6	-2	1.33
5	R	23	-5	1.21	11	-2	1.18
	L	18	0	1	9	0	1
6	R	19	-5	1.26	4	0	1
	L	21	-4	1.19	5	0	1
7	R	16	0	1	10	0	1
	L	18	-4	1.22	9	-3	1.33
8	R	17	-3	1.18	5	0	1
	L	12	-4	1.33	6	0	1

Note.—PSV, peak-systolic velocity (cm/s); EDV, end-diastolic velocity (cm/s); RI, resistive index; R, right; L, left.

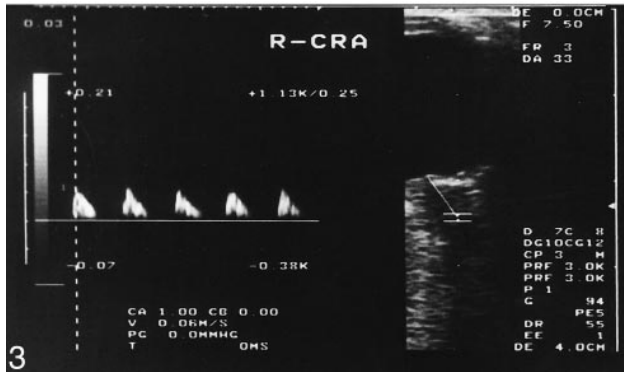
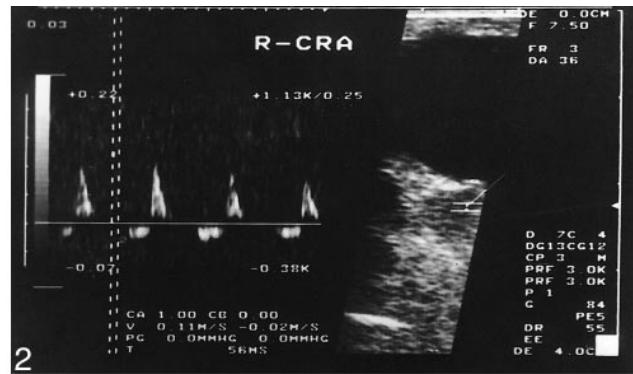
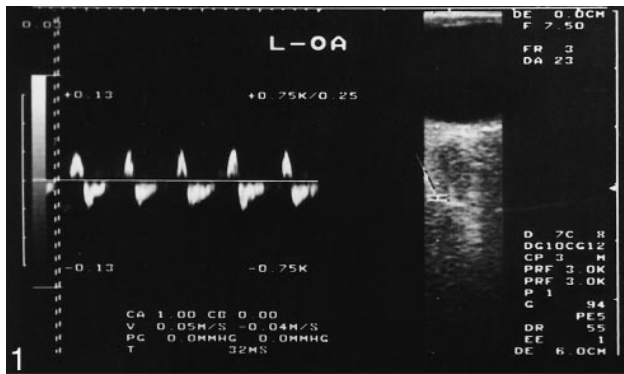


FIG 1. Doppler spectrum of the left ophthalmic artery shows end-diastolic flow reversal. Resistive index is 1.80.

FIG 2. Doppler spectrum of the right central retinal artery shows end-diastolic flow reversal. Resistive index is 1.18.

FIG 3. Doppler spectrum of the right central retinal artery shows absence of end-diastolic flow. Resistive index is 1.

the presence of vascular catheters, or large cervical hematomas.

References

1. President's Commission for the Study of Ethical Problems in Medicine and Biomedical and Behavioral Research. *Defining Death: A Report on the Medical, Legal and Ethical Issues in the Determination of Death*. Washington: US Government Printing Office; 1981
2. Guidelines for the determination of death: Report of the medical consultants on the diagnosis of death to the President's Commission for the Study of Ethical Problems in Medicine and Biomedical and Behavioral Research. *JAMA* 1981;246:2184-2186
3. Payen DM, Lamer C, Pilorget A, Moreau T, Beloucif S, Echter E. Evaluation of pulsed Doppler common carotid blood flow as a noninvasive method for brain death diagnosis: a prospective study. *Anesthesiology* 1990;72:222-229
4. Glasier CM, Seibert JJ, Chaddock WM, Williamson SL, Leithiser RE. Brain death in infants: evaluation with Doppler US. *Radiology* 1989;172:377-380
5. Petty GW, Mohr JP, Pedley TA, et al. The role of transcranial Doppler in confirming brain death: sensitivity, specificity and suggestions for performance and interpretation. *Neurology* 1990;40:300-303
6. Erickson SJ, Hendrix LE, Massaro BM, et al. Color Doppler flow imaging of the normal and abnormal orbit. *Radiology* 1989;173:511-516
7. Wilson K, Gordon L, Selby JB. The diagnosis of brain death with Tc-99m HMPAO. *Clin Nucl Med* 1993;18:428-434
8. Dupas B, Gayet-Delacroix M, Villers D, Antonioli D, Veccherini MF, Soullou JP. Diagnosis of brain death using two-phase spiral CT. *AJNR Am J Neuroradiol* 1998;19:641-647
9. Patel YP, Gupta SM, Batson R, Herrera NE. Brain death: confirmation by radionuclide cerebral angiography. *Clin Nucl Med* 1988;13:438-442
10. Ishii K, Onuma T, Kinoshita T, Shiina G, Kameyama M, Shimosegawa Y. Brain death: MR and MR angiography. *AJNR Am J Neuroradiol* 1996;17:731-735