

Are your MRI contrast agents cost-effective?
Learn more about generic Gadolinium-Based Contrast Agents.



AJNR

Reply

Colin P. Derdeyn, Robert L. Grubb Jr. and William J. Powers

AJNR Am J Neuroradiol 2001, 22 (1) 227-0227
<http://www.ajnr.org/content/22/1/227>

This information is current as
of April 19, 2024.

Dilation of Cervical Epidural Veins in Intracranial Hypotension

We read with interest the case report of Clarot et al (1) regarding a patient with intracranial hypotension (IH) after lumbar puncture who had giant cervical epidural veins as the sole MR finding. Having had experience with a similar case, we felt obliged to report on our observation and contribute to the validation of this finding, with the aim of rendering a difficult diagnosis easier.

A 34-year-old previously healthy woman presented in May 1996 with headache and neck pain. Spinal MR showed dilation of cervical epidural veins, especially visible from the C2 down to the C4 level anteriorly. On subsequent angiography, no vascular malformation was identified; venous drainage and jugular veins were normal, but epidural veins appeared markedly dilated at the upper cervical and spinal-medullary level (Fig 1). Further observation of the spinal MR study made it possible to identify meningeal ectasia at the level of the exiting spinal roots at C7–T1 (Fig 2). At the same level, increased signal was noticed on T2-weighted images in the paraspinal soft tissues, which was interpreted as cerebrospinal fluid. On this basis, spontaneous IH caused by CSF leakage was suspected. Brain MR showed thickened dura, but the patient refused a contrast-enhanced examination. Nevertheless, accurate measurement of brain position in the skull on midsagittal T1-weighted images gave results suggesting a significant rostrocaudal brain displacement (Fig 3). Cerebellar tonsils were 2 mm below the Chamberlain line, and the apex of the fourth ventricle was 3 mm below the Twining line. The symptoms and the MR images resolved after conservative therapy (ie, bed rest and hydration). On clinical follow-up 41 months later, the patient denied any relapse of symptoms.

In addition to confirming dilation of cervical epidural veins as a possible presentation of IH, we would like to draw attention to precise measurement of brain position in the skull on midsagittal MR images as an aid to the diagnosis of IH (2).

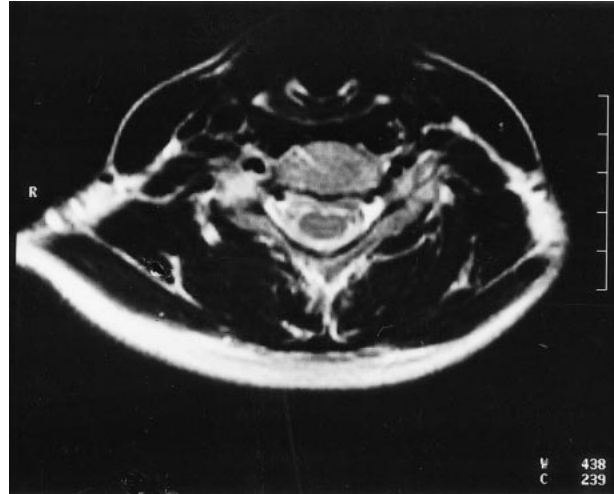


FIG 2. Axial T2-weighted turbo spin-echo sequence (3900/120) at C7–T1 level showing increased signal in the paraspinal soft tissues close to the right exiting root. This finding was interpreted as cerebrospinal fluid leakage.

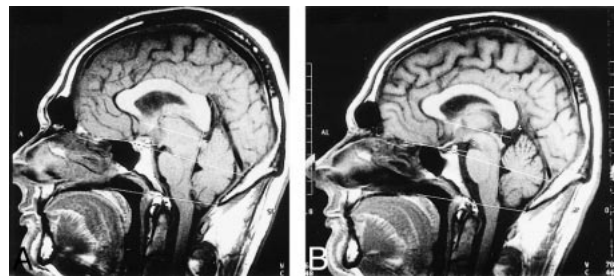


FIG 3. Anatomic landmarks for measurement of vertical brain displacement on sagittal T1-weighted MR images (1, cerebellar tonsils; 2, fourth ventricle; 3, infundibular recess; 4/5, angle.

A, Symptomatic patient.
B, Same patient after a normal follow-up examination.

We recently measured brain position relative to four anatomic landmarks in a series of eight patients affected by the syndrome of spontaneous IH, and in 89 healthy control subjects. We found that

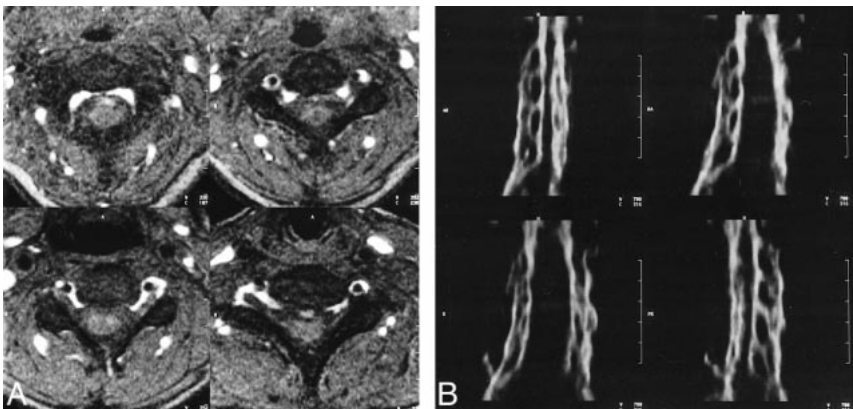


FIG 1. A, MR angiogram obtained with an axial fast low-angle shot 2D sequence (40/9.8 [TR/TE]; flip angle, 35°). Cervical epidural veins are markedly dilated and give very high signal. Carotid and vertebral arteries give dark signal because of inferior saturation.

B, Oblique sagittal and coronal reconstructed images obtained with maximum intensity projection.

the two groups differed for all four measurements: 1) the position of the cerebellar tonsils measured relative to the Chamberlain line (a straight line drawn from the posterior lip of the bony hard palate posteriorly to the posterior lip of the foramen magnum), 2) the position of the apex of the fourth ventricle measured relative to the Twining line (a straight line drawn from the anterior tuberculum sellae posteriorly to the internal occipital protuberance), 3) the position of the third ventricle infundibular recess relative to the straight line drawn tangent to the floor of the anterior cranial fossa, and 4) the position of the third ventricle measured as the value of the superior-posterior angle between the bicommissural line (a straight line drawn from the anterior to the posterior commissure) and the straight line drawn tangent to the floor of the fourth ventricle. The difference was significant ($P < .001$) for three of the four measurements (1, 2, and 3).

To conclude, dural contrast enhancement (4) and other MR findings can be absent in some cases of IH, and we emphasise the possibility of confirming clinical suspicion by precise evaluation of the above-mentioned features.

Anna Messori, M.D.
Gabriele Polonara, M.D.
Ugo Salvolini, M.D.
University of Ancona
Ancona, Italy

References

1. Clarot F, Callonnet F, Douvrin F, et al. **Giant cervical epidural veins after lumbar puncture in a case of intracranial hypotension.** *AJNR Am J Neuroradiol* 2000;21:787-789
2. Pannullo SC, Reich JB, Krol G, Deck MDF, Posner JB. **MRI changes in intracranial hypotension.** *Neurology* 1993;43:910-926
3. Messori A, Regnicolo L, Simonetti BF, Di Bella P, Logullo F, Salvolini U. **Spontaneous intracranial hypotension syndrome: the value of brain measurements in MRI diagnosis** (in press)
4. Mokri B, Atkinson JLD, Dodick DW, Miller GM, Piepgras DG. **Absent pachimeningeal gadolinium enhancement on cranial MR despite symptomatic CSF leak.** *Neurology* 1999;53:402-404

Pain Prevention for Interventional Radiologists

I read with interest Dr. Pelz's letter in a recent issue of the *AJNR* (1) regarding the prevention of neck and low back pain in interventional radiologists. The physical stresses Dr. Pelz alludes to are very real. I have been able to participate in many sports with negligible low back and neck pain, but have nearly always been symptomatic with back pain and radiculopathy when performing interventional procedures with a lead apron on. I now limit myself to short procedures because of this problem.

I want to call attention to another simple, yet effective, method of decreasing the stress on the low back when performing procedures with a lead apron on. Placing one foot on a short, comfortably

elevated stool under the fluoroscopy table puts the low back in a more comfortable straight posture, and relieves stresses on the intervertebral disks and paraspinal soft tissues. For many years I was able to maintain a moderately busy interventional schedule that would have been impossible without my stool. Dr. Pelz's "Hang 'em High" solution seems to be better and more definitive, but I want to share my simple, cheap solution.

John F. Healy, M.D.
University of California and
VA San Diego Healthcare System
San Diego, CA

Reference

1. Pelz, DM. **Low back pain, lead aprons, and the angiographer.** *AJNR Am J Neuroradiol* 2000;21:1364

Absence of Selective Deep White Matter Ischemia in Chronic Carotid Disease

In a recent article in the *AJNR*, Derdeyn et al (1) concluded that "normal deep white matter among patients with carotid occlusion is not subject to a greater degree of ischemia than is the overlying cortex." This conclusion may be appropriate for the population studied and the measurements made; however, it should be qualified because of patient selection bias. The conclusion is not applicable to the larger clinical population, and it does not settle the question at hand.

The study is subject to selection bias because 19 of 55 patients who had raised superficial (cortical) oxygen extraction fraction ratios (compared to the contralateral hemisphere) were excluded because "all three deep white matter regions were abnormal, as revealed by CT or MR imaging." These patients may have been the ones that should have been examined to show the changes that were

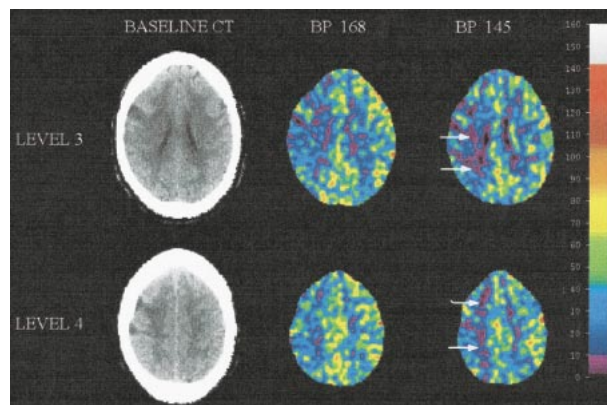


FIG 1. Cerebral blood flow decreased throughout the right middle cerebral artery territory and selectively within the deep white matter during systolic blood pressure reduction from 168 to 145 mm Hg. The lavender color indicates increase of area with flow levels at or below 8 mL/100 g/min (arrows).

sought. Furthermore, CT and MR imaging “changes” do not necessarily indicate infarction and, by eliminating these patients and studying only patients with “normal” white matter, the authors biased their study.

The authors further biased the study by selecting only patients with unilateral occlusion (for a ratio-based approach for calculating the oxygen extraction fraction). Seventeen of the 36 patients had never had a neurologic event or were 5 months past their last event. Because patients with bilateral occlusion were excluded, the patients studied were less likely to have severe or prolonged hemodynamic compromise. Widder et al (2) showed that cerebrovascular hemodynamics improves by 5 months after the onset of symptoms in unilateral carotid disease, but remains impaired in bilateral carotid disease. Thus, nearly half of the patients may have overcome the disorder by the time of this study.

Further selection bias is evident because few individuals in the study presented with ischemic claudication (Dr. William Powers, personal communication). These coarse, rhythmic, shaking movements, often induced in a patient with carotid occlusion who assumes an erect posture, are associated with the appearance of unilateral deep white matter changes. Firlik et al observed a patient with this syndrome and white matter changes who had near-zero perfusion selectively within the deep white matter with a vasodilator challenge by acetazolamide (3). A similar response was observed within the deep white matter of 13 patients who had recurrent hemispheric symptoms despite maximal medical therapy, and who subsequently developed deep white matter infarctions in the lowest flow regions. A hemodynamic mechanism for this disorder was indicated by the fact that all of these patients stabilized clinically and had positive cerebrovascular reserve after superficial temporal artery-middle cerebral artery bypass surgery (4).

Patients with ischemic claudication and ipsilateral deep white matter ischemic changes presumably suffered infarctions because of modest alterations in cerebral perfusion pressure, as may occur when assuming an erect posture. Perhaps a simple way to answer the question raised by Derdeyn et al would be to measure the cerebral blood flow (CBF) response to a transient, moderate lowering of arterial blood pressure. In a recently treated patient who had carotid occlusion, we observed that blood pressure elevation resulted in cessation of recurrent neurologic events. A blood pressure-lowering, xenon/CT, CBF study was performed 5 days later to determine whether hypertensive therapy was still needed (Fig 1, page 225). A dramatic decrease of CBF values to near zero was recorded selectively within the deep white matter, in and near the site of white matter infarction.

In conclusion, we believe that a significant number of individuals who come to clinical attention because of recurrent ischemic events ipsilateral to

a carotid occlusion, despite anticoagulation, suffer from a hemodynamic disorder. The predilection of these individuals for deep white matter infarctions within regions of maximal hemodynamic challenge (evidenced by the development of ischemia in response to a hemodynamic challenge) is a real phenomenon that warrants further study.

Howard Yonas, M.D.
Ronda R. Pindzola, Ph.D.
Charles Jungreis, M.D.
Edwin M. Nemoto, M.D.
*University of Pittsburgh
Pittsburgh, PA*

References

1. Derdeyn CP, Simmons NR, Videen TO, et al. **Absence of selective deep white matter ischemia in chronic carotid disease: a positron emission tomographic study of regional oxygen extraction.** *AJNR Am J Neuroradiol* 2000;21:631-638
2. Widder B, Kleiser B, Krapf H. **Course of cerebrovascular reactivity in patients with carotid artery occlusions.** *Stroke* 1994;25:1963-1967
3. Firlik AD, Firlik KS, Yonas H. **Physiological diagnosis and surgical treatment of recurrent limb shaking: case report.** *Neurosurgery* 1996;39:607-611
4. Przybylski GJ, Yonas H, Smith HA. **Reduced stroke risk in patients with compromised cerebral blood flow reactivity treated with superficial temporal artery to distal middle cerebral artery bypass surgery.** *J Stroke Cerebrovasc Dis* 1998;7:302-309

Reply

Is the deep white matter of adults more vulnerable to greater ischemia than the overlying cortex because of hemodynamic factors? Is the concept of an internal arterial borderzone valid? These important questions remain unanswered. We recently reported that structurally normal (on CT or T2-weighted MR images) white matter regions in patients with chronic carotid occlusive disease were not subject to a greater amount of ischemia than the overlying cortex (1). Yonas et al contend that this conclusion is valid for only a small group of patients, because of selection bias. In addition, they provide an anecdotal example of a patient with reduced white matter blood flow after blood pressure reduction to support their argument that the white matter is vulnerable to ischemia from hemodynamic mechanisms.

The patients included in our study were, in fact, quite representative of patients with carotid occlusion. These patients were enrolled in the St. Louis Carotid Occlusion Study, a longitudinal study of hemodynamic factors and stroke risk (2). Baseline epidemiologic and stroke risk factors for the 117 patients enrolled in this study were very similar to those reported from other studies of stroke risk,

such as the North American Symptomatic Carotid Endarterectomy Trial (3). Patients with atherosclerotic carotid occlusion were invited to participate, regardless of whether the occlusion was bilateral or whether ischemic ocular or cerebral events had occurred.

We limited our analysis of white matter hemodynamics to structurally normal white matter. Consequently, we excluded patients for whom no imaging studies were available for review, as well as those having regions of interest located in structurally abnormal tissue. Whereas it is true that white matter hypodensity on CT or T2 hyperintensity on MR images does not always indicate tissue infarction, it often does. Damaged tissue may have impaired autoregulation in the absence of reduced perfusion pressure. Consequently, it is not valid, as Yonas et al suggest, to analyze such white matter regions and draw firm conclusions regarding the hemodynamic status of that tissue.

The patient illustrated in the figure in Yonas et al's letter is a case in point. The significance of the low flow in the deep white matter with blood pressure reduction is unknown. There are several possible explanations for the reduced white matter blood flow that do not necessarily invoke selective white matter ischemia caused by hemodynamic factors. The tissue may be dead, with no metabolic demand (hence no need for flow), or the tissue may be injured and unable to autoregulate normally. Furthermore, even if their observation of an apparent flow reduction actually represents viable tissue and failure of autoregulation to maintain blood flow, this alone does not prove the existence of a selectively vulnerable, deep white matter region. The degree of flow reduction in the white matter may be to the same degree as the overlying cortex. Normal baseline cerebral blood flow to the white matter is a fraction of that to the cortex, reflecting inherent differences in metabolic demand.

A longitudinal study of cerebral hemodynamics documenting that selective ischemia is present in the deep white matter (requiring the establishment of normal control values), and that this is associated with future white matter infarction, may be a better approach to addressing the question of an internal borderzone. Our conclusion that structurally normal white matter regions in patients with chronic carotid occlusive disease is not subject to a greater amount of ischemia than the overlying cortex is valid. It remains to be determined if selective ischemia (greater in the deep white matter than in the overlying cortex) caused by hemodynamic factors plays a role in the pathogenesis of deep white matter infarction in patients with acute carotid occlusion. Our data suggest that if selective ischemia does exist, it is unlikely to be a common phenomenon of chronically reduced perfusion pres-

sure. We agree that further study regarding the presence of selective deep white matter ischemia is necessary.

Colin P. Derdeyn, M.D.
Member, Editorial Board

Robert L. Grubb, Jr., M.D.
William J. Powers, M.D.
Washington University School of Medicine
St. Louis, MO

References

1. Derdeyn CP, Simmons NS, Videen TO, et al. **Absence of deep white matter ischemia in chronic carotid disease: A PET study of regional oxygen extraction.** *AJNR Am J Neuroradiol* 2000;21:631-638
2. Grubb RL Jr, Derdeyn CP, Fritsch SM, et al. **The importance of hemodynamic factors in the prognosis of symptomatic carotid occlusion.** *JAMA* 1998;280:1055-1060
3. North American Symptomatic Carotid Endarterectomy Trial (NASCET) Collaborators. **Beneficial effect of carotid endarterectomy in symptomatic patients with high-grade carotid stenosis.** *N Engl J Med* 1991;325:445-453.

Calculating Percent Stenosis

I read with interest the article by Samuels et al (1) regarding the measurement of intracranial arterial stenosis. I do not understand, however, why the authors, and the Warfarin-Aspirin Symptomatic Intracranial Disease method, calculate vessel stenosis by the formula: percent stenosis = $[1 - (D_{\text{stenosis}}/D_{\text{normal}})] \times 100$, where D_{stenosis} = the diameter of the artery at the site of the most severe stenosis, and D_{normal} = the diameter of the normal segment of the artery.

This calculation is a one-dimensional view. Most vessels are circular or elliptical, and the stenoses are frequently asymmetric when viewed in cross section. A vessel with 50% diameter stenosis in one plane is 50% stenotic. If it has 50% stenosis in two planes it is 75% narrowed. The following is the correct formula: percent stenosis = $[1 - ((D_{\text{stenosis } 1} \times D_{\text{stenosis } 2}) / (D_{\text{normal } 1} \times D_{\text{normal } 2}))] \times 100$, where $D_{\text{stenosis } 1}$ and $D_{\text{stenosis } 2}$ = diameters of the stenotic segment in two planes, and $D_{\text{normal } 1}$ and $D_{\text{normal } 2}$ = diameters of the normal artery in two planes.

Joel Schwartz, M.D.
Mid Rockland Imaging
New City, NY

Reference

1. Samuels OB, Joseph GJ, Lynn MJ, Smith HA, Chimowitz MI. **A standardized method for measuring intracranial arterial stenosis.** *AJNR Am J Neuroradiol* 2000;21:643-646