

Are your MRI contrast agents cost-effective?

Learn more about generic Gadolinium-Based Contrast Agents.



FRESENIUS
KABI

caring for life

AJNR

Spontaneous Retropharyngeal Hematoma: Diagnosis by MR Imaging

Alberto Muñoz, Nancy J. Fischbein, Joaquin de Vergas, Jose Crespo and Jose Alvarez-Vincent

AJNR Am J Neuroradiol 2001, 22 (6) 1209-1211

<http://www.ajnr.org/content/22/6/1209>

This information is current as
of April 19, 2024.

Spontaneous Retropharyngeal Hematoma: Diagnosis by MR Imaging

Alberto Muñoz, Nancy J. Fischbein, Joaquin de Vergas, Jose Crespo, and Jose Alvarez-Vincent

Summary: Spontaneous retropharyngeal hematoma is an uncommon entity that is difficult to diagnose and may progress rapidly to airway obstruction. We report a case of a 53-year-old man with acute onset of retropharyngeal pain, dysphonia, and dysphagia after vomiting. On CT, a non-specific retropharyngeal collection was seen. MR imaging demonstrated blood products, suggesting a diagnosis of retropharyngeal hematoma, and the patient was managed conservatively. MR imaging allowed specific diagnosis of a rare condition that is otherwise difficult to diagnose without surgical intervention.

Spontaneous retropharyngeal hematoma (RH) is a rare cause of acute noninflammatory neck swelling that may rapidly evolve to upper respiratory airway obstruction. The diagnosis is often delayed because of its rarity and the absence of objective signs and diagnostic laboratory data in the majority of cases (1–3). Five cases have been reported to date (1, 2). We report a case of spontaneous RH in which the diagnosis was established noninvasively on the basis of MR imaging.

Case Report

A 54-year-old Caucasian man with no history of preexisting neck disease presented to the emergency ward with a 1-day history of sore throat, dysphonia, and dysphagia that had its onset after vomiting that the patient attributed to a fatty meal. Previous medical history included chronic bronchopathy due to heavy smoking, peptic ulcer disease, and alcohol abuse. General examination was unremarkable. The neck was nontender and there was no significant limitation of neck movement. He was afebrile with normal blood pressure. Mild inspiratory stridor was noted on decubitus position. Examination of the oropharynx was unremarkable, but fiberoptic examination of the laryngopharynx showed significant anterior bulging of the posterior pharyngeal wall with reddish discoloration but no ecchymosis. In addition, mild left hemilaryngeal and pharyngolaryngeal fold swelling was noted. Chest X-ray showed mild cardiomegaly. Hematologic evaluation showed a hematocrit of 47.9%, hemoglobin of 15.9 gr/dL, and mean corpus-

cular volume of 94. White blood cell count (per mm³) was 12,700 (neutrophils, 87.5%; leukocytes, 7.0%; monocytes, 4.9%). Platelet count was 215,000/dL. Coagulation tests showed a prothrombin activity of 96%, normal partial-thromboplastin time, and fibrinogen of 485 mg/dL. CT of the neck (Fig 1A) disclosed a midline hypoattenuating retropharyngeal collection, without peripheral enhancement, that ventrally displaced the posterior pharyngolaryngeal wall. The airway was not significantly narrowed. Eight hours later, MR imaging was performed (Fig 1B–E). The image sequences disclosed a retropharyngeal collection that exhibited high signal on routine T1- and T2-weighted sequences. On sagittal T2-weighted fast spoiled gradient-echo sequence, concentric layers of low and high signal were demonstrated. On the basis of the clinicoradiologic findings, a diagnosis of spontaneous retropharyngeal hematoma was suggested. The patient remained stable with no progressive airway compromise. Conservative treatment with fluids and steroids was elected and there was complete resolution of dysphagia and dysphonia. The patient was discharged within 6 days.

Discussion

Retropharyngeal hematoma is a rare entity with a potential for fatal outcome owing to progressive internal blood loss and airway obstruction. The diagnosis can be difficult, as a patient may initially have only a sore throat without shortness of breath and may be misdiagnosed with viral pharyngitis. If a retropharyngeal mass is identified, the patient may be misdiagnosed with retropharyngeal abscess. Most documented causes have occurred in the context of coagulopathic states, trauma, rupture of the carotid artery, bleeding from paraesophageal veins, infection, parathyroid adenoma rupture, metastasis, angiographic procedures, and foreign body ingestion (1–4). Five cases of “spontaneous” RH, without any identifiable predisposing risk factors, have been reported; two of these cases had fatal outcomes (1, 2).

The classical manifestations of cervicomedial hematomas are referred to as “Capp’s triad” and consist of tracheal and esophageal compression, anterior displacement of the trachea, and subcutaneous bruising over the neck and anterior chest (3, 5). In a few cases, the blood loss caused complicating hypovolemic shock (1, 4). However, in cases of moderate RH, clinical signs are related to airway compression and include dysphagia and dysphonia, which may progress to dyspnea and upper respiratory failure, without subcutaneous bruising (2).

Address reprint requests to Alberto Muñoz, Servicio de Radiodiagnostico, Sección de Neuroradiología, Hospital Universitario “12 de Octubre”, Carretera de Andalucía s/n, 28041 Madrid, Spain.

© American Society of Neuroradiology

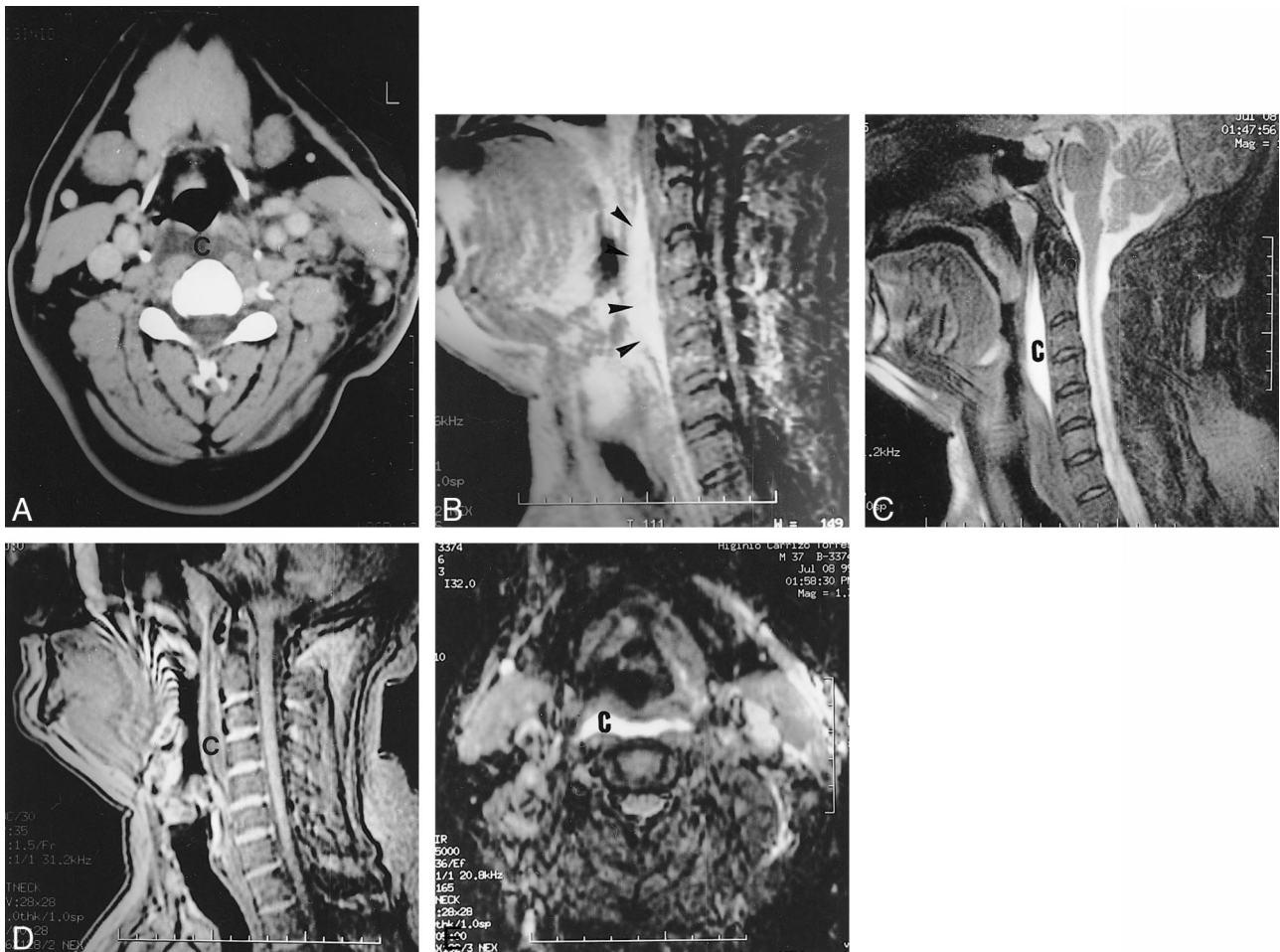


FIG 1. Retropharyngeal hematoma.

A, Enhanced CT scan through the supraglottis shows a well-defined, low-attenuation, midline collection ("C") that separates the posterior pharyngeal wall from the prevertebral muscles, consistent with a retropharyngeal location. No peripheral enhancement is seen. Small nonspecific left jugulodigastric nodes are present.

B and C, Sagittal T1-weighted (B) spin-echo 500/18/2 (TR/TE/excitations) and T2-weighted (C) fast spin-echo (5000/100) images show a hyperintense retropharyngeal collection that extends from the nasopharynx to the laryngopharynx (arrowheads and "C"). The airway is mildly compromised.

D, Sagittal T2-weighted fast spoiled gradient-echo image 35/6/30 (TR/TE/ α°) shows the retropharyngeal collection ("C") that exhibits an outer hyperintense layer and a hypointense central core. Notice upper nasopharyngeal respiratory artifacts.

E, Axial fast inversion recovery T2-weighted 5000/136/150 (TR/T_{eff}/TI), at the level of the floor of the mouth, shows a high-intensity, well-defined, retropharyngeal collection ("C").

Bleeding into the retropharyngeal space is serious because of the anatomic peculiarity of the pharyngeal muscles, whose insertions move toward their origins, offering no resistance to expansion of the hematoma. As the hematoma expands, compression of the arythenoid cartilage can occur, closing the vocal cords and obstructing the airway (2).

Clinical diagnosis of spontaneous RH can be difficult unless a history of coagulopathy, trauma, or foreign body ingestion is elicited. Laryngoscopic inspection usually shows signs of pharyngolaryngeal swelling, with no signs of the bleeding source, and a tentative diagnosis of infection or tumor is usually made.

Our patient presented with acute onset of mild dyspnea and dysphonia after vomiting. Vomiting and Valsalva maneuver are predisposing factors for triggering hemorrhage, particularly in the upper al-

imentary tract and cervical region, whether spontaneous in healthy individuals or in association with underlying conditions (1, 6). When bleeding occurs in the head and neck, a proposed mechanism associated with vomiting and Valsalva maneuver is an increase in intrathoracic pressure leading to an increase in jugular pressure, which is in turn transmitted to tributary valveless veins and leads to rupture of bridging veins (7). Alternatively, RH can develop following arterial avulsion that occurs during a violent coughing or sneezing episode (8).

Although our patient manifested no coagulopathic state or had history of trauma, he may have been at increased risk for developing the so-called "spontaneous" hematoma because of his history of alcohol abuse and potential for para-alimentary varices that may have ruptured in the context of severe vomiting. On the basis of the clinical find-

ings and laboratory data alone, the diagnosis of retropharyngeal hematoma was not initially suspected, and other more common conditions, such as infection, were considered. In this case, as in other reported cases (1), a tentative diagnosis of retropharyngeal infection was made on the basis of the clinical and CT findings.

MR has proven to be an increasingly important diagnostic tool in the head and neck, not only in head and neck oncology, but also in head and neck infections (9). MR offers several advantages over CT in terms of multiplanar anatomic display and superior soft-tissue contrast, often allowing more specific diagnoses to be made. MR is, however, less available and requires more patient cooperation, and is therefore difficult to perform in acutely ill patients who may not have stable airways. In this case, in which the patient's airway was stable enough to allow MR imaging, MR not only better depicted the extent of the retropharyngeal lesion but, most important, was able to identify acute and subacute blood products, thereby affecting both diagnosis and management.

MR is sensitive to blood products in different stages of evolution because of the paramagnetic signal properties of the blood products, which change over the time depending on their dominant component (acute deoxyhemoglobin, subacute intra- or extracellular methemoglobin, and chronic hemichromes). The evolution of the MR appearance of non-CNS hematomas is less well characterized and more variable than are those of the brain and spine, because the CNS possesses a blood-brain barrier, has a high oxygen concentration, and lacks rapid response from macrophages (10–12). In acute or early subacute soft-tissue hematomas, the MR signal characteristics may vary depending on several factors (10, 12). The diagnosis of hematoma can be made as early as a few hours after the acute event, when hyperintensity is seen on both T1- and T2-weighted sequences (13), and this diagnosis is reinforced when changes due to magnetic susceptibility effects are demonstrated on gradient-echo sequences (10, 14). Gradient-echo's fast acquisition technique is more sensitive than is conventional spin-echo, especially fast spin-echo sequences, in the detection of magnetic susceptibility effects induced by static field inhomogeneities arising from paramagnetic blood breakdown products, and this is particularly true for acute hematomas (10, 14, 15). Our patient exhib-

ited hyperintensity on both T1- and T2-weighted sequences, as well as susceptibility effects on a gradient-echo sequence. This allowed the diagnosis of retropharyngeal hematoma to be made with certainty, explaining the clinical picture.

In summary, we present a case of an adult who developed the acute onset of symptoms related to an acute retropharyngeal process in whom MR suggested a specific diagnosis of retropharyngeal hematoma. This potentially life-threatening condition can be difficult to diagnose clinically and by CT imaging. Moreover, this case raises the possibility that cases of acute retropharyngeal swelling of unknown origin may be recognized in clinical practice.

References

1. Chin KW, Sercarz JA, Wang MB, Andrews R. **Spontaneous cervical hemorrhage with near-complete airway obstruction.** *Head Neck* 1998;20:350–353
2. DiFrancesco RC, Escamilla JS, Sennes LU, et al. **Spontaneous cervical hematoma: a report of two cases.** *Ear Nose Throat J* 1999;78:168–175
3. Al-Fallouji HK, Snow DG, Kuo MJ, Johnson PJE. **Spontaneous retropharyngeal hematoma: two cases and review of the literature.** *J Laryngol Otol* 1993;107:649–650
4. Ku P, Scott P, Kew J, van Hasselt A. **Spontaneous retropharyngeal hematoma in a parathyroid adenoma.** *Aust N Z J Surg* 1998;68:619–621
5. Capps RB. **Multiple parathyroid tumors within massive mediastinal and subcutaneous hemorrhage.** *Am J Med Sci* 1954; 188:800–805
6. Hiller N, Zagal I, Hadas-Halpern I. **Spontaneous intramural hematoma of the esophagus.** *Am J Gastroenterol* 1999;94: 2282–2284
7. Boyer MM, Lucarelli MJ. **Valsalva-induced subperiosteal hematoma during migraine.** *Arch Ophthalmol* 1998;116:106–107
8. Owens DE, Calcaterra TC, Aarstad RA. **Retropharyngeal hematoma. A complication of therapy with anticoagulants.** *Arch Otolaryngol* 1975;101:565–568
9. Muñoz A, Ballesteros AI, Brandáriz-Castelo JA. **Primary lingual abscess presenting as acute swelling of the tongue obstructing the upper airway: diagnosis by MR.** *AJNR Am J Neuroradiol* 1998;19:496–498
10. Bradley WG. **MR appearance of hemorrhage in the brain.** *Radiology* 1993;189:15–26
11. Rubin JJ, Gomori JM, Grossman RI, et al. **High-field MR imaging of extracranial hematomas.** *AJR Am J Roentgenol* 1987; 148:813–817
12. Bluemke DA. **Definitive diagnosis of intramural hematoma of the thoracic aorta with MR imaging.** *Radiology* 1997;204: 319–321
13. White P, Seymour R, Powell N. **MRI assessment of the prevertebral soft tissues in the acute cervical spine trauma.** *Br J Radiol* 1999;72:818–823
14. Atlas SW, Mark AS, Grossman RI, et al. **Intracranial hemorrhage: gradient-echo MR imaging at 1.5 T. Comparison with spin-echo imaging and clinical applications.** *Radiology* 1988; 168:803–807
15. Liang L, Kozogi Y, Sugahara T, et al. **Detection of intracranial hemorrhage with susceptibility-weighted MR sequences.** *AJNR Am J Neuroradiol* 1999;20:1527–1534