

Are your **MRI contrast agents** cost-effective?

Learn more about generic **Gadolinium-Based Contrast Agents**.



**FRESENIUS
KABI**

caring for life

AJNR

**De Novo Aneurysm Formation After
Stereotactic Radiosurgery of a Residual
Arteriovenous Malformation: Case Report**

Paul P. Huang, Toshifumi Kamiryo and P. Kim Nelson

AJNR Am J Neuroradiol 2001, 22 (7) 1346-1348

<http://www.ajnr.org/content/22/7/1346>

This information is current as
of April 19, 2024.

Case Report

De Novo Aneurysm Formation After Stereotactic Radiosurgery of a Residual Arteriovenous Malformation: Case Report

Paul P. Huang, Toshifumi Kamiryo, and P. Kim Nelson

Summary: We report a case of a 19-year-old woman who underwent radiosurgical treatment of a residual arteriovenous malformation. Nine months after treatment, repeat angiography revealed a de novo paranasal aneurysm that was treated endovascularly. We postulate that changes in flow dynamics or vessel integrity after radiosurgery contributed to the formation of her de novo aneurysm.

Stereotactic radiosurgery is a well-established treatment option for arteriovenous malformations (AVMs). The potential complications related to radiosurgery are well documented and are predominantly related to radiation effects to the surrounding brain parenchyma (1, 2). Following treatment, complete obliteration of a vascular lesion may not occur for several years. During this latency period, the patient remains at risk for hemorrhage. Despite concerns for increased risk of hemorrhage during the early experience with radiosurgery, subsequent studies have shown that the hemorrhage rate is comparable to the natural history of these lesions (3, 4).

This report describes a patient who underwent a subtotal resection of a large left hemispheric AVM followed by gamma knife treatment of her residual nidus. Nine months after treatment, she developed increased seizures associated with an episodic postictal hemiparesis. Repeat angiography showed a de novo paranasal aneurysm arising from a distal anterior cerebral artery branch supplying her residual nidus. This case suggests that, in certain circumstances, changes following radiosurgery may predispose to aneurysm formation in feeding vessels.

Case Report

This 19-year-old right-handed woman presented with a left frontal intraparenchymal hemorrhage and a right hemiplegia 2 years before the writing of this report. Her workup revealed a large left frontoparietal AVM. The patient subsequently un-

derwent preoperative embolization followed by a microsurgical resection of her lesion at an outside institution. Her family declined immediate postoperative angiography.

The patient recovered well and was able to ambulate independently with a mildly spastic gait 1 year after her procedure. A follow-up angiogram was eventually obtained that revealed a small residual nidus (Fig 1), and the patient underwent gamma knife treatment of the nidus. The total volume of the lesion was 0.25 cm³. The margin of the nidus was covered by the 50% isodose line, and 25 Gy were delivered to the margin.

Nine months after her treatment, the patient developed intermittent sensory seizures. MR imaging suggested the presence of a new aneurysm. Repeat angiography revealed a reduction in flow to the nidus and confirmed the presence of a de novo paranasal aneurysm arising from a distal pericallosal branch vessel supplying the residual nidus (Figs 2 and 3). The feeding vessel was subsequently embolized and the nidus was obliterated (Fig 4).

Discussion

Microsurgical resection remains the most effective treatment for AVMs of the brain. However, depending on the size and location of the lesion, surgery may carry an unacceptable risk of serious neurologic sequela. Over the past several years, the development of endovascular and radiosurgical techniques have improved our ability to treat lesions that were previously considered untreatable.

The advantages and disadvantages of stereotactic radiosurgery for brain AVMs have been discussed extensively in the literature (4–6). Complete obliteration of an AVM after radiosurgery is not immediate. During this latency period, the patient remains at risk for hemorrhage. The hemorrhage rate during this latency is similar to the rate of hemorrhage in untreated AVMs (3, 4). However, the presence of intranasal aneurysms or venous outflow stenosis may increase the near-term risk of hemorrhage. Radiosurgical treatment of lesions with these angioarchitectural features may carry a higher risk of hemorrhage before complete obliteration is achieved.

Three types of aneurysms are associated with cerebral AVMs: flow-related aneurysms, intranasal aneurysms, and congenital aneurysms. Flow-related aneurysms are probably acquired lesions and typically involve a vascular root supplying the AVM. They presumably result from increased shear stress along the vessel wall due to the hyperdynamic flow through the arteriovenous shunt. They

Received December 15, 2000; accepted December 22.

From the Departments of Neurosurgery (P.P.H.) and Radiology (Interventional Neuroradiology) (T.K., P.K.N.), New York University Medical Center, New York, NY.

Address reprint requests to Paul P. Huang, MD, Department of Neurosurgery, NYU Medical Center, 530 First Ave., Suite 8R, New York, NY 10016.

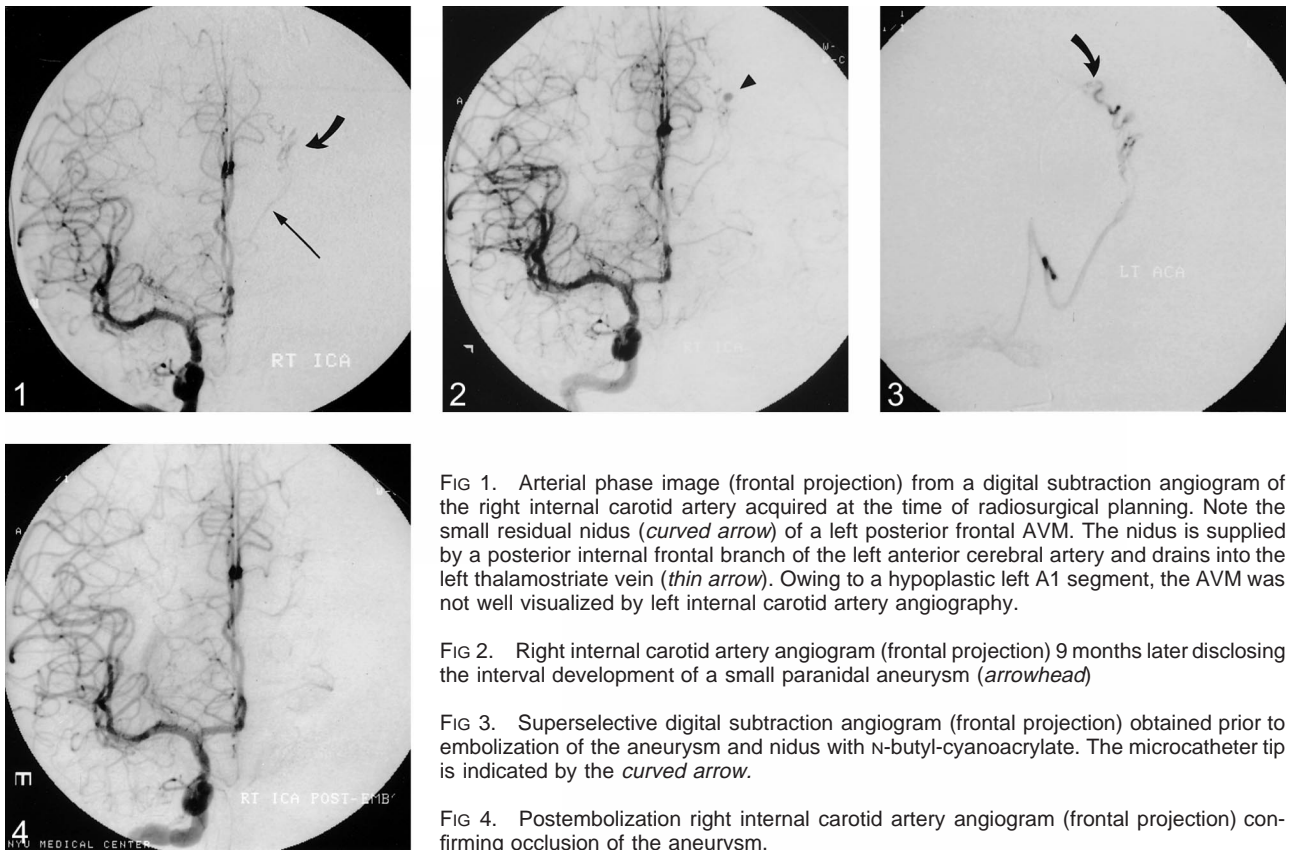


FIG 1. Arterial phase image (frontal projection) from a digital subtraction angiogram of the right internal carotid artery acquired at the time of radiosurgical planning. Note the small residual nidus (*curved arrow*) of a left posterior frontal AVM. The nidus is supplied by a posterior internal frontal branch of the left anterior cerebral artery and drains into the left thalamostriate vein (*thin arrow*). Owing to a hypoplastic left A1 segment, the AVM was not well visualized by left internal carotid artery angiography.

FIG 2. Right internal carotid artery angiogram (frontal projection) 9 months later disclosing the interval development of a small paranasal aneurysm (*arrowhead*)

FIG 3. Superselective digital subtraction angiogram (frontal projection) obtained prior to embolization of the aneurysm and nidus with n-butyl-cyanoacrylate. The microcatheter tip is indicated by the *curved arrow*.

FIG 4. Postembolization right internal carotid artery angiogram (frontal projection) confirming occlusion of the aneurysm.

occur in multiple locations in over half of patients affected.

Intranidal aneurysms occur in 5.5% to 58% of AVMs (7, 8). They are frequently multiple and usually less than 4 to 5 mm in size. These aneurysms typically arise from a feeding artery as it merges into the nidus. These aneurysms exhibit a thin wall of 3 to 4 cell layers, scant smooth muscle, and no elastic fibers. They are associated with an increased incidence of hemorrhage (8) and may occur in approximately 40% of patients with intracranial hemorrhage related to an AVM.

There are several possible explanations for the de novo formation of a paranasal aneurysm in our patient. Potentially, a preferential radiotherapeutic effect on venular vascular structures within the nidus could have increased venous outflow impedance, thereby increasing intraluminal pressure within the supplying arteries proximal to the AVM nidus. Increased cerebral vessel diameter within targeted radiation fields has been demonstrated in experimental settings (9). The pathogenesis of this phenomenon has been ascribed to downstream microvascular occlusion or impaired venous drainage acting to increase intraluminal pressures within the upstream microvasculature. It seems reasonable that a reduction in flow through the nidus could result in increased intramural pressure in the feeding artery and subsequent aneurysm formation.

Alternatively, a focal vasculopathic effect of the radiation on the vessel wall could have led to an-

eurysm formation (10). The location of the aneurysm was in close proximity to the treatment margins. Retrospective review of the treatment plan showed that the feeding vessel received 20 Gy of radiation at the site of aneurysm formation. Doses as low as 5–9 Gy may be sufficient to cause changes in normal vessels (11). Radiation effects to blood vessels result in intimal hyperplasia and stenosis (9), although these specific structural changes are not known to increase the risk of aneurysm formation. Finally, formation of the aneurysm in our patient may have been part of the natural history of her lesion, independent of her treatment.

It is difficult to know, from a single case report, what set of factors or circumstances led to aneurysm formation in our patient. We were fortunate in documenting the progression of these events before a new rupture. It seems reasonable that changes in flow dynamics and/or vasculopathic effects after radiation treatment may, in certain circumstances, predispose these patients to an increased risk of rupture. However, it is doubtful that this is a common occurrence since the overall hemorrhage rate after treatment is comparable to the hemorrhage rate of untreated lesions.

References

1. Karlsson B, Lax I, Soderman M. Factors influencing the risk for complications following Gamma Knife radiosurgery of cerebral arteriovenous malformations. *Radiother Oncol* 1997;43: 275–280

2. Flickinger JC, Kondziolka D, Pollock BE, Maitz AH, Lunsford LD. **Complications from arteriovenous malformation radiosurgery: multivariate analysis and risk modeling.** *Int J Radiat Oncol Biol Phys* 1997;38:485-490
3. Karlsson B, Lindquist C, Steiner L. **Effect of Gamma Knife surgery on the risk of rupture prior to AVM obliteration.** *Minim Invasive Neurosurg* 1996;39:21-27
4. Lunsford LD, Kondziolka D, Flickinger JC, et al. **Stereotactic radiosurgery for arteriovenous malformations of the brain[see comments].** *J Neurosurg* 1991;75:512-524
5. Luxton G, Petrovich Z, Jozsef G, Nedzi LA, Apuzzo ML. **Stereotactic radiosurgery: principles and comparison of treatment methods.** *Neurosurgery* 1993;32:241-259 Discussion 259
6. Ogilvy CS. **Radiation therapy for arteriovenous malformations: a review[see comments].** *Neurosurgery* 1990;26:725-735
7. Redekop G, TerBrugge K, Montanera W, Willinsky R. **Arterial aneurysms associated with cerebral arteriovenous malformations: classification, incidence, and risk of hemorrhage.** *J Neurosurg* 1998;89:539-546
8. Turjman F, Massoud TF, Vinuela F, Sayre JW, Guglielmi G, Duckwiler G. **Aneurysms related to cerebral arteriovenous malformations: superselective angiographic assessment in 58 patients.** *AJNR Am J Neuroradiol* 1994;15:1601-1605
9. Kamiryo T, Kassell NF, Thai QA, Lopes MB, Lee KS, Steiner L. **Histological changes in the normal rat brain after gamma irradiation.** *Acta Neurochir* 1996;138:451-459
10. Casey AT, Marsh HT, Uttley D. **Intracranial aneurysm formation following radiotherapy.** *Br J Neurosurg* 1993;7:575-579
11. Yamamoto M, Ide M, Jimbo M, Ono Y. **Middle cerebral artery stenosis caused by relatively low-dose irradiation with stereotactic radiosurgery for cerebral arteriovenous malformations: case report.** *Neurosurgery* 1997;41:474-477; discussion 477-478