

Are your **MRI contrast agents** cost-effective?

Learn more about generic **Gadolinium-Based Contrast Agents**.



**FRESENIUS  
KABI**

caring for life

**AJNR**

**Demonstration of Glycine Peaks at 3.50 ppm  
in a Patient with van der Knaap Syndrome**

R. Nuri Sener

*AJNR Am J Neuroradiol* 2001, 22 (8) 1587-1589

<http://www.ajnr.org/content/22/8/1587>

This information is current as  
of April 19, 2024.

## Demonstration of Glycine Peaks at 3.50 ppm in a Patient with van der Knaap Syndrome

R. Nuri Sener

**Summary:** Elevated levels of glycine in the CSF have recently been documented in van der Knaap syndrome (diffuse leukoencephalopathy associated with cystic degeneration of the white matter). This report describes a patient affected with the syndrome in whom proton MR spectroscopy showed probable glycine peaks at 3.50 ppm in the brain parenchyma. An experimental study with a superconducting 9.397-T laboratory spectrometer identified the location of pure glycine at 3.52 ppm, originating from the methylene (CH<sub>2</sub>) group of the molecule. This suggests that the peak at 3.50 ppm in patients with van der Knaap syndrome may belong to glycine, as a slight shift in peak resonances is possible as a result of spatial electron interactions.

Van der Knaap syndrome is a new entity associated with diffuse leukoencephalopathy and cystic degeneration of the white matter of the brain. The clinical course is mild and slowly progressive (1–7). In a recent report, van der Knaap et al (8) documented the presence of glycine in the CSF in five of their patients. In our patient with van der Knaap syndrome, proton MR spectroscopy showed prominent peaks of the brain parenchyma at 3.50 ppm, distinct from the *myo*-inositol peak. This finding corresponded to the results of an experimental study on glycine.

### Case Report

A 14-month-old boy with macrocephaly (over 98 percentile) and moderate retardation of motor development was studied with MR imaging and proton MR spectroscopy on a superconducting 1.5-T MR unit. Spectra were obtained with the chemical-shift mode using the spin-echo point-resolved spectroscopy technique with parameters of 1500/40 (TR/TE). MR imaging findings were consistent with a recently described syndrome associated with diffuse leukoencephalopathy and cystic degeneration of the white matter of the brain (van der Knaap syndrome). At MR spectroscopy, a peak at 3.50 ppm was evident, separate from the *myo*-inositol peak at 3.56 ppm.

Under the assumption that the peak at 3.50 ppm could represent glycine, an *in vitro* experimental study was undertaken. A proton MR spectrum of pure glycine was recorded using a Bruker DPX-400 spectrometer with a superconducting 9.397-T magnet operating at 400 MHz. Tetramethylsilane was the reference medium, and deuteriochloroform (CDCl<sub>3</sub>) was used as the solvent for pure glycine. Glycine revealed a peak at 3.52

ppm, originating from the methylene (CH<sub>2</sub>) group of its molecule (Fig 1). The experiment thus provided the exact location of the pure glycine peak. This finding with respect to pure glycine strongly suggests that the peak at 3.50 ppm could belong to glycine, as it is known that a slight shift of peak resonances is possible as a result of spatial electron interactions.

Characteristic white matter changes in the patient with van der Knaap syndrome, including widespread cerebral signal abnormalities and cystic degeneration of the white matter, was shown on a fluid-attenuated inversion-recovery (FLAIR) image (Fig 2A). A distinct and prominent peak, resonating at 3.50 ppm, which probably belonged to glycine, was consistently present in almost every volume of interest of the spectroscopic imaging sequence in both cerebral hemispheres. In one of the spectra, this peak was dominant, with an amplitude value of 4.90 mV, whereas that of *N*-acetyl aspartate (NAA) was 4.44 mV, that of creatine (Cr) was 3.83 mV, and that of choline (Cho) was 4.49 mV (Fig 2B).

In addition to these values, the relationships among the peaks of NAA, Cho, Cr, and *myo*-inositol were evaluated and compared with findings in eight age-matched control cases. NAA/Cho and NAA/Cr ratios were normal in some regions; however, in some parts of the brain the NAA peaks were low and the Cho peaks were high, resulting in decreased NAA/Cho ratios and increased Cho/Cr ratios.

### Discussion

The feature that distinguishes van der Knaap syndrome from other leukoencephalopathies associated with either large or normal-size heads appears to be the presence of temporal and frontal white matter cysts in combination with diffuse white matter abnormality on CT and MR studies (1–7). The presence of cystic degeneration of the white matter can be confirmed by FLAIR and diffusion-weighted imaging (9). In our patient, the FLAIR MR imaging findings were identical to those described previously (Fig 2). It has been reported that in laboratory investigations, no abnormalities of amino acids, organic acids, lysosomes, peroxisomes, or mitochondria could be found (1–7). Recently, however, van der Knaap et al (8) documented moderate elevation of glycine in the CSF of five patients, reaching a level considered diagnostic for nonketotic hyperglycinemia. Several previous investigators reported the MR spectroscopy findings of glycine in nonketotic hyperglycinemia (10), brain tumors (11–13), and other conditions (14). Because the glycine peak is very close to that of *myo*-inositol, resonating at 3.56 ppm, discriminating between the two has been problematic; thus, some authors have concluded from clinical studies

Received December 7, 2000; accepted after revision March 20, 2001.

From the Department of Radiology, Ege University Hospital, Bornova, Izmir, 35100, Turkey.

Address reprint requests to Prof. Dr. R. Nuri Sener.

FIG 1. Proton MR spectrum of pure glycine, recorded using a laboratory spectrometer with a 9.397-T magnet, reveals the peak at 3.52 ppm.

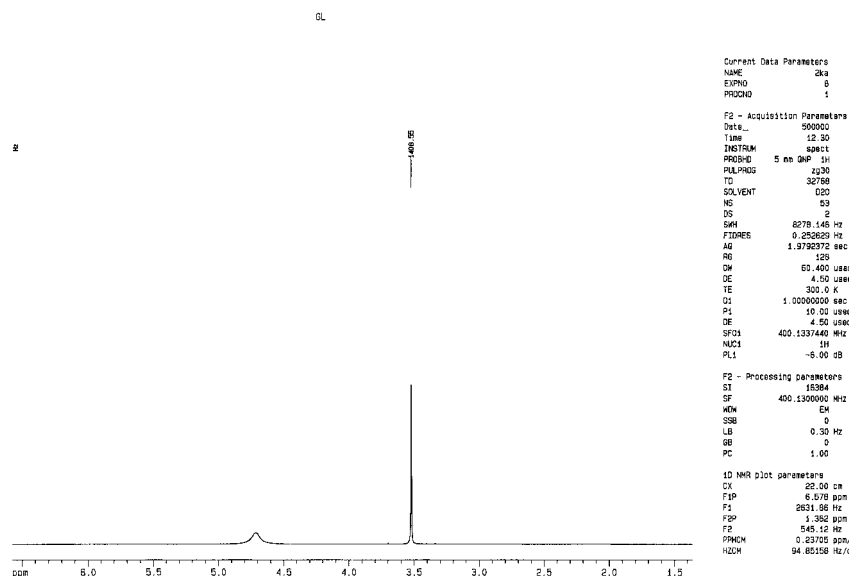
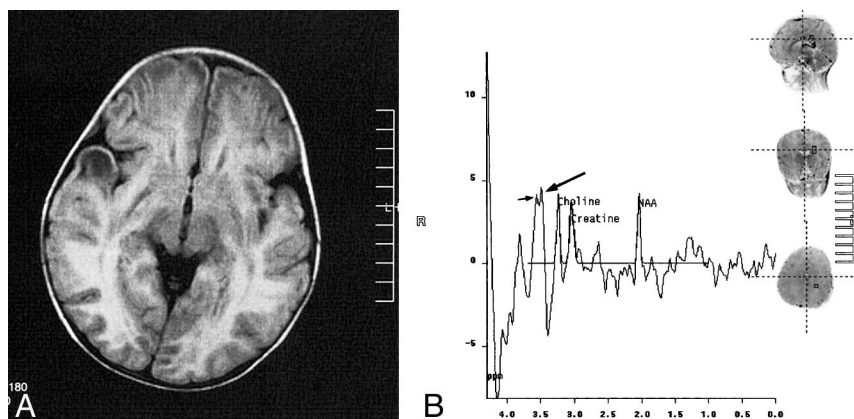


FIG 2. 14-month-old boy with van der Knaap syndrome.

A, FLAIR image shows widespread signal abnormality and characteristic cystic degeneration of the white matter in the right temporal lobe.

B, Spectrum obtained at 1500/40 (TR/TE) in a voxel from the left hemisphere reveals that the most prominent peak belongs to glycine, at 3.50 ppm (long arrow). Note that to the left of the glycine peak is that of *myo*-inositol, at 3.56 ppm (short arrow).



that *myo*-inositol and glycine reveal a combined (single) peak at about 3.56 ppm (10–13).

In the MR spectroscopy examination of our patient with van der Knaap syndrome, however, the peak resonating at 3.50 ppm, which was clearly and distinctly separate from the nearby *myo*-inositol peak, most likely represented the glycine peak. In the *in vitro* experiment with the Bruker DPX-400 spectrometer, the peak of pure glycine was at 3.52 ppm. Thus, this experiment established the exact *in vitro* spectroscopic location of pure glycine. This slight difference between the resonances can be explained by the known possibility of a shift of peak resonances caused by spatial electron interactions of nearby molecules, resulting from deshielding effects. This was probably the case with the *in vivo* environment of our patient. These considerations, and the experimental findings with respect to glycine, strongly suggest that the peak at 3.50 ppm belonged to glycine.

Van der Knaap et al (8) noted that glycine is an excitatory amino acid, a neurotransmitter for the brain, and in many different brain diseases (including nonketotic hyperglycinemia, stroke, meningoencephalitis, Huntington chorea, migraine, Parkin-

son disease, Alzheimer disease, and others) glycine increases in the CSF. These authors concluded that elevated glycine levels in the CSF may reflect either excitotoxic brain damage or a primary disorder of glycine metabolism in their eponymous syndrome (8). In our patient, the presence of prominent glycine peaks in the brain parenchyma may indicate that the syndrome could be caused by a primary disorder of glycine metabolism; however, an excitotoxic mechanism cannot be excluded.

In previously reported cases of van der Knaap syndrome, MR spectroscopy revealed decreased NAA/Cr ratios and increased Cho/Cr ratios as compared with healthy persons (1, 5, 9). In the patient reported here, similar findings were evident, and although the NAA/Cho and NAA/Cr ratios appeared to be normal in many regions, the NAA peaks were low and the Cho peaks were high in some parts of the brain, resulting in decreased NAA/Cho ratios and increased Cho/Cr ratios as compared with the spectroscopic findings in our eight control cases. It is known that a decrease in the NAA peak represents decreased neuronal viability, neuronal function, and neuronal loss. On the other hand, the Cho peak tends to increase in dis-

ease processes associated with cell membrane breakdown and increased cell membrane synthesis (1, 5, 9). Corresponding changes in these metabolites as well as in their ratios appear to be in conformity with the slowly progressive nature of van der Knaap syndrome.

### Conclusion

Pure glycine resonates at 3.52 ppm. Electron interactions can cause a slight shift of its resonance to 3.50 ppm. It has been shown that, in humans, brain levels of amino acids can be studied only indirectly by measuring their levels in the CSF (8). Proton MR spectroscopy, however, noninvasively depicts a number of metabolites, including amino acids and others. With respect to our patient with van der Knaap syndrome, in light of the experimental and imaging studies, it is probable that in in vivo environments glycine resonates with a peak centered at 3.50 ppm, owing to electron interactions. Thus, the glycine peak is distinct from the *myo*-inositol peak, which is centered at 3.56 ppm. In this patient, the glycine peaks were distinctly present in the brain in almost every voxel of the spectroscopic imaging sequence. Furthermore, in one of the spectra, the glycine peak was dominant, with an amplitude value of 4.90 mV, higher than those of NAA, Cr, and Cho. Documentation of these prominent glycine peaks in the brain parenchyma may indicate the presence of a disorder of glycine metabolism in van der Knaap syndrome, although an excitotoxic mechanism cannot be excluded.

### Reference

1. van der Knaap MS, Barth PG, Stroink H. **Leukoencephalopathy with swelling and a discrepantly mild clinical course in eight children.** *Ann Neurol* 1995;37:324-334
2. van der Knaap MS, Valk J, Barth PG, Smit LM, van Engelen BG, Tortori Donati P. **Leukoencephalopathy with swelling in children and adolescents: MRI patterns and differential diagnosis.** *Neuroradiology* 1995;37:679-686
3. Gontieres F, Bouloche J, Bourgeois M, Aicardi J. **Leukoencephalopathy, megalencephaly, and mild clinical course: a recently individualized familial leukodystrophy: report on five new cases.** *J Child Neurol* 1996;11:439-444
4. van der Knaap MS, Barth PG, Vrensen GF, Valk J. **Histopathology of an infantile-onset spongiform leukoencephalopathy with a discrepantly mild clinical course.** *Acta Neuropathol* 1996;92:206-212
5. van der Knaap MS, Kamphorst W, Barth PG, Kraaijeveld CL, Gut E, Valk J. **Phenotypic variation in leukoencephalopathy with vanishing white matter.** *Neurology* 1998;51:540-547
6. Yakinci C, Soylu H, Kutlu NO, Sener RN. **Leukoencephalopathy with a mild clinical course: a case report.** *Comput Med Imaging Graph* 1999;23:169-172
7. Topcu M, Saatci I, Apak RA, Soylemezoglu F. **A case of leukoencephalopathy with vanishing white matter.** *Neuropediatrics* 2000;31:100-103
8. van der Knaap MS, Wevers RA, Kure S, et al. **Increased cerebrospinal fluid glycine: a biochemical marker for a leukoencephalopathy with vanishing white matter.** *J Child Neurol* 1999;14:728-731
9. Sener RN. **Van der Knaap syndrome: MR imaging findings including FLAIR, diffusion imaging, and proton MR spectroscopy.** *Eur Radiol* 2000;10:1452-1455
10. Heindel W, Kugel H, Roth B. **Noninvasive detection of increased glycine content by proton MR spectroscopy in the brains of two infants with nonketotic hyperglycinemia.** *AJNR Am J Neuroradiol* 1993;14:629-635
11. Gutowski NJ, Gomez-Anson B, Torpey N, Revesz T, Miller D, Rudge P. **Oligodendroglial gliomatosis cerebri: <sup>1</sup>H-MRS suggests elevated glycine/inositol levels.** *Neuroradiology* 1999;41:650-653
12. Mader I, Roser W, Hagberg G, et al. **Proton chemical shift imaging, metabolic maps, and single voxel spectroscopy of glial brain tumors.** *MAGMA* 1996;4:139-150
13. Kim DG, Choe WJ, Chang KH, et al. **In vivo proton magnetic resonance spectroscopy of central neurocytomas.** *Neurosurgery* 2000;46:329-333
14. Nishina M, Kato T, Ito M, Takashima S. **In vitro high resolution proton magnetic resonance study of human cerebellar development during the period from the fetus to childhood.** *Physiol Chem Phys Med NMR* 1999;31:103-108