

Are your **MRI contrast agents** cost-effective?

Learn more about generic **Gadolinium-Based Contrast Agents**.



**FRESENIUS
KABI**

caring for life

AJNR

Separate Origins of the Left Internal and External Carotid Arteries from the Aortic Arch: MR Angiographic Findings

Sinan Cakirer, Ercan Karaarslan, Murat Kayabali and Izzet Rozanes

This information is current as of April 18, 2024.

AJNR Am J Neuroradiol 2002, 23 (9) 1600-1602
<http://www.ajnr.org/content/23/9/1600>

Case Report

Separate Origins of the Left Internal and External Carotid Arteries from the Aortic Arch: MR Angiographic Findings

Sinan Cakirer, Ercan Karaarslan, Murat Kayabali, and Izzet Rozanes

Summary: Agenesis of the left common carotid artery with independent origins of the internal and external carotid arteries arising directly from the aortic arch is an extremely rare congenital anomaly. We present MR angiographic findings in a case with agenesis of left common carotid artery that, to our knowledge, is unique by virtue of its detection and description with MR angiography.

Agenesis of the left common carotid artery is a rare congenital anomaly characterized by independent origins of the left internal and external carotid arteries that arise directly from the aortic arch. The literature includes few cases in which the diagnosis is established by using invasive angiographic procedures or duplex sonographic examination of the carotid arteries (1–5).

We present a case of agenesis of left common carotid artery in a 68-year-old female patient that was diagnosed with contrast-enhanced MR angiography (MRA) of the carotid arteries. To our knowledge, this is the first report of such a rare congenital anomaly with MRA findings.

Case Report

A 68-year-old female patient presented with a sudden onset of left-sided mild hemiparesis that gradually resolved over 48 hours. She had a medical history of arterial hypertension that had been medically controlled for more than 25 years. Emergency CT of the brain was performed, and the findings were normal except for the findings of mild age-related cerebral atrophy and a few hypoattenuating ischemic foci in the bilateral centrum semiovale. Color Doppler sonographic examination of the neck arteries revealed low bifurcation of the right common carotid artery however; the left common carotid artery could not be precisely evaluated.

MRA study of the supra-aortic vessels was performed by using a 1.5-T MR imager with a fast gradient capability and a polarized phase-array head and neck coil (Magnetom Vision; Siemens, Erlangen, Germany). Three-dimensional contrast-enhanced MRA images were acquired after the intravenous administration of 0.15 mmol/kg gadopentetate dimeglumine

(Magnevist; Schering, Berlin, Germany) at a rate of 2 mL/s followed by 20-mL bolus of saline solution. For supra-aortic MRA imaging, 3D spoiled gradient-echo images were acquired in a sequential k-space order. Interpolation in the section-select direction was used at two time points (the arterial and venous phases) with identical parameters to perform subtraction both before and after the injection of contrast material. The imaging slab was positioned in the coronal oblique orientation parallel to the courses of the carotid circulation. The sequence parameters for 3D contrast-enhanced MRA were the following: TR/TE, 5.2/2.1; flip angle, 25°; slab volume, 60 cm; effective section thickness, 0.8 mm; and matrix, 224 × 256. The acquisition time was 21 seconds. Maximum intensity projection and a volume-rendering technique (VRT) were applied to arterial-phase contrast-enhanced subtracted images. The VRT algorithm for MRA was performed on a satellite workstation with an MR vessel unshaded algorithm (Magic View 1000; Siemens, Erlangen, Germany). This procedure accounted for the translucency of 3D images.

An MRA study clearly revealed a low bifurcation of the common carotid artery on the right side, the left common carotid artery was absent, and the internal and external carotid arteries arose directly from separate origins on the aortic arch (Fig). An additional MRA study of the intracranial arteries did not show any associated intracranial arterial lesion or variation.

Discussion

The absence of left common carotid artery is an extremely rare congenital anomaly in which the internal and external carotid arteries originate directly from the aortic arch. Lie (1) described the details of this anomaly with its embryologic development and angiographic characteristics. A search of the literature starting from 1968 revealed only four cases of agenesis of left common carotid artery. In all cases, the condition was diagnosed by using intraarterial angiography of the supra-aortic vessels (2–5), with additional duplex sonography of the neck arteries in one case (5).

Noninvasive imaging techniques such as color Doppler sonography and MRA have become widely used in the clinical diagnosis of carotid artery diseases. MRA, especially MRA with the recently developed contrast enhancement techniques, has become the study of choice because its high resolution and diagnostic accuracy. Compared with angiography, the reference standard in the diagnosis of arterial diseases, MRA is not invasive and eliminates the intravenous administration of iodinated contrast material.

With the widespread use of MRA, arterial congenital anomalies are increasingly identified during studies to assess for arterial diseases. Although MRA and

Received March 26, 2002; accepted after revision May 30.

From the Department of Radiology, Istanbul Sisli Etfal Hospital (S.C.); the Department of Radiology, American Hospital (E.K.); and the Department of Surgery, Vascular Surgery Unit (M.K.) and the Department of Radiology (I.R.), Faculty of Medicine, Istanbul University, Turkey.

Address reprint requests to Sinan Cakirer, 67 Ada, Kardelen 4/2, Daire 37, 81120 Atasehir-Istanbul, Turkey.

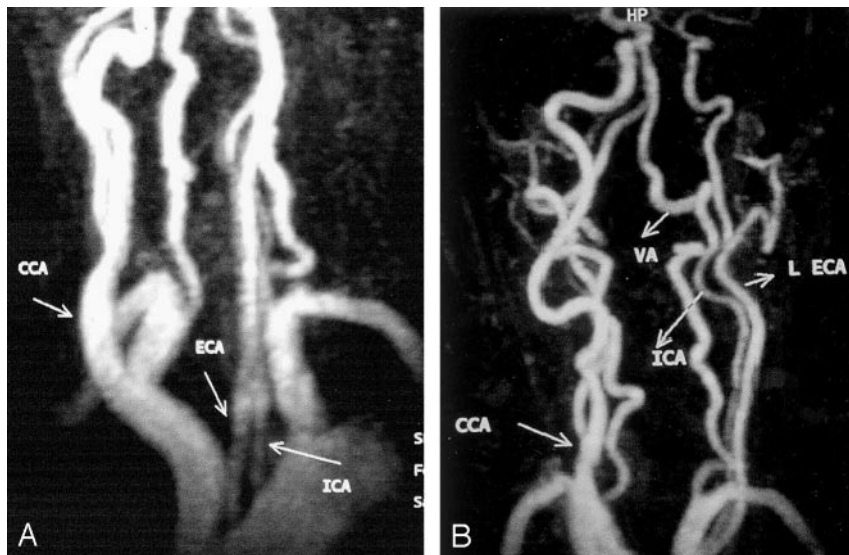


FIG 1. Contrast-enhanced 3D MRA images (5.2/2.1, 25° flip angle) of the neck show the independent origins of the left internal carotid artery (ICA) and external carotid arteries (ECA and L ECA) that arise directly from the aortic arch. Note that a low carotid bifurcation (CCA) is associated on the right side. VA indicates the left vertebral artery.

intraarterial angiography of the carotid arteries may easily demonstrate agenesis of the left common carotid artery, the diagnosis is difficult with color Doppler sonography. Sonograms may not satisfactorily depict the left-sided circulation, because a low or even intrathoracic location of the carotid bifurcation is possible in some cases.

In embryonic development, a pair of longitudinally directed channels arises in a paramedian location in the embryo on approximately the 19th day. These ultimately become the dorsal aortae. The ventral aortic sac connects to the dorsal aortae via the paired first aortic arches during the 21st to 25th days. Six pairs of aortic arches form, coursing around the five brachial arches by the 32nd day. The third arches are precursors of the carotid system, and the fourth arches develop asymmetrically. The right fourth arch, together with part of the right dorsal aorta, forms the proximal right subclavian artery. The left fourth arch remains continuous with the aortic sac and the left dorsal aorta to form the left aortic arch in postnatal life. The first and second arches substantially involute by the 29th day, and the dorsal aortae also regress between the third and fourth arches; this structure is called the ductus caroticus by the 6th week. The regression of these vascular segments leaves one predominant connection to the cranial region that courses from the ventral aortic sac through the third aortic arch to the cranial extension of the dorsal aorta. The combination of the ventral aortic sac, the third aortic arch, and the dorsal aorta rostral to the arch forms the common and internal carotid arteries. According to the most accepted view, if the ductus caroticus does not involute and if it persists into postnatal life, it forms a separate origin of the internal carotid artery, and this formation occurs in conjunction with involution of the third aortic arch that normally persists and becomes the common carotid artery and proximal internal carotid artery (1, 6).

The external carotid artery forms from a direct branch of the aortic sac, namely, the ventral pharyngeal artery. The rapid descent of the heart at around 40th day causes the origin of external carotid artery to migrate from the aortic sac for a variable distance along the third arch. Another theory about the development of independent origins of internal and external carotid arteries depends on a developmental failure that causes the external carotid artery to migrate laterally and join the internal carotid artery (1, 6).

The right-sided equivalent of the congenital vascular anomaly described here has also been reported in one case in the literature (7). The external carotid artery arises from the innominate artery, whereas the internal carotid artery arises from the subclavian artery proximal to the vertebral artery in such cases. The right-sided anomaly is briefly explained by the embryonic persistence of the right ductus caroticus that is associated with involution of the third aortic arch on the right side.

Agenesis of common carotid artery is usually asymptomatic unless it is associated with a coincidental arterial lesion. The reported congenital anomalies associated with agenesis of the common carotid artery include a cervical aortic arch, a double aortic arch, a right aortic arch, an aberrant right subclavian artery, a persistent trigeminal artery, and a persistent proatlantal intersegmental artery (1, 4, 6).

Our case could not be precisely evaluated with color Doppler sonography because of the difficulty in locating the left carotid bifurcation, although the characteristic wave patterns for the internal and external carotid arteries were both detected. MRA of the supra-aortic arteries was performed to determine if a low bifurcation of the left common carotid artery was present, and MRA of the intracranial arteries was performed to investigate any associated anomaly related to them. Other than agenesis of the left common carotid artery and the low bifurcation on the right-sided carotid system, the internal carotid artery

was smaller than the external carotid artery on the left side. Although the internal carotid artery is generally expected to be bigger than the external carotid artery, the opposite finding in our patient could have been related to 1) the persistence of a smaller ductus caroticus that formed the internal carotid artery or 2) the direct origin of the external carotid artery from the aortic sac, with the capacity to carry a large volume of blood. Because the clinical findings were unrelated to the presence of this congenital anomaly, further invasive and noninvasive studies were not needed, and a therapeutic regimen including antiplatelet drugs was started to treat transient ischemic attacks in the patient.

Conclusion

Agenesis of the left common carotid artery with independent origins of the internal and external carotid arteries directly from the aortic arch is an extremely rarely reported anomaly. Herein we presented MRA findings in such a case, which, to our

knowledge, have not been previously reported in the literature.

References

1. Lie TA. *Congenital anomalies of the carotid arteries: An angiographic study and a review of the literature*. Amsterdam: Excerpta Medica Foundation; 1968:30–35
2. Bryan RN, Drewyer RG, Gee W. **Separate origins of the left internal and external carotid arteries from the aorta**. *AJR Am J Roentgenol* 1978;130:362–365
3. Dahn MS, Kaurich JD, Brown FR. **Independent origins of the internal and external carotid arteries: a case report**. *Angiology* 1999;50:755–760
4. Rossitti S, Raininko R. **Absence of the common carotid artery in a patient with a persistent trigeminal artery variant**. *Clin Radiol* 2001;56:79–81
5. Woodruff WW III, Strunsky VP, Brown NJ. **Separate origins of the left internal and external carotid arteries directly from the aortic arch: duplex sonographic findings**. *J Ultrasound Med* 1995;14:867–869
6. Dungan DH, Heiserman JE. **The carotid artery: embryology, normal anatomy, and physiology**. *Neuroimaging Clin N Am* 1996;6:789–799
7. Jerius JT, Stevens SL, Freeman MB, Goldman MH. **Vertebrobasilar syndrome associated with subclavian origin of the right internal carotid artery**. *J Vasc Surg* 1995;21:855–861