

**Are your MRI contrast agents cost-effective?**  
Learn more about generic Gadolinium-Based Contrast Agents.



# AJNR

## Errata

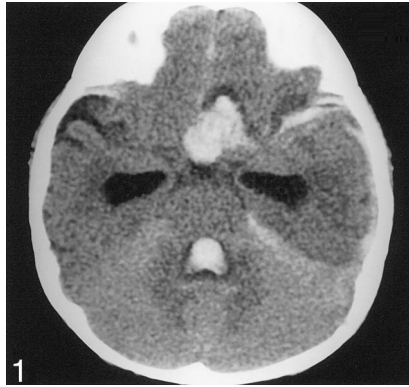
*AJNR Am J Neuroradiol* 2003, 24 (5) 1032  
<http://www.ajnr.org/content/24/5/1032.2>

This information is current as  
of April 23, 2024.

## Erratum

---

Case Report **Pediatric Intracranial Aneurysm: A Diagnostic Dilemma Solved with Contrast-Enhanced MR Imaging**, AJNR 24:370–372, March 2003. Figure 1 legend should read: Nonenhanced *axial* CT scan of the brain shows hydrocephalus and left anterior frontal lobe hematoma extending into the suprasellar cistern. The correct orientation of Figure 1 is shown below.



In the editorial **Building a Better Mousetrap: The Diagnosis of Metastatic Cervical Adenopathy**, Weissman JL, AJNR 24:297, March 2003, the following error occurred: In the third paragraph, the first sentence “CT and MR Imaging have improved on that rather dismal statistic by applying a variety of anatomic criteria (size, shape, attenuation, original intensity number) to differentiate normal from abnormal nodes” should read “CT and MR Imaging have improved on that rather dismal statistic by applying a variety of anatomic criteria (size, shape, attenuation, **signal intensity, number**) to differentiate normal from abnormal nodes.”