

Are your **MRI contrast agents** cost-effective?

Learn more about generic **Gadolinium-Based Contrast Agents**.



**FRESENIUS  
KABI**

caring for life

**AJNR**

**Standard Variants of the Skull and Brain:  
Atlas for Neurosurgeons and  
Neuroradiologists**

*AJNR Am J Neuroradiol* 2004, 25 (5) 901

<http://www.ajnr.org/content/25/5/901>

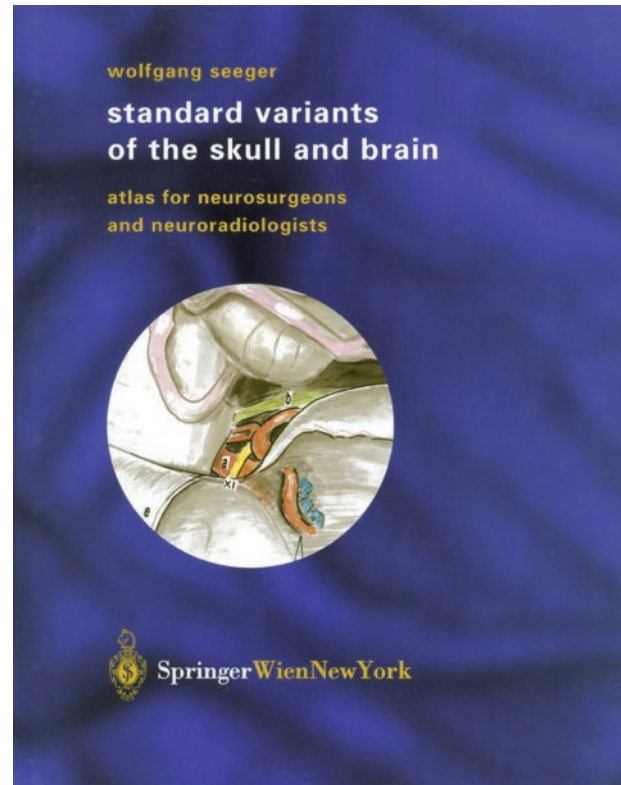
This information is current as  
of April 17, 2024.

**Standard Variants of the Skull and Brain: Atlas for Neurosurgeons and Neuroradiologists**  
Wolfgang Seeger. Vienna and New York: Springer-Verlag; October 2003. 371 pages, 177 illustrations. \$250.

Seeger's *Standard Variants of the Skull and Brain: Atlas for Neurosurgeons and Neuroradiologists* is a continuation of the author's previous impressive volume, *Neuronavigation and Neuroanatomy* (Wolfgang Seeger and Josef Zentner). This work, like many of the anatomic publications by Springer-Verlag, is a physically attractive atlas that uses clear, uncluttered illustrations printed on high-quality paper. The author taps into his vast clinical experience to highlight the most important anatomic variations that neurosurgeons are likely to encounter. As such, not every anatomic variation is listed or addressed, and the chosen anatomy itself is also not exhaustively detailed. Only relevant structures are demonstrated, and the pertinent relationships are emphasized. Variants are categorized into three groups according to frequency: rare (<10%), common (10–50%), and normal (>50%).

The book is organized into five main chapters, which are based upon surgical areas: 1) frontobasal–frontodorsal, 2) fronto-temporo-basal (pterional), 3) temporolateral and temporomedial, 4) parietal and occipital, and 5) infratentorial. Opening the book to any individual page reveals large illustrations occupying the entire right-hand page with the corresponding figure legends on the left-hand page. Narrative is nonexistent, conforming to the atlas format. The legends are brief and mostly limited to listings of the names associated with the labels on the illustrations. If the reader is looking for a substantive explanation or discussion of the anatomic nuances demonstrated, this atlas format would not be useful. Even the occasional comments on the clinical significance of some of the illustrated anatomic variations are for the most part limited to the immediate dangers during surgery. The short list of references can partially alleviate the desire for more discussion, but that list seems merely perfunctory because the main point of this book is for a highly experienced teacher and neurosurgeon to lead readers through specific anatomic points.

The minor errors of syntax that sporadically appear are probably related to the translation process. The illustrations appear to be mostly freehand sketches with light pastel colors added to highlight the pertinent structures. The images effectively demonstrate the author's desired anatomic teaching points, though the aesthetics of the images seem spare and simplistic



compared with the plethora of stunning medical/anatomic illustrations already in the marketplace. It should be noted, however, that an image with a powerful artistic impact is not necessarily a more effective one. The subdued artistic style of the illustrations in this book works well in demonstrating the desired anatomy, even though the surrounding anatomic environment may not be as detailed as some readers may want or expect.

In summary, this atlas will probably prove very useful for neurosurgeons at all levels of training. The author's experience and anatomic insights are invaluable. This book, however, is also being marketed to neuroradiologists. The effectiveness of this marketing strategy depends on the particular neuroradiologist and his or her priority for understanding the microsurgical anatomic challenges of the neurosurgeon with whom he or she collaborates.