

Are your **MRI contrast agents** cost-effective?

Learn more about generic **Gadolinium-Based Contrast Agents**.



**FRESENIUS  
KABI**

caring for life

**AJNR**

**Immediate Evaluation of Angioplasty and Stenting Results in Supra-Aortic Arteries by Use of a Doppler-Tipped Guidewire**

Nina Ghosh, Donatella Tampieri and Denis Melancon

*AJNR Am J Neuroradiol* 2004, 25 (7) 1172-1176

<http://www.ajnr.org/content/25/7/1172>

This information is current as of April 16, 2024.

## Immediate Evaluation of Angioplasty and Stenting Results in Supra-Aortic Arteries by Use of a Doppler-Tipped Guidewire

Nina Ghosh, Donatella Tampieri, and Denis Melancon

**Summary:** Intra-arterial Doppler sonography may complement arteriography by providing immediate physiological evidence of hemodynamic adequacy and by obviating unnecessary angioplastic dilation. We used a Doppler-tipped guidewire in 16 patients and obtained velocity measurements at the site of stenosis immediately before and after carotid artery stenting (CAS) in 10 patients. Intra-arterial Doppler sonography confirmed hemodynamic improvement immediately after stent placement and correlated well with post-CAS duplex Doppler sonography results. Thus, intra-arterial Doppler sonography can be feasibly incorporated into CAS procedures for hemodynamic evaluation and can provide anatomic information that complements information provided by angiography.

Although intra-arterial Doppler-tipped guidewires have been found to be accurate in measuring intra-arterial blood flow velocities in extra- and intracranial arteries and veins, the clinical application of Doppler guidewires in neuroradiology has been limited to only a few studies (1–4).

Carotid artery stenting (CAS) requires arteriography for immediate anatomic evaluation of the adequacy of dilation obtained after stenting but does not provide physiological measures of the resultant improvement in blood flow velocities (5). Reliance on an anatomic measure alone of CAS adequacy may result in dilation without adequate improvement in cerebral hemodynamics. Prolonged or excessive balloon inflation has been associated with cerebral hypoperfusion from luminal compromise, plaque dislodgment, and intimal dissection (6).

Use of a Doppler-tipped guidewire as a means of evaluating blood flow velocities during the stent placement procedure may obviate unnecessary angioplastic dilation or provide physiological evidence of hemodynamic adequacy. Our goal was to determine whether the Doppler-tipped guidewire can safely be used for immediate evaluation of CAS and to evalu-

ate the relationship between blood flow velocities as measured with intra-arterial and duplex Doppler sonography and the degree of stenosis estimated on the basis of angiographic studies.

### Methods

The intra-arterial system used consists of a 0.014-inch Doppler-tipped guidewire (Flowire; Cardiometrics, Mountain View, CA) with a piezoelectric transducer operating at 12 MHz mounted at its distal end. The proximal end of the wire is connected to a spectral wave analyzer that displays the pulsed Doppler signal.

Sixteen patients (nine men and seven women) with symptomatic carotid stenosis shown by an external duplex color Doppler device were examined. When the symptomatic stenotic vessel was entered by using the regular femoral approach, an angiographic study was performed, and the Flowire was navigated in the catheter to the site of the stenosis. Blood flow velocities were recorded proximal to, distal to, and at the level of stenosis. After angioplasty and stent placement, the Flowire was reinserted to obtain flow measurements at the level of stenosis. Patients underwent color and spectral Doppler sonography 24 hours, 1 month, 3 months, 6 months, and 1 year after the stent placement procedure.

Percentage of pre- and post-stent stenosis as seen on the angiograms were estimated during the procedure and confirmed by using the North American Symptomatic Carotid Endarterectomy Trial method after the procedure (6, 14), specifically by using the following equation:  $\% = [1 - (d_{\text{stenosis}} / d_{\text{normal}})] \times 100$ , where  $d_{\text{stenosis}}$  = diameter of the internal carotid artery at the site of the most severe stenosis and  $d_{\text{normal}}$  = diameter of the proximal normal common artery. The same approach was used for post-stent measurements, for which the numerator was the diameter of the stent at the internal carotid artery that was judged to be the smallest. The measurements were obtained 90 degrees to the arterial wall. Measurements were obtained on three separate occasions by using three separate images of the same vessels. The average of the three results was calculated. All measurements were made by the primary author (N.G.).

### Results

Full data are presented in tabulated form (Table). For four of 16 patients, it was not possible to advance the Doppler-tipped guidewire past the level of the stenosis, and velocity measurements could not be obtained with that system. In one patient, the angioplasty procedure was not performed because of induction of a severe vasovagal response. In the remaining patient, the immediate pre- and post-stent peak systolic velocities were recorded by using the intra-arterial Doppler-tipped guidewire system.

Received August 11, 2003; accepted after revision January 5, 2004.

From the Montreal Neurological Hospital, Montreal, Quebec, Canada.

Address reprint requests to Donatella Tampieri, MD, Head, Diagnostic and Interventional Neuroradiology Divisions, Montreal Neurological Hospital, McGill University Health Centre, 3801 University Street, Montreal, Quebec, H3A 2B4 Canada.

© American Society of Neuroradiology

## Pre- and post-stent angiography, intra-arterial Doppler ultrasonography, and duplex Doppler ultrasonography data

Patient No.	Pre-stent Angiogram % Stenosis	Post-stent Angiogram % Stenosis	Pre-stent IAD PSV (cm/s)	Post-stent IAD PSV (cm/s)	Pre-stent Duplex PSV (cm/s)	Post-stent Duplex PSV (cm/s)
1	73	50	320	180	450	200
2	89	42	ITA	100	400	160
3	80	54	160	60	N/A	140
4	88	33	ITA	60	250	90
5	81	27	240	80	N/A	60
6	92	54	ITA	60	250	90
7	90	25	ITA	120	N/A	110
8	71	20	180	60	N/A	60
9	80	NP	350	NP	N/A	N/A
10	78	33	120	90	170	110
11	75	43	240	60	300	60
12	80	N/A	100	60	N/A	60
13	89	34	250	120	N/A	250
14	94	62	250	120	250	85
15	70	46	320	120	N/A	N/A
16	81	53	160	60	275	60

Note.—IAD indicates intra-arterial Doppler sonography; PSV, peak systolic velocity; ITA, impossible to advance past stenosis; NA, not available; NP, angioplasty not performed because of patient's vasovagal response.

The pre-stent peak systolic velocities obtained by using the intra-arterial Doppler-tipped guidewire system were markedly greater compared with the peak systolic velocities obtained after stent placement, with an average difference of approximately 120 cm/s. This difference suggests that the stent placement procedure resulted in significant relief of stenosis and recuperation of blood flow. Similarly, pre-stent measurement of peak systolic velocities were recorded by using conventional duplex Doppler sonography on the same day of the procedure in eight patients; in 14 patients, same-day post-stent duplex Doppler peak systolic velocities were recorded. As with the intra-arterial Doppler-tipped guidewire system, the pre-stent velocities recorded by using duplex Doppler sonography were significantly greater than those recorded after the stent placement procedure (average pre-stent/post-stent difference of 204 cm/s). When comparing the intra-arterial Doppler-tipped guidewire system and duplex Doppler sonography results, good correlation was observed between peak systolic velocity measurements obtained after stent placement ( $r = 0.70$ ;  $P < .01$ ). Both methods show resolution of peak systolic velocities to "normal" values in nine patients (56%) after stent placement (Table, Fig 2).

For the 10 CAS procedures for which intra-arterial Doppler peak systolic velocity measurements were obtained, several angiographic studies were conducted both immediately before and immediately after the CAS procedures (Table, Patients 1, 3, 5, 8, 10, 11, 13, 14, 15, and 16). In all 10 cases, the post-stent angiographic results indicated resolution of stenosis to moderate (30–69%) or low (<30%) grade levels after the angioplasty and stent placement procedure. [However, below approximately 54% stenosis achieved after stent placement, peak systolic velocities achieved by using the intra-arterial Doppler-tipped guidewire system and duplex Doppler sonog-

raphy did not improve considerably.] For example, the intra-arterial Doppler-tipped guidewire system peak systolic velocity values for patients 3, 4, 5, 6, 8, 11, and 16 were all between 60 and 80 cm/s, even though post-CAS stenosis values were 54%, 33%, 27%, 54%, 20%, 43%, and 53%, respectively. Furthermore, peak systolic velocities remained above 100 cm/s in patients 1, 13, and 15 even though measured percent stenosis achieved in these patients was below 54%. This observation suggests that dilation of the stent above a certain point does not result in any significant increase in blood flow. No neurologic complications occurred during the procedures.

## Discussion

Patients with unstable angina and those with contralateral carotid artery occlusion, restenosis, or radiation-induced stenosis represent specific patient populations for whom CAS offers a potential alternative to carotid endarterectomy (11, 12). Doppler guidewire-measured intravascular blood flow velocities after CAS have been shown to closely correspond with velocities obtained by using external duplex Doppler sonography in both animal models (1, 2) and preliminary studies of patients undergoing endovascular carotid angioplasty (3). The intra-arterial Doppler-tipped guidewire system offers the advantage of intra-procedural physiological measurements, and therefore the opportunity to make any hemodynamically based adjustments during the procedure. In addition, the system is less affected by inaccuracies introduced as a result of interference of sonographic penetration by endovascular prostheses such as stents (13).

Our results show that the intra-arterial Doppler-tipped guidewire system can be used for immediate evaluation of angioplasty and stent placement of stenotic carotid arteries. Pre-stent peak systolic velocity measurements at the tightest stenosis could be obtained

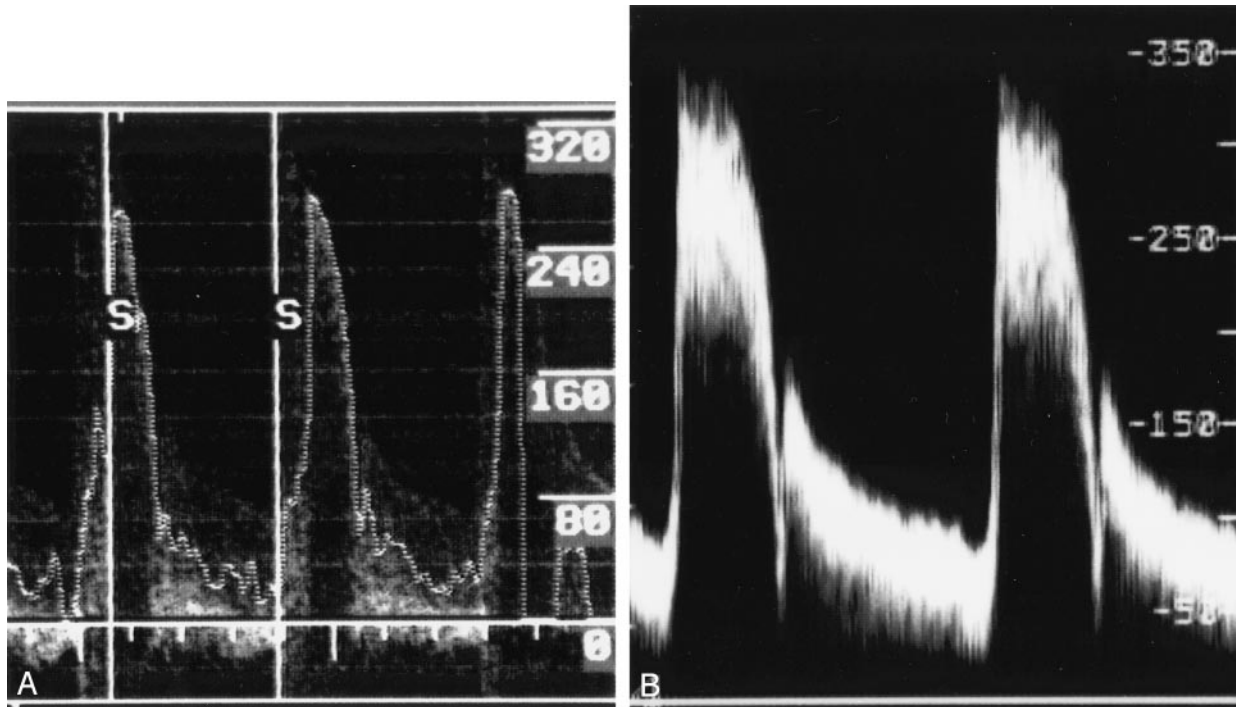
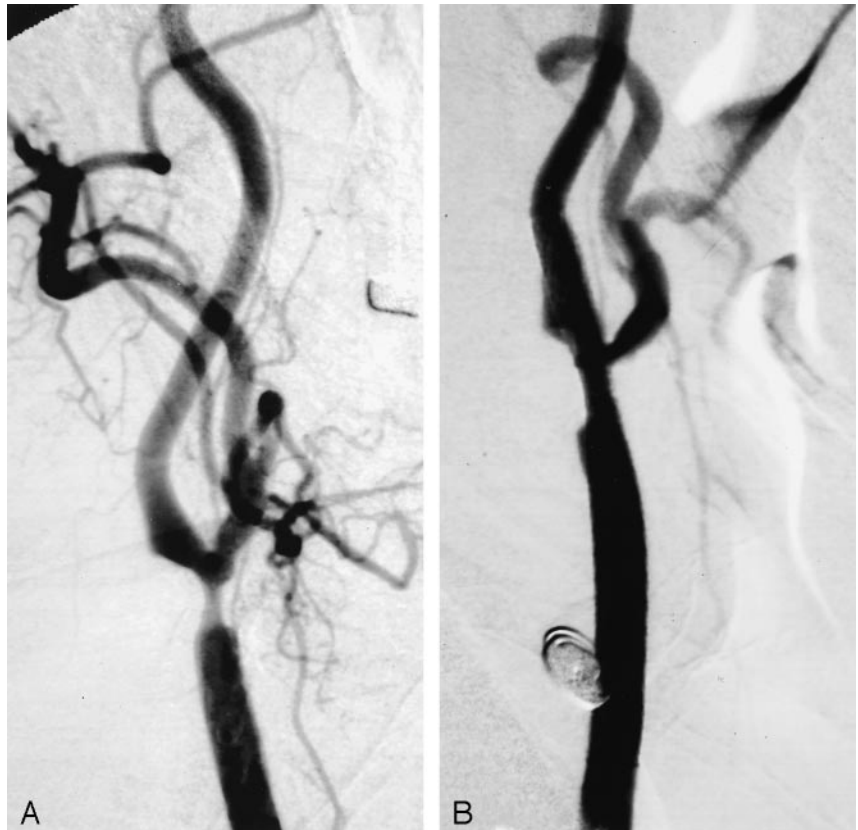

FIG 1. Examples of Doppler spectra. Velocities are measured in cm/s.  
 A, Intra-arterial Doppler-tipped guidewire spectra obtained immediately before the stent placement procedure.  
 B, Duplex color Doppler sonography spectra obtained 2 hours before stent placement.

FIG 2. Angiograms of the patient whose spectra are shown in Figure 1.  
 A, Before angioplasty of >80% stenosis of the right carotid artery.  
 B, After the procedure, successful angioplasty and stent placement can be seen.



in all except four patients for whom the extent of stenosis precluded the advancement of the Doppler-tipped guidewire past the stenosis. As expected, peak systolic velocities at the tightest level of stenosis decreased sig-

nificantly with angioplasty and stent placement in all patients. The system thus provided real-time physiological confirmation of recuperation of blood flow after stent placement.

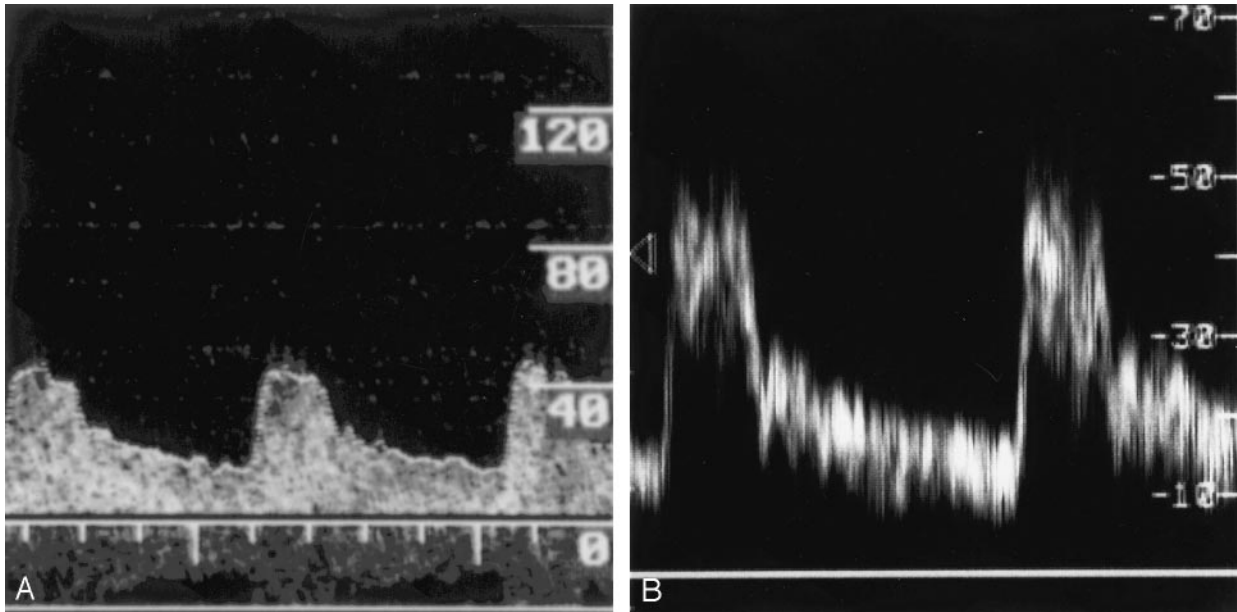


FIG 3. Examples of Doppler spectra. Velocities are measured in cm/s.  
 A, Intra-arterial Doppler-tipped guidewire spectra obtained immediately after the stent placement procedure.  
 B, Duplex color Doppler sonography spectra obtained 2 hours after stent placement.

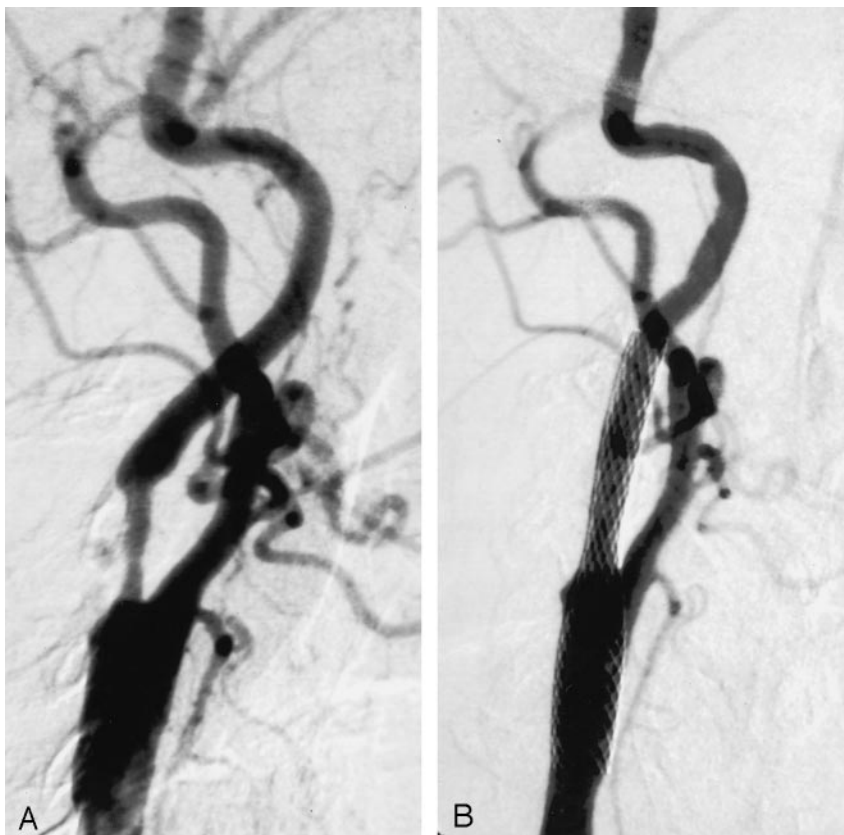


FIG 4. Angiograms of the patient whose spectra are shown in Figure 3.

A, Before angioplasty of >80% stenosis of the right carotid artery.

B, After the procedure, successful angioplasty and stent placement can be seen.

As assessed by the intra-arterial Doppler-tipped guidewire system, 10 patients attained velocities within normal ranges for adequate blood flow. Among these same patients, however, the degree of post-stent dilation achieved as assessed by using post-stent angiography resulted in stenoses ranging from 20% (low grade) to 54% (moderate grade). These

results indicate that below a certain level of stenosis, no clinically significant improvement occurs in blood flow. Thus, below approximately 50% stenosis, it may be unnecessary to dilate as long as peak systolic velocity has decreased to normal levels. Despite the wide range of angiographic results for these patients, no difference in the rates of neurologic complications

occurred after stent placement. These results provided some insight into the observation that no benefit has been shown of procedures such as carotid endarterectomy for patients with stenosis of <50% (12). That is, below this level of stenosis, blood flow is sufficient to avoid neurologic sequelae.

Ringer et al (11) and Yoshida et al (13) showed that the use of carotid duplex Doppler sonography for follow-up of carotid arteries may be less reliable after stent placement than before stent placement. Altered arterial wall compliance or stent interference with Doppler signaling may reduce the accuracy of Doppler sonography after stent placement, resulting in a significant number of falsely positive stenoses (11). The intra-arterial Doppler-tipped guidewire system may be less subject to the effects of signal interference caused by stent placement, because the Doppler-tipped guidewire is in direct contact with blood. This may be reflected in the generally lower post-stent peak systolic velocity values obtained by using the system (Table) and may indicate a way of reducing false-positive results after stent placement.

Further studies need to be conducted on a greater sample size to accurately assess the validity of the intra-arterial Doppler-tipped guidewire system for evaluation of CAS success. Importantly, it must be established whether a threshold peak systolic velocity range exists as measured by the system, below which one can reliably predict no further benefit from dilation at the level of stenosis. The importance of improvement in blood flow velocities before and after stent placement compared with absolute blood flow velocities also must be determined. If improvement is more important, the use of the intra-arterial Doppler-tipped guidewire system may be limited to cases in which the degree of pre-stent stenosis does not preclude advancement of the Doppler-tipped guidewire.

### Conclusion

On the basis of our preliminary results, we find that the intra-arterial Doppler-tipped guidewire system is a feasible method of evaluating the immediate results of CAS. Except when near-occlusive stenosis precludes the advancement of the Doppler-tipped guidewire, the technique is easily incorporated during the CAS procedure and adds minimal time and no complications. Although more experience is needed, a reasonable correlation seems to exist between post-stent peak systolic velocity levels as measured by the intra-arterial Doppler-tipped guidewire system and those measured by duplex Doppler sonography. The intra-arterial Doppler-tipped guidewire system can therefore be useful in showing the adequacy blood

flow velocities achieved by the stent placement procedure. The system may in turn help circumvent unnecessary, potentially harmful over-dilation during the CAS procedure. The generally lower peak systolic velocities shown by the intra-arterial Doppler-tipped guidewire system, as compared with duplex Doppler sonography, may indicate that the system is less subject to sonographic interference produced by the stent. The intra-arterial Doppler-tipped guidewire system is limited in that it may be difficult to advance the Doppler-tipped guidewire past levels of tight stenosis. This may have important implications if relative improvement in peak systolic velocities is more indicative of successful CAS than the final post-stent peak systolic velocity value. More research is needed to determine the prognostic importance of physiological measurements obtained by using the system versus the anatomic measurements obtained by using post-procedural angiography.

### References

1. Chaloupka JC, Viñuela F, Malanum RP, et al. **Technical feasibility and performance studies of a Doppler guide wire for potential neuroendovascular applications.** *AJNR Am J Neuroradiol* 1994;15:503-507
2. Chaloupka JC, Viñuela F, Kimme-Smith C, Robert J, Duckwiler GR. **Use of a Doppler guide wire for intravascular blood flow measurements: a validation study for potential neurologic endovascular applications.** *AJNR Am J Neuroradiol* 1994;15:509-517
3. Benndorf G, Singel S, Proest G, Lanksch W, Felix R. **The Doppler guide wire: clinical applications in neuroendovascular treatment.** *Neuroradiology* 1997;39:286-291
4. Benndorf G, Wellenhofer E, Lanksch W, Felix R. **Intraaneurysmal flow: evaluation with Doppler guidewires.** *AJNR Am J Neuroradiol* 1996;17:1333-1337
5. Willinsky RA, Taylor SM, TerBrugge K, Farb RI, Tomlinson G, Montanera W. **Neurological complications of cerebral angiography: prospective analysis of 2,899 procedures and review of the literature.** *Radiology* 2003;227:522-528
6. Phatouros CC, Higashida RT, Malek AM, et al. **Carotid artery stent placement for atherosclerotic disease: rationale, technique, and current status.** *Radiology* 2000;217:26-41
7. Young G, Humphrey P. **Measuring carotid stenosis.** *J Neurol Neurosurg Psychiatry* 2003;74:140-141
8. Hwang CS, Liao KM, Lee JH, Tegeler CH. **Measurement of carotid stenosis: comparisons between duplex and different angiographic grading methods.** *J Neuroimaging* 2003;13:133-139
9. Baumgartner RW, Mattle HP, Schroth G. **Assessment of  $\geq 50\%$  and <50% intracranial stenoses by transcranial color-coded duplex sonography.** *Stroke* 1999;30:87-92
10. Alexandrov AV. **Ultrasound and angiography in the selection of patients for carotid endarterectomy.** *Curr Cardiol Rep* 2003;5:141-147
11. Ringer AJ, German JW, Guterman LR, Hopkins LN. **Follow-up of stented carotid arteries by Doppler ultrasound.** *Neurosurgery* 2002;51:639-643
12. Chaturvedi S, Fessler R. **Angioplasty and stenting for stroke prevention: good questions that need answers.** *Neurology* 2002;59:664-668
13. Yoshida K, Nozaki K, Kikuta K, Sadato A, Miyamoto S, Hashimoto N. **Contrast-enhanced carotid color-coded duplex sonography for carotid stenting follow-up assessment.** *AJNR Am J Neuroradiol* 2003;24:992-995