

Are your **MRI contrast agents** cost-effective?

Learn more about generic **Gadolinium-Based Contrast Agents**.



**FRESENIUS
KABI**

caring for life

AJNR

**Unilateral Transpedicular Course of an
Ascending Lumbar Vein through a Pedicular
Foramen Mimicking a Lytic Lesion: An
Anatomic Variant**

Musturay Karcaaltincaba and Deniz Akata

This information is current as
of April 19, 2024.

AJNR Am J Neuroradiol 2004, 25 (9) 1597-1598
<http://www.ajnr.org/content/25/9/1597>

Unilateral Transpedicular Course of an Ascending Lumbar Vein through a Pedicular Foramen Mimicking a Lytic Lesion: An Anatomic Variant

Musturay Karcaaltincaba and Deniz Akata

Summary: An ascending lumbar vein passing through a foramen on the right pedicle of the third lumbar vertebra unilaterally, which was diagnosed incidentally during virtual CT colonoscopy of a patient with a rectal tumor, is described. Recognition of this anatomic variation is important to avoid diagnostic misinterpretations and transpedicular interventions such as percutaneous vertebroplasty or surgical instrumentation that may result in excessive hemorrhage and inadvertent leak of cement when it is present.

The ascending lumbar vein is normally located between the psoas major and roots of the lumbar transverse processes (1). We describe the course of a right ascending lumbar vein through a unilateral foramen located on the right pedicle of the third lumbar vertebra (L3). This anatomic variation may have important clinical implications. We could not find a similar anatomic variant through an extensive literature search (2–9).

Case Report

A 46-year-old man presented with hematochezia and was found to have a rectal tumor on rectal examination. He subsequently underwent virtual CT colonoscopy to define the extent and search for coexisting colonic lesions and metastases. Virtual CT colonoscopy was obtained by a four-channel multidetector CT scanner (Siemens volume zoom, Siemens Medical Systems, Munich, Germany) by using 3-mm section thickness and a 15-mm reconstruction index after insufflation of rectal air and intravenous contrast medium administration. A lytic lesion with sclerotic margin on the right pedicle of L3 was noted on axial CT scans (Fig 1A). Upon evaluation of sequential scans, the presence of a foramen mimicking a lytic lesion was recognized, and a right lumbar vein was passing through this pedicular foramen with a paravertebral course at other lumbar levels. It is interesting to note that the left lumbar vein had a normal anatomic course between the psoas major and the lumbar vertebrae. We reconstructed sagittal and coronal images and 3D volume-rendered images from axial scans (Fig 1B–D) at a distant workstation (Leonardo, Siemens Medical Systems). The transpedicular course of the right ascending lumbar vein was visible on multiplanar reformatted scans; however, it was less well appreciated on these scans compared with

axial scans and volume-rendered scans (Fig 1). Axial and coronal volume-rendered scans confirmed the presence of the foramen containing an ascending lumbar vein (Fig 1C and D).

Discussion

Ascending lumbar veins normally course in a paravertebral location between lumbar vertebrae and psoas muscle on each side. Superiorly they usually join the subcostal vein and, passing deep to the diaphragmatic crus, ascend as the azygos vein on the right and as the hemiazygos on the left (1). The ascending lumbar vein is considered a derivative of a precostal or lumbocostal venous system located between the vertebrocostal element and supracardinal vein during embryologic development (1). In this report, we describe the unilateral course of an ascending lumbar vein through a pedicular foramen of L3 with a normal paravertebral course at other lumbar vertebrae levels. The contralateral lumbar vein had a normal course. We considered this finding as an anatomic variation of pedicle morphologic features.

Although this anatomic variant was recognized on axial CT scans, it would be difficult to detect this foramen on direct roentgenograms or on fluoroscopic images. Moreover, it might be diagnosed as a lesion on the basis of unenhanced CT and MR imaging findings, especially during evaluation of nonsequential images obtained for studies of lumbar disks. Our patient had a rectal tumor, and this lesion might have been interpreted as a suspect lesion for bone metastasis.

With the recent increase in use of transpedicular approach by interventional radiologists for percutaneous vertebroplasty (10), anatomic and morphologic features of vertebrae pedicles gain importance in preoperative evaluation. Insertion of a needle through a pedicle containing an ascending lumbar vein might result in excessive hemorrhage and cement leak and may end up with massive pulmonary thromboembolism. Therefore, preoperative CT scanning for fluoroscopically guided procedures or CT-guided procedures can be performed, which have already been used routinely at some centers.

Conclusion

Transpedicular course of an ascending lumbar vein can occur and should be known by radiologists and

Received January 2, 2004; accepted after revision January 29.

From the Department of Radiology, Hacettepe University School of Medicine, Ankara, Turkey.

Address correspondence to Musturay Karcaaltincaba, MD, Department of Radiology, Hacettepe University School of Medicine, Sıhhiye Ankara 06100, Turkey.

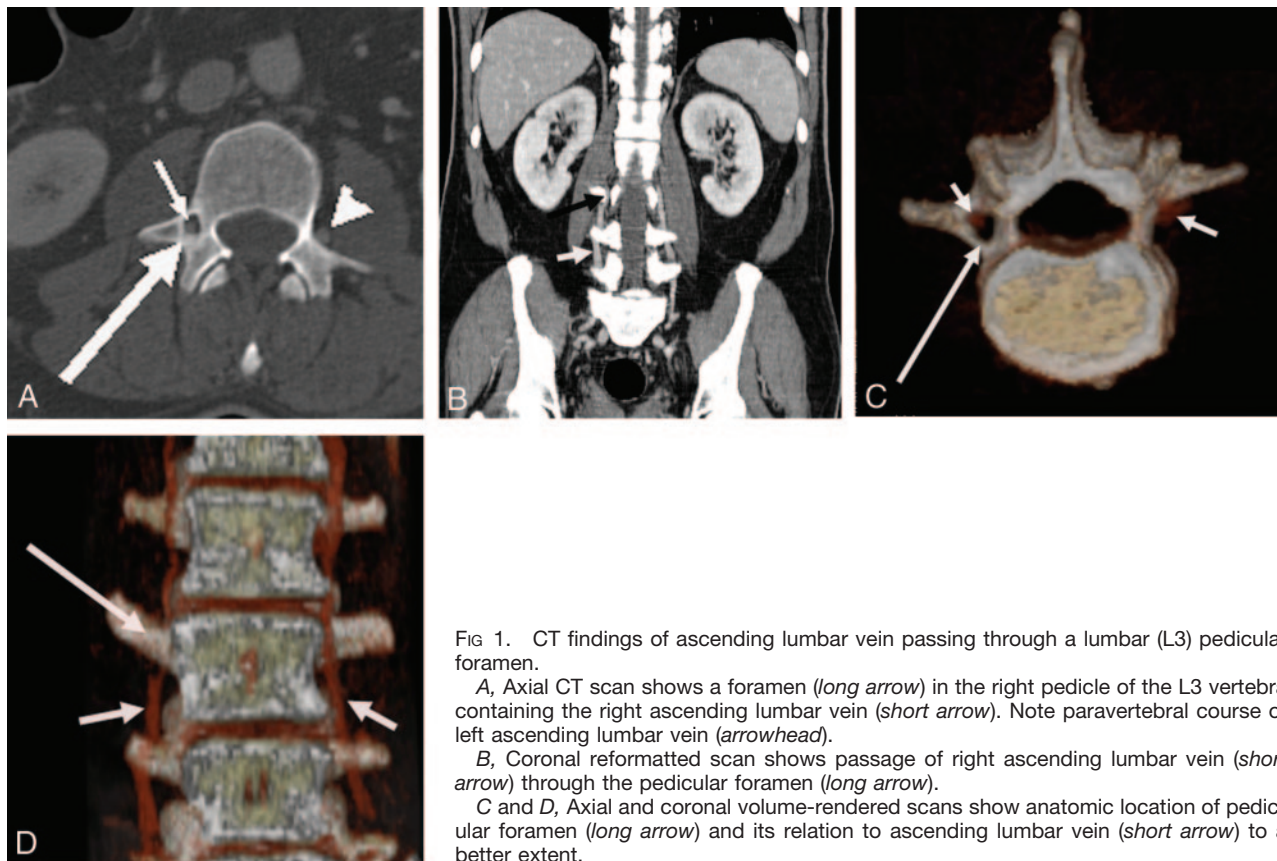


FIG 1. CT findings of ascending lumbar vein passing through a lumbar (L3) pedicular foramen.

A, Axial CT scan shows a foramen (*long arrow*) in the right pedicle of the L3 vertebra containing the right ascending lumbar vein (*short arrow*). Note paravertebral course of left ascending lumbar vein (*arrowhead*).

B, Coronal reformatted scan shows passage of right ascending lumbar vein (*short arrow*) through the pedicular foramen (*long arrow*).

C and D, Axial and coronal volume-rendered scans show anatomic location of pedicular foramen (*long arrow*) and its relation to ascending lumbar vein (*short arrow*) to a better extent.

surgeons to avoid diagnostic misinterpretations and potential complications that may arise during or after transpedicular interventions.

References

- Williams PL, Warwick R, Dyson M, Bannister LH, eds. *Gray's Anatomy*. 37th ed. London: Churchill Livingstone;1989:818
- Patel NP, Kumar R, Kinkhabwala M, Wengrover S. **Radiology of lumbar vertebral pedicles: variants, anomalies and pathologic conditions.** *Radiographics* 1987;7:101-137
- Patel NP, Kumar R, Kinkhabwala M, Wengrover SI. **Lumbar vertebral pedicles: radiologic anatomy and pathology.** *Crit Rev Diagn Imaging* 1988;28:75-132
- Helms CA, Vogler JB 3d, Hardy DC. **CT of the lumbar spine: normal variants and pitfalls.** *Radiograph* 1987;7:447-463
- Dorwart RH. **Computed tomography of the lumbar spine: techniques, normal anatomy, pitfalls, and clinical applications.** *Crit Rev Diagn Imaging* 1984;22:1-42
- Renfrew DL, Whitten CG, Wiese JA, et al. **CT-guided percutaneous transpedicular biopsy of the spine.** *Radiology* 1991;180:574-576
- Wortzman G, Steinhardt MI. **Congenitally absent lumbar pedicle: a reappraisal.** *Radiology* 1984;152:713-718
- Keats T. *Atlas of Normal Roentgen Variants that may Simulate Disease*. 5th ed. St Louis: Mosby Year Book;1989
- Schnitzlein HN, Murtagh FR. *Imaging Anatomy of the Head and Spine: a Photographic Color Atlas of MRI, CT, Gross and Macroscopic Anatomy in Axial, Coronal and Sagittal Planes*. 2nd ed. Baltimore: Urban and Schwarzenberg;1990
- Mathis JM, Barr JD, Belkoff SM, et al. **Percutaneous vertebroplasty: a developing standard of care for vertebral compression fractures.** *AJNR Am J Neuroradiol* 2001;22:373-381