

Are your MRI contrast agents cost-effective?

Learn more about generic Gadolinium-Based Contrast Agents.



AJNR

**Differences in Functional MR Imaging
Activation Patterns Associated with
Confrontation Naming and Responsive
Naming**

Sarah Tomaszewki Farias, Gregory Harrington, Catherine
Broomand and Maysud Seyal

This information is current as
of April 19, 2024.

AJNR Am J Neuroradiol 2005, 26 (10) 2492-2499
<http://www.ajnr.org/content/26/10/2492>

Differences in Functional MR Imaging Activation Patterns Associated with Confrontation Naming and Responsive Naming

Sarah Tomaszewski Farias, Gregory Harrington, Catherine Broomand, and Maysud Seyal

BACKGROUND AND PURPOSE: Direct cortical stimulation studies suggest that responsive naming is more widely distributed within the temporal lobe than confrontation naming and involves anterior temporal regions typically resected in a standard temporal lobectomy. The aim of the current study was to further demonstrate the anatomic dissociation between confrontation and responsive naming by using functional MR imaging (fMRI).

METHODS: Twenty participants underwent fMRI while performing either a confrontation or responsive naming task. Regions of interest were identified within the anterior and posterior temporal lobe.

RESULTS: Responsive naming produced more activation than confrontation naming within the dominant temporal lobe, with activation extending into the temporal pole. Activation in the dominant temporal lobe associated with responsive naming was observed in the superior, middle, and inferior temporal gyri but was limited to the middle temporal gyrus for confrontation naming. Although both naming tasks produced activation within the posterior temporal region of interest in all participants, responsive and confrontation naming produced activation within the anterior temporal region of interest in 90% versus 60% of the sample, respectively. Areas of the dominant hemisphere activated by both tasks included parts of the middle occipital and middle temporal gyri, inferior frontal lobe, and hippocampus, among others.

CONCLUSION: Findings are consistent with cortical stimulation studies and suggest that responsive naming produces more widespread activation within the temporal lobe compared with confrontation naming. The activation more often included anterior temporal regions during responsive naming as compared with confrontation naming. In clinical cases where the functional assessment of the temporal lobe—particularly the anterior regions—is important, the current results suggest responsive naming should be a useful fMRI paradigm and may ultimately help predict the risk of postsurgical language changes.

Word finding is typically measured by using confrontation naming in which a person is required to generate the name of visually presented pictures of objects. An alternate approach requires individuals to generate an object name in response to a verbal definition; this type of task has been referred to as auditory responsive naming or just responsive naming. There is evidence that responsive naming is more

sensitive to the word-finding problems associated with temporal lobe epilepsy (TLE) of the dominant hemisphere than confrontation naming (1).

Cortical stimulation studies in patients with epilepsy have suggested that there is some anatomic dissociation between areas in the dominant temporal lobe involved in confrontation and responsive naming (2, 3). Both Malow et al (2) and Hamberger et al (3) found that stimulation of anterior lateral temporal cortex disrupted responsive naming, whereas confrontation naming was rarely disrupted by stimulation of areas in this region. In contrast, stimulation of sites in the posterior region of the dominant temporal lobe most often disrupted both responsive and confrontation naming. Such findings support a degree of anatomic dissociation between responsive and confrontation naming that may reflect modality-specific processing.

Individuals with a left hemisphere epileptic focus,

Received February 22, 2005; accepted after revision May 13.

From the Departments of Neurology (S.T.F., C.B., M.S.) and Radiology (G.H.), University of California, Davis, Sacramento, CA.

Presented in part as a poster at the 58th annual meeting of the American Epilepsy Society, December 3–8, 2004, New Orleans, LA.

Address correspondence to Sarah Tomaszewski Farias, PhD, Department of Neurology, University of California, Davis, 4860 Y Street, Suite 3700, Sacramento, CA 95817.

particularly those with a history of an early brain insult, however, are more likely to have abnormal language organization (4, 5). Thus, inferring typical brain organization from patients who are known to be at risk for abnormal organization is problematic.

Functional MR imaging (fMRI) is another approach that has been used to map functional brain topography with high spatial and temporal resolution (6–12). It uses blood oxygen level–dependent signal intensity changes to map cortical areas, which are activated during a specific task compared with a baseline task (13). It has the advantage of being a completely noninvasive technique that can be used with healthy controls. In recent years, fMRI-based assessment of language laterality and localization has been increasingly used in patients who will be undergoing resection of a cortical lesion or seizure focus (14).

Adequate functional assessment of the dominant temporal lobe (including anterior regions) is important when it is the possible target of a surgical resection. This is the case in a standard temporal lobectomy, in which the anterior two thirds of the temporal lobe, including a large area of lateral cortex, is resected (15, 16). Thus, the identification of tasks that are both disrupted by direct cortical stimulation of anterior temporal cortex and associated with fMRI activation of this region in healthy individuals will likely have important clinical applications in terms of surgical planning and predicting the risk for postsurgical language changes.

The aim of this study was to attempt to replicate the cortical mapping studies comparing confrontation naming and responsive naming in healthy individuals by using fMRI. On the basis of previous studies, it was hypothesized that responsive naming would produce temporal activation to a greater extent and would more often include activation of anterior temporal regions than confrontation naming.

Methods

Participants. Participants in this study included 20 healthy right-handers. They were recruited from a variety of sources, including undergraduate college courses and through word of mouth at a medical center. The study was approved by the local institutional review board, and all participants gave appropriate consent. Ten subjects completed the responsive naming task and 10 completed the confrontation naming task. Because confrontation naming was part of a larger fMRI study protocol and responsive naming was added later in the project, only 2 of the subjects completed both naming tasks. The individual data for these 2 subjects are presented separately in the Results section. Within the sample of 10 subjects who completed the responsive naming task, the mean age of the sample was 36.2 years ($SD = 7.6$ years), with a range of 28–49 years. Within the sample that completed the confrontation naming task, the average age was 39.5 years ($SD = 9.3$ years), with a range of 28–52 years. The groups were matched for sex distribution; in both groups, 80% of the subjects were women.

Imaging Tasks. All tasks were block-design paradigms with active blocks of varying durations lasting 12–30 seconds alternating with baseline blocks of similar durations. The total time for each paradigm was 6 minutes 32 seconds. The visual stimuli were projected through an LCD projector (XG-G20XU; Sharp Electronics, Mahwah, NJ) outside the scanning room to a

screen located at the end of the scanner bed by using Presentation software (www.neurobs.com). The subject viewed the screen via a mirror on top of the head coil, and special MR imaging–compatible headphones (Resonance Technologies, Northridge, CA) were used to transmit the auditory stimuli. The subject's head was restrained with a moldable air bag (Vac-Fix-Bionix, Toledo, OH) to help reduce head motion.

For the confrontation naming task, subjects viewed line drawings from the Boston Naming Test (17) every 3 seconds and were instructed to name covertly the object pictured. The baseline condition consisted of the presentation of sets of vertical, horizontal, diagonal, and crossing lines to control for low-level visual perception. Subjects were instructed to attend closely to these images but not to respond in any way. For the experimental condition of the responsive naming task, subjects heard short definitions of various nouns and had to name the object covertly. Items from Hamberger and Seidel's Auditory Naming Test were used (18). For example, subjects heard a short definition, such as "an instrument you beat with sticks," and had to generate the word "drum" covertly. The baseline condition consisted of short phrases of the same duration as the definitions presented in the experimental condition but played backward, to control for low-level auditory perception. Behavioral data were collected outside the scanner by using an alternate form of the responsive naming tasks. All subjects achieved a high degree of accuracy (correctly naming approximately 97% of the items). These results are similar to published norms for this task (18). Behavioral data were not collected for the confrontation naming task. The stimuli, however, were taken from the Boston Naming Tests; published normative data for this test for subjects of similar age (by using the group mean age) indicate that 93% of all stimuli are typically named correctly (19).

Imaging. For the functional images, 21 contiguous 5-mm axial sections were acquired with a gradient echo, echo-planar imaging sequence (TR, 2 seconds; TE, 50 msec; flip angle, 90°; field of view [FOV], 22 cm; 64 × 64 matrix) by using a 1.5T GE Signa NV/I MR imaging system (GE Medical Systems, Milwaukee, WI). Each functional acquisition run contained 196 image volumes, and the first 4 image volumes were removed. A 3D T1-weighted image was acquired by using a fast SGPR sequence (TR, 8.7 msec; TE, 1.8 msec; flip angle, 15°; FOV, 22 cm; 256 × 256 matrix; section thickness, 1.2 mm; bandwidth, 15.63 kHz) for anatomic reference.

Analysis. The echo-planar images were reconstructed by using standard Fourier transformation combined with image-phase correction to reduce the $N/2$ ghost artifact (20). The images were then motion corrected with a 3D registration algorithm (21), and the statistical analysis was performed with analysis of functional neuroimages (22).

Statistical maps were generated through a multiple regression algorithm by using a boxcar (6-second lag) reference waveform with linear trends included as covariates. Activation maps were created by using a combination of a P value threshold ($P < .001$) generated from the regression statistics and a minimum cluster size (23, 24) to achieve a significance level $< .05$ by using AlphaSim (22). The statistical maps were transformed to Talairach coordinates by using a transformation derived from the 3D anatomic dataset (25). Regions of interest were hand drawn according to Talairach coordinates for the anterior and posterior temporal lobe of the left hemisphere (26). Figure 1 depicts the anterior and posterior regions of interest. The anterior temporal region of interest was a small region of interest covering the entire lobe anterior to the Talairach coordinate $y = -20$ and the posterior temporal region of interest covered the area in the temporal lobe posterior to $y = -20$. The posterior border of the anterior temporal region of interest at the most superior location is 5 cm from the anterior pole, and the posterior border at a point midway from the inferior and superior borders is approximately 4.1 cm from the anterior pole (15, 16) (this is approximately the cutoff used in

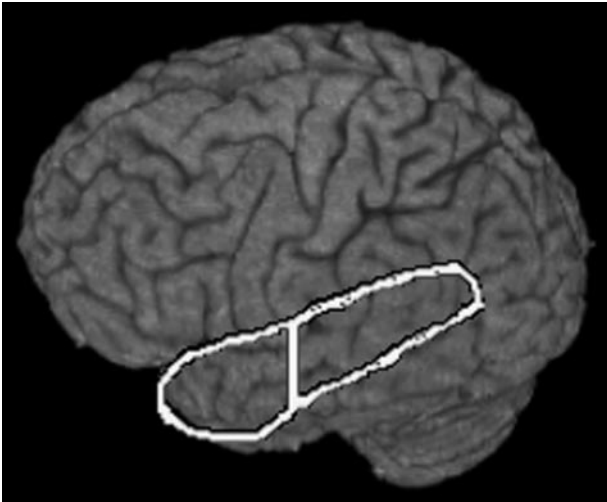


FIG 1. Temporal regions of interest.

Vertical line represents Talairach coordinate $y = -20$, which delineates the anterior region of interest from the posterior region of interest.

Hamberger et al [3] and roughly corresponds to the area of temporal cortex resected in a standard temporal lobectomy). Volumes of activation within each region of interest (left and right) were calculated by counting active voxels within the region of interest.

For the group analysis the statistical maps were smoothed (without threshold) with a 6-mm full width half maximum Gaussian kernel to compensate for residual differences after normalization. Group averages for each task were performed by calculating the mean of the regression coefficients for each voxel and the corresponding t statistic of the mean. Functional maps were created by applying a threshold of $P < .01$. In addition, a voxel-wise t test was used to compare the differences between the group means for each task.

Results

Group Analysis. Table 1 presents the Talairach coordinates for activation associated with each naming task within the temporal lobe of the left hemisphere. Responsive naming, compared with baseline, was associated with activation of the middle, inferior, and superior temporal gyri. Other areas of activation within the dominant hemisphere (data not shown) included extensive activation throughout the inferior frontal gyrus and insula. There was also activation in the superior frontal, middle frontal, precentral, inferior parietal, parahippocampal, and fusiform gyri (Brodmann area [BA] 37), as well as the basal ganglia and thalamus. The parahippocampal activation extended into the hippocampus. Activation occurred in the right hemisphere within the inferior frontal, superior temporal, cingulate, and parahippocampal gyri, as well as the insula, basal ganglia, and cerebellum. There was also a large activation cluster extending from the superior frontal gyrus through the medial frontal and cingulate gyri that covered both the left and right hemispheres.

Temporal activation for confrontation naming compared with baseline was limited to the middle temporal gyrus. Extratemporal activation included in-

ferior frontal and parahippocampal gyri of the dominant hemisphere. The parahippocampal activation in the left hemisphere extended into the hippocampus. There was also activation of the lingual, cuneus, middle occipital, fusiform (BA 37), precentral, anterior cingulate, and inferior parietal gyri, as well as within the insula, basal ganglia, and thalamus of the left hemisphere. Activation occurred in the right hemisphere within the inferior frontal, precentral, precuneus, middle occipital, inferior parietal, cingulate, parahippocampal, and fusiform gyri (BA 37), as well as the insula, thalamus, and basal ganglia. Similar to responsive naming there was a large cluster of activation extending from the superior frontal gyrus through the medial frontal and cingulate gyri covering both the left and right hemispheres.

Figure 2 shows the group activation maps for both language tasks. Responsive naming produced more activation compared with the confrontation naming task within the temporal lobe, with the largest activation cluster extending from the posterior superior temporal gyrus through the middle temporal gyrus to anterior and inferior portions of the temporal lobe. Table 1 also includes the Talairach coordinates that are associated with significant differences between the group means for responsive versus confrontation naming within the temporal lobe. The responsive naming versus confrontation naming contrast resulted in significant activation within the inferior, middle, and superior temporal gyri of the dominant hemisphere. Other areas outside of the temporal lobe were also identified in this contrast, most notably in the inferior frontal lobe (BA 9/46; data not shown). The confrontation naming versus responsive naming contrast indicated that confrontation naming was not associated with increased activation anywhere in the temporal lobe as compared with responsive naming. The confrontation versus responsive naming contrast did result in significant activation in several extratemporal sites, including the cuneus and middle occipital gyri, as well as some other areas, including the insula, cingulate, parahippocampal, and inferior parietal gyri (data not shown). In general, the confrontation naming task was also associated with greater activation of the right hemisphere compared with the responsive naming task.

There were several areas of activation that were associated with both naming tasks. Figure 2 (row C) also depicts the overlapping activation for the group analyses across the 2 naming tasks. In the dominant hemisphere, task activation overlap included areas in the middle occipital and middle temporal gyri, the inferior frontal and precentral gyri, the medial frontal, middle frontal and cingulate gyri, the hippocampus and parahippocampal gyrus, the inferior parietal gyrus, and the basal ganglia. Areas of overlap in the right hemisphere were largest in the inferior frontal gyrus, parahippocampal gyrus, basal ganglia, insula, and cerebellum.

Individual Analysis. To further investigate differences in activation patterns between the 2 naming tasks at an individual subject level, the number of

TABLE 1: Group results: left hemisphere temporal lobe

Cortex	Responsive naming					Confrontation naming				
	BA	x	y	z	z score	BA	x	y	z	z score
Superior temporal	38/22	-50	5	-10	3.5					
Middle temporal	21/22	-48	-12	-6	3.9					
Middle temporal	21/22/39	-50	-41	-1	5.3	22	-50	-42	-1	4.0
Inferior temporal	20	-27	1	-33	3.0	21	-59	-27	-14	3.1

Responsive naming > Confrontation naming					
Cortex	BA	x	y	z	z score
Middle superior temporal	22/39	-41	-55	19	4.0
Middle temp/fusiform	20/21	-48	-4	-19	3.9
Superior temporal	22	-60	-42	6	2.8
Inferior temporal	20	-32	-1	-38	2.9

Note.—BA indicates Brodmann area.

There was no significant activation within the temporal regions of interest for confrontation naming compared to responsive naming.

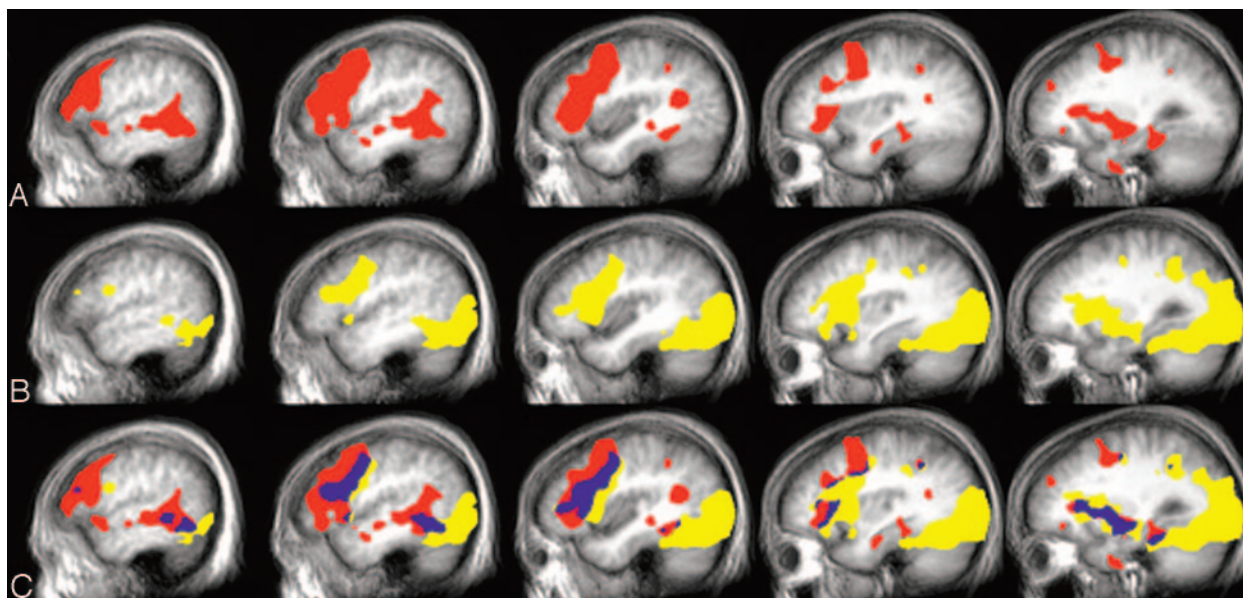


FIG 2. Group activation, left hemisphere.

A, Responsive naming; B, confrontation naming; C, overlap: yellow, confrontation naming; red, responsive naming; blue, overlap.

participants producing activation within each region of interest and the volume of activation in each region of interest were examined. Responsive naming was associated with activation in 90% of the participants within the anterior temporal region of interest and 100% of participants within the posterior temporal region of interest. Confrontation naming also produced activation within 100% of the subjects in the posterior temporal region of interest, but only 60% of subjects in the anterior temporal region of interest.

Table 2 includes the average volume of activation within the regions of interest for each task. Analysis of variance was used to examine differences in activation for each task across the 2 regions of interest. There was a significant effect for both the region of interest ($P = 3.0 \times 10^{-6}$) and the task ($P = .01$). The main effect for task indicates that, overall, responsive

naming produced more activation within the temporal lobe than the confrontation naming task. The main effect for region of interest indicates that, regardless of task, there was more activation within the posterior temporal region of interest than in the anterior temporal region of interest. There was only a nonsignificant trend for an interaction between task and region of interest ($P = .15$), which provides just weak evidence for a possible difference in activation between anterior and posterior regions for confrontation naming compared with responsive naming (with confrontation naming showing somewhat greater of a difference in activation between the 2 regions of interest).

Comparison of Activation in Subjects Who Completed Both Tasks. Table 2 includes the activation volume for each individual subject under the naming

TABLE 2: Individual results

Patient	Responsive Naming		Patient	Confrontation Naming	
	Anterior Temporal	Posterior Temporal		Anterior Temporal	Posterior Temporal
1*	768	4581	1*	99	1004
2*	1124	2950	2*	0	927
3	518	3479	3	213	1107
4	1117	2280	4	1269	3958
5	628	3939	5	0	870
6	839	2444	6	0	707
7	0	1616	7	0	3328
8	278	492	8	323	1246
9	390	4578	9	11	926
10	111	979	10	108	365
Avg	577.4	2733.8		202.3	1443.8
SD	391.1	1434.2		390.5	1192.0

*Participated in both experiments.

conditions in the anterior and posterior temporal regions of interest, including the 2 subjects who completed both tasks. The comparison of responsive naming to confrontation naming for the 2 individual subjects who participated in both experiments were similar to the comparison of the tasks for the non-overlapping subjects; there was more activation detected within both regions of interest for responsive naming compared with confrontation naming. There was minimal activation within the anterior temporal region of interest for both subjects during confrontation naming. In fact, within the anterior temporal region of interest, activation associated with confrontation naming was not detected at all for Subject 2 and the activation detected for Subject 1 was on the outside borders of the anterior temporal region of interest. Figure 3 shows the activation patterns for each task for these 2 subjects. Both subjects produced activation within the anterior temporal region of interest for responsive naming that was near regions detected in the group analyses.

Discussion

The results of this study suggest that there are some anatomically distinct sites of activation for responsive naming and confrontation naming. Group activation associated with the responsive naming task produced more widespread activation of the dominant temporal lobe, particularly within the superior and middle temporal gyri, which extended into anterior portions of the temporal lobe. This degree of mid- to anterior temporal activation was not observed in association with the confrontation naming task. Even at the individual subject level, activation associated with confrontation naming was not as consistently produced in the anterior temporal region of interest as it was with responsive naming (60% vs 90% of the samples showed activation, respectively). As such, our findings by using fMRI are quite similar to the direct cortical stimulation studies, which showed that auditory responsive naming, but not confrontation naming, was disrupted during stimulation of locations within the

anterior portions of the temporal lobe (extending about 4–5 cm from the temporal pole).

The results of the fMRI activation for each task within the posterior temporal region of interest, in comparison to the previous direct cortical stimulation studies, are not as straightforward. The 2 previous stimulation studies reported somewhat different findings with respect to the pattern of disruption associated with the 2 naming tasks within the posterior temporal lobe. Malow et al (2) reported that responsive naming was more disrupted than confrontation naming in the posterior part of the superior and middle temporal gyri, whereas there was a fairly equal degree of disruption of function across the 2 naming tasks in the posterior part of the inferior temporal gyrus. Hamberger et al (3) reported that stimulation within the posterior temporal lobe most often disrupted both confrontation and responsive naming. Our findings revealed some degree of activation within the posterior temporal region of interest during both tasks in all subjects. Responsive naming, however, produced more overall activation in both temporal regions of interest, including the posterior region of interest.

Unfortunately, we were limited to having only 2 subjects who completed both the responsive and confrontation naming tasks. The individual results of the 2 subjects who completed both naming tasks parallel the group results in showing more activation detected in both regions of interest during responsive naming, with confrontation naming producing little if any activation of the anterior temporal region of interest. There have now been a number of studies examining fMRI-related activation associated with various versions of confrontation naming paradigms. Results of the current study are consistent with previous studies showing activation associated with confrontation naming most often involves temporal-occipital cortices (BAs 37, 19, and 18) and the inferior frontal gyrus (7, 27). Most studies have used covert responses during confrontation naming, as done in the current study. Studies that have used overt responses within the scanner, however, have also produced highly similar results (28).

We are aware of only a single study that has examined fMRI-related activation associated with a responsive naming task. Similar to the current study, Balsamo et al (29) reported strong activation within the superior and middle temporal gyri associated with their responsive naming task, with the group analysis appearing to show activation extending into the superior aspects of the temporal lobe. The Balsamo et al study, however, involved young children (mean age, 8.5 years) whose language and semantic network organization may be quite different from those of adults. Furthermore, these authors used a “rest” baseline, which can be problematic (30, 31). Finally, the previous study did not include a confrontation naming task, so activation associated with responsive and confrontation naming could not be compared.

Previous studies have shown that the hippocampus of the speech-dominant hemisphere is a significant

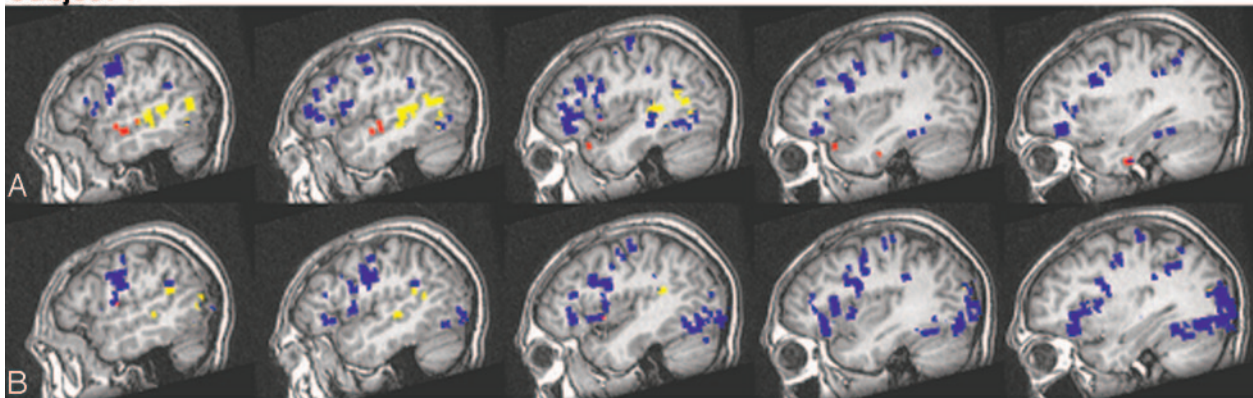
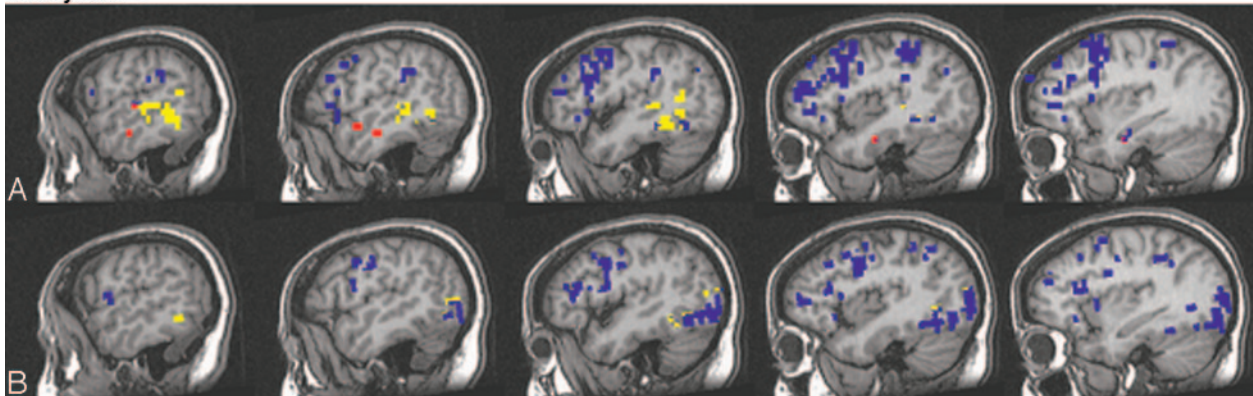
Subject 1**Subject 2**

FIG 3. Individual activation, left hemisphere.

Activation patterns for the 2 subjects who participated in each experiment for (A) responsive naming and (B) confrontation naming. Blue, activation external to the temporal regions of interest; yellow, activation within the posterior temporal region of interest; and red, activation within the anterior temporal region of interest.

component of the neuroanatomic network involved in naming (32–34). In line with such research, the current study also showed that both naming tasks produced hippocampal and parahippocampal activation.

The dissociation between responsive and confrontation naming may reflect modality-specific subsystems involved in word retrieval. Despite the use of an auditory baseline to control for low-level auditory processing, the responsive naming task produced activation throughout much of the temporal lobe (including, but not limited to, primary and secondary auditory cortex). Such activation was strongly lateralized to the left, which suggests that auditory processing was specific to the lexical nature of the stimuli. Activation of inferior frontal regions by both tasks is consistent with other fMRI studies that have compared areas of common activation across different language tasks and suggests that, though word selection and retrieval may be somewhat modality specific (11, 35), other aspects of language such as articulatory planning activate similar areas of the inferior frontal lobe. The finding that both tasks activated a posterior region within the fusiform gyrus is also consistent with previous research that has suggested that BAs 37 and 20 are important in word selection and are believed to be multimodal (28, 36–39), receiving input from auditory, visual, and somatosensory cortices (10, 40–43).

Unlike the confrontation naming task, responsive naming, in addition to word retrieval, requires sentence comprehension. A number of neuroimaging studies have now shown that sentence comprehension involves a distributed frontal and temporoparietal neural network—particularly within the dominant hemisphere—including the temporal pole (44, 45). The anterior temporal lobe may be particularly sensitive to both the semantic and the syntactic demands of the task and may help account for the increased anterior temporal activation during responsive naming as compared with during confrontation naming (44, 46).

Both Hamberger and Tamny (47) and Bell et al (1) have found that responsive naming is more sensitive than confrontation naming to the word retrieval deficits associated with TLE of the dominant hemisphere. Positron-emission tomography (PET) studies have shown that, even in epilepsy patients with hippocampal sclerosis, hypometabolism is not restricted to mesial temporal structures, but generally extends into most of the temporal lobe (48–50). It is this lateral temporal lobe involvement that, in addition to the hippocampal dysfunction, likely produces the mild naming deficits often associated with dominant TLE. The larger area of temporal lobe recruitment during responsive naming observed both in this fMRI study and in the direct cortical stimulation studies

may account for the increased sensitivity of this task (compared with confrontation naming) in detecting the language deficits within the TLE population.

There are some limitations to this study. First, all behavioral responses in the scanner were made covertly, so it is not possible to confirm that the subjects were performing the task correctly. However, participants received extensive training before scanning and were administered an alternate form of the responsive naming task after scanning. These results showed that participants were highly accurate in their responses (accurately named approximately 97% of the items on an alternate form of the task). We do not have behavioral data on the confrontation naming test that would enable a direct comparison of performance levels, but normative studies also indicate that healthy controls of similar age to our sample name approximately 94% of the items on the Boston Naming Test (19). Use of naming tasks strictly matched on difficulty level should be used in future studies.

Group activation associated with responsive naming was minimal in the inferior regions of the temporal pole. This appears to be at odds with the results of Hamberger et al, who reported disruption of this task at multiple sites in this region (3). Limited activation of this area may be related to the MR imaging signal intensity loss due to magnetic susceptibility artifacts from the nearby auditory canal, mastoid air cells, and petrous bone (51). In fact, a study by Devlin et al (52) compared PET activation with fMRI activation for a semantic task and found temporal pole activation with PET but not fMRI. Those researchers also found that analysis of the echo-planar images showed 82% of the voxels in the temporal pole had a signal intensity loss >25%. The use of shimming or acquiring extra images are approaches that may be used to compensate for, or reduce these artifacts (53, 54) and should be the focus of future research. Another limitation to our study findings, which could affect clinical applicability, was that responsive naming, though producing activation in the anterior temporal region of interest in 90% of our participants, fell short of producing activation in the entire sample. Ideally, fMRI tasks that are going to be used to map functions in clinical samples should produce activation within a given cortical region in all healthy controls. Anterior temporal regions are generally associated with low fMRI signal intensity to noise. Increased detection of activation would likely be achieved by increasing the degrees of freedom associated with the statistical tests. This can be done by repeating the same tasks in 2 different fMRI acquisitions and then combining the tasks or increasing the time points within the fMRI acquisition. Further investigation of the activation associated with responsive naming in a larger sample would help elucidate what percent of healthy controls produce activation in the anterior temporal lobe during this task.

In summary, results of this study support the 2 previous cortical stimulation studies suggesting that responsive naming is, in part, subserved by areas of the temporal cortex that are anterior to those areas

associated with confrontation naming (2, 3). Adequate assessment of anterior temporal lobe functions through the identification of tasks such as responsive naming is critical to surgical planning, because they are likely to be useful in predicting the risk of the word-finding changes that can occur after a temporal lobectomy of the dominant hemisphere. Many of the fMRI language paradigms currently in use do not produce activation within the anterior temporal lobe. The selection of language paradigms must be chosen carefully and will vary as a function of the location of the planned surgical resection. We hypothesize that fMRI activation patterns within the anterior temporal lobe associated with responsive naming or other tasks that activate this region may be better predictors of post-temporal lobectomy language outcome than other fMRI paradigms that do not produce activation in this region in healthy individuals. In support of this prediction, the results of Sabsevitz et al (55) suggest that language-related fMRI activation of a temporal region of interest better predicted postsurgical language changes than activation in an inferior frontal region of interest. Future studies examining patterns of temporal lobe fMRI activation associated with responsive naming and other language tasks and detailed postoperative neuropsychological assessment will be useful in determining if they yield differential information in predicting language outcome after temporal lobectomy.

References

1. Bell BD, Seidenberg M, Hermann BP, Douville K. **Visual and auditory naming in patients with left or bilateral temporal lobe epilepsy.** *Epilepsy Res* 2003;55:29–37
2. Malow BA, Blaxton TA, Sato S, et al. **Cortical stimulation elicits regional distinctions in auditory and visual naming.** *Epilepsia* 1996;37:245–252
3. Hamberger MJ, Goodman RR, Perrine K, Tamny T. **Anatomic dissociation of auditory and visual naming in the lateral temporal cortex.** *Neurology* 2001;56:56–61
4. Rausch R, Boone K, Ary CM. **Right-hemisphere language dominance in temporal lobe epilepsy: clinical and neuropsychological correlates.** *J Clin Exp Neuropsychol* 1991;13:217–231
5. Devinsky O, Perrine K, Llinas R, et al. **Preoperative predictors of anterior temporal language areas.** *J Neurosurg* 1998;34:727–732
6. Binder JR, Frost JA, Hammeke TA, et al. **Human brain language areas identified by functional magnetic resonance imaging.** *J Neurosci* 1997;17:353–362
7. Votaw JR, Faber TL, Popp CA, et al. **A confrontational naming task produces congruent increases and decreases in PET and fMRI.** *Neuroimage* 1999;10:347–356
8. Binder JR. **Functional MRI of the language system.** In: Moonen CTW, Bandettini PA, eds. *Functional MRI.* Berlin and Heidelberg: Springer-Verlag;1999:407–419
9. Price CJ. **The anatomy of language: contributions from functional neuroimaging.** *J Anat* 2000;197:335–359
10. Cabeza R, Nyberg L. **Imaging cognition. II. An empirical review of 275 PET and fMRI studies.** *J Cogn Neurosci* 2000;12:1–47
11. Carpentier A, Pugh K, Westerveld M, et al. **Functional MRI of language processing: dependence on input modality and temporal lobe epilepsy.** *Epilepsia* 2001;42:1241–1254
12. Gaillard WD, Pugliese M, Grandin CB, et al. **Cortical localization of reading in normal children: an fMRI language study.** *Neurology* 2001;57:47–54
13. Ogawa S, Tank DW, Menon R, et al. **Intrinsic signal changes accompanying sensory stimulation: functional brain mapping with magnetic resonance imaging.** *Proc Natl Acad Sci U S A* 1992;89:5951–5955
14. Abou-Khalil B, Schlaggar BL. **Is it time to replace the Wada test?** *Neurology* 2002;59:160–161

15. Doyle WK, Spencer DD. **Anterior temporal resections.** In: Engle J Jr, Pedley TA, eds. *Epilepsy: a comprehensive textbook.* Philadelphia: Lippincott-Raven;1997:1807–1817
16. Kim R, Spencer D. **Surgery for mesial temporal sclerosis.** In: Luders HO, Comair YG, eds. *Epilepsy surgery.* Philadelphia: Lippincott, Williams & Wilkins;2001:643–652
17. Kaplan E, Goodglass H, Weintraub S. *Boston naming test.* 2nd ed. Philadelphia: Lea and Febiger;1983
18. Hamberger MJ, Seidel WT. **Auditory and visual naming tests: normative and patient data for accuracy, response time, and tip-of-the-tongue.** *J Int Neuropsychol Soc* 2003;9:479–489
19. Spreen O, Strauss E. *A compendium of neuropsychological tests.* New York: Oxford University Press;1998
20. Buonocore MH, Gao L. **Ghost artifact reduction for echo-planar imaging using image phase correction.** *Magn Reson Med* 1997;38:89–100
21. Cox RW, Jesmanowicz A. **Real-time 3D image registration for functional MRI.** *Magn Reson Med* 1999;42:1014–1018
22. Cox R. **AFNI: Software for analysis and visualization of functional magnetic resonance neuroimages.** *Comp Biomed Res* 1996;29:162–173
23. Forman SD, Cohen JD, Fitzgerald M, et al. **Improved assessment of significant activation in functional magnetic resonance imaging (fMRI): use of a cluster-size threshold.** *Magn Reson Med* 1995;33:636–647
24. Xiong J, Gao J-H, Lancaster JL, Fox PT. **Clustered pixels analysis for functional MRI activation studies of the human brain.** *Hum Brain Mapp* 1995;3:287–301
25. Talairach J, Tournoux P. *Co-planar stereotaxic atlas of the human brain.* New York: Thieme Medical;1988
26. Lancaster JL, Woldorff MG, Parsons LM, et al. **Automated Talairach atlas labels for functional brain mapping.** *Hum Brain Mapp* 2000;10:120–131
27. Murtha S, Chertkow H, Beauregard M, Evans A. **The neural substrate of picture naming.** *J Cogn Neurosci* 1999;11:399–423
28. Abrahams S, Goldstein LH, Simmons A, et al. **Functional magnetic resonance imaging of verbal fluency and confrontation naming using compressed image acquisition to permit overt responses.** *Hum Brain Mapp* 2003;20:29–40
29. Balsamo LM, Xu B, Grandin CB, et al. **A functional magnetic resonance imaging study of left hemisphere language dominance in children.** *Arch Neurol* 2002;59:1168–1174
30. Newman SD, Twieg DB, Carpenter PA. **Baseline conditions and subtractive logic in neuroimaging.** *Hum Brain Mapp* 2001;14:228–235
31. Stark CE, Squire LR. **When zero is not zero: the problem of ambiguous baseline conditions in fMRI.** *Proc Natl Acad Sci U S A* 2001;98:12760–12766.
32. Martin R, Sawrie S, Hugg J, et al. **Cognitive correlates of 1H MRSI-detected hippocampal abnormalities in temporal lobe epilepsy.** *Neurology* 1999;53:2052–2058
33. Sawrie S, Martin RC, Gilliam, FG, et al. **Visual confrontation naming and hippocampal function: A neural network study using quantitative (1)H magnetic resonance spectroscopy.** *Brain* 2000;124:770–780
34. Aldenkamp A, Boon P, Deblaere K, et al. **Usefulness of language and memory testing during intracarotid amobarbital testing: observations from an fMRI study.** *Acta Neurol Scand* 2003;108:147–152
35. Lehericy S, Cohen L, Bazin B, et al. **Functional MR evaluation of temporal and frontal language dominance compared with the Wada test.** *Neurology* 2000;54:1625–1633
36. Benson D, ed. *Neurological correlates of anomia.* New York: Oxford University Press;1979
37. Damasio A. **Aphasia.** *N Engl J Med* 1992;59:531–539
38. Warburton E, Wise RJ, Price CJ, et al. **Noun and verb retrieval by normal subjects: studies with PET.** *Brain* 1996;119:159–179
39. Vandenberghe R, Price C, Wise R, et al. **Functional anatomy of a common semantic system for words and pictures.** *Nature* 1996;383:254–256
40. Luders H, Lesser RP, Hahn J, et al. **Basal temporal language area.** *Brain* 1991;114:743–754
41. Suzuki W, Amaral D. **Topographic organization of the reciprocal connections between the monkey entorhinal cortex and the perirhinal and parahippocampal cortices.** *J Neurosci* 1994;14:1856–1877
42. Price CJ. **The functional anatomy of word comprehension and production.** *Trends Cogn Sci* 1998;2:1201–1207
43. Buchel C, Price C, Friston K. **A multimodal language region in the ventral visual pathway.** *Nature* 1998;394:274–277
44. Noppeney U, Price CJ. **An fMRI study of syntactic adaptation.** *J Cogn Neurosci* 2004;16:702–713
45. Vandenberghe R, Nobre AC, Price CJ. **The response of left temporal cortex to sentences.** *J Cogn Neurosci* 2002;14:550–560
46. Cohen L, Jobert A, Le Bihan D, Dehaene S. **Distinct unimodal and multimodal regions for word processing in the left temporal cortex.** *Neuroimage* 2004;23:1256–1270
47. Hamberger MJ, Tamny TR. **Auditory naming and temporal lobe epilepsy.** *Epilepsy Res* 1999;35:229–243
48. Arnold S, Schlaug G, Niemann H, et al. **Tomography of interictal glucose hypometabolism in unilateral mesiotemporal epilepsy.** *Neurology* 1996;46:1422–1430
49. Theodore W, Sat S, Kufta CV, et al. **Temporal lobectomy for uncontrolled seizures: the role of positron emission tomography.** *Ann Neurol* 1992;32:789–794
50. Chassoux F, Semah F, Bouilleret L, et al. **Metabolic changes and electro-clinical patterns in mesio-temporal lobe epilepsy: a correlative study.** *Brain* 2004;127:164–174
51. Ojemann JG, Akbudak E, Snyder AZ, et al. **Anatomic localization and quantitative analysis of gradient refocused echo-planar fMRI susceptibility artifacts.** *Neuroimage* 1997;6:156–167
52. Devlin JT, Russell RP, Davis MH, et al. **Susceptibility-induced loss of signal: comparing PET and fMRI on a semantic task.** *Neuroimage* 2000;11:589–600
53. Jezzard P, Clare S. **Sources of distortion in functional MRI data.** *Hum Brain Mapp* 1999;8:80–85
54. Deichmann R, Josephs O, Hutton C, et al. **Compensation of susceptibility-induced BOLD sensitivity losses in echo-planar fMRI imaging.** *Neuroimage* 2002;15:120–135
55. Sabsevitz DS, Swanson SJ, Hammeke TA, et al. **Use of preoperative functional neuroimaging to predict language deficits from epilepsy surgery.** *Neurology* 2003;60:1788–1792