

Are your **MRI contrast agents** cost-effective?

Learn more about generic **Gadolinium-Based Contrast Agents**.



**FRESENIUS
KABI**

caring for life

AJNR

Characteristic MR Imaging Changes in Severe Hypermethioninemic States

Nancy E. Braverman, S. Harvey Mudd, Peter B. Barker and Martin G. Pomper

AJNR Am J Neuroradiol 2005, 26 (10) 2705-2706

<http://www.ajnr.org/content/26/10/2705>

This information is current as of April 19, 2024.

Characteristic MR Imaging Changes in Severe Hypermethioninemic States

In a recent report in this journal (1), Tada et al described a patient with markedly elevated plasma methionine (740 μM) and slightly elevated total homocysteine (tHcy) (37 μM) who was diagnosed with possible cystathionine beta-synthase (CBS) deficiency. During dietary methionine restriction with supplemental betaine and, later, pyridoxine, his plasma methionine rose to 960–1560 μM . His tHcy level was normal (6.3–14.9 μM). Decreased appetite and daytime sleepiness developed, and MR imaging revealed diffuse T1 and T2 prolongation in subcortical areas extending to deep white matter with relative sparing of the corticospinal tracts, corpus callosum, optic radiations, ventral brain stem, and cerebellar white matter. Symmetrical lesions in the dorsal brain stem were recognized. Diffusion-weighted imaging (DWI) demonstrated a decreased apparent diffusion coefficient (ADC) in the white matter. These findings were considered by the authors to be less suggestive of CBS deficiency than of an alternative consistent with the metabolite findings, that is, methionine adenosyltransferase I/III (MAT I/III) deficiency (2). MAT I/III deficiency was then confirmed by demonstration of compound heterozygosity for 2 mutations in the gene encoding this enzyme. Therapy was discontinued, plasma methionine decreased to 570–1090 μM , and brain imaging studies largely normalized.

We suggest that the MR imaging abnormalities in question are similar to those already reported in other children with extreme elevations of methionine who developed clinical signs or symptoms of cerebral edema, thus prompting neuroimaging studies: Patient 1. A 10-year-old girl with homocystinuria due to CBS deficiency increased her plasma methionine from 800 to 3000 μM while on betaine therapy (3). MR imaging showed T2 prolongation throughout the supratentorial white matter extending into the brain stem, with relative sparing of the cerebellum. There was striking involvement of the dorsal brain stem, particularly in the region of the midbrain and pons tegmentum (Fig 1A). MR spectroscopy was normal. Patients 2 and 3. Two normal infants developed hypermethioninemia from inadvertent, excessive methionine intake, with levels of 2154 μM and 6830 μM (3). MR imaging findings in both were similar to those in patient 1, and DWI in one showed decreased ADC values in regions corresponding to T2 prolongation within the brain stem (Fig 1B–D). Patient 4. A 4-year-old boy with CBS deficiency was placed on betaine, and his plasma methionine levels rose from 200 to 1190 μM . Methionine was elevated also in CSF (4). MR imaging revealed diffusely abnormal signal within white matter bilaterally, but further imaging was not reported.

Thus, in each of the above-reported patients, hypermethioninemia was associated with similar clinical and distinctive MR imaging abnormalities: widespread edema in subcortical

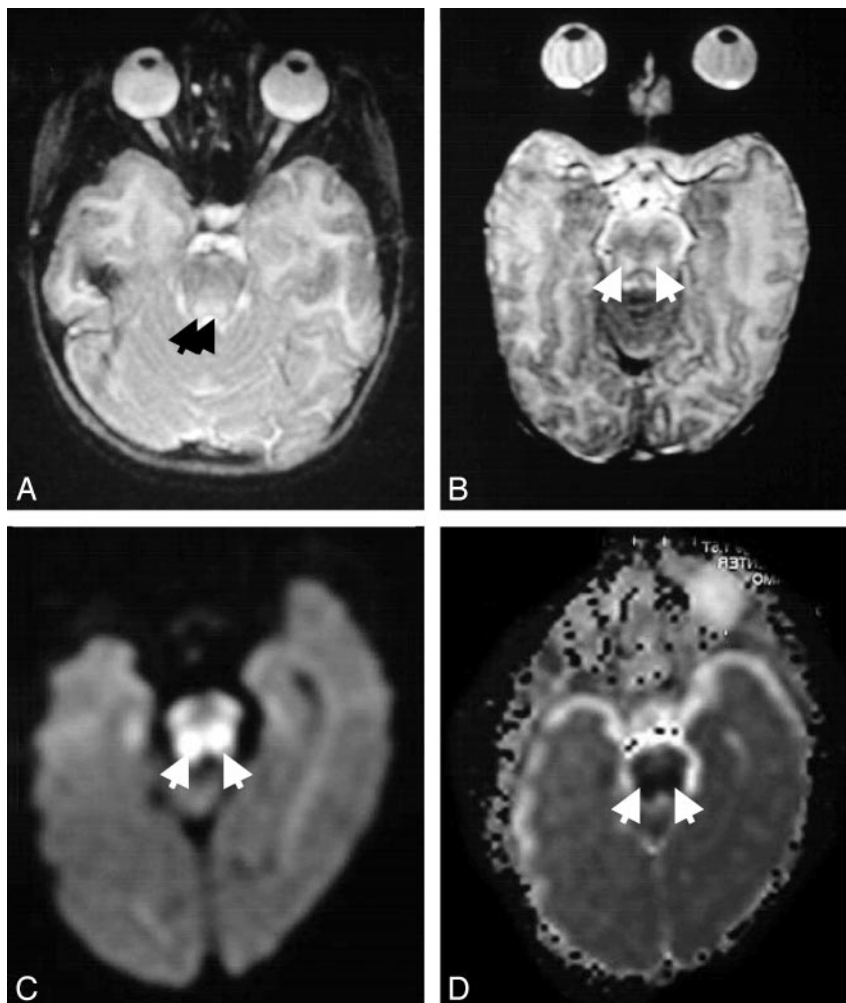


FIG 1. T2-weighted MR images show increased signal diffusely in white matter and focally within the dorsal brain stem (arrows) for patients 1 (A) and 2 (B). For patient 3, note that signal is increased in the $b = 1000$ image (C) and correspondingly decreased in the ADC map (D), indicative of restricted diffusion (arrows).

and deep white matter, being pronounced in the dorsal brain stem, with relative sparing of the cerebellum and ventral brainstem. As proposed by Tada et al (1), restricted water diffusion in those areas could represent intramyelinic edema or reversible energy failure. The metabolites formed from methionine in the major pathway for its disposal are *S*-adenosylmethionine (AdoMet), *S*-adenosylhomocysteine (AdoHcy), homocysteine, and cystathionine. Of these metabolites, neither AdoMet nor AdoHcy is elevated in MAT I/III deficiency (2). tHcy was normal during treatment of the Tada et al patient, and cystathionine is not elevated in CBS deficiency (2). Together, these facts indicate that the high methionine itself was a causative factor in the observed cerebral edema. Although both CBS-deficient and MAT I/III-deficient patients have chronic elevations of methionine, cerebral edema is rare in such patients. Betaine administration more than doubled the methionine levels of the affected children. Because betaine is an intracellular osmolyte, its concomitant use may have contributed to the development of edema. Significantly, after institution of therapy to reduce methionine levels, the clinical and MR imaging findings resolved in all patients. Collectively, these cases underscore a pattern of central nervous system injury due to extremely high methionine levels.

Nancy E. Braverman,* S. Harvey Mudd,†
Peter B. Barker,‡ and Martin G. Pomper‡
Departments of *Pediatrics and †Neuroradiology
Johns Hopkins Medical Institutions
Baltimore, MD
‡Laboratory of Molecular Biology
National Institute of Mental Health
Bethesda, MD

References

1. Tada H, Takanashi J, Barkovich AJ, Yamamoto S, Kohno Y. **Reversible white matter lesion in methionine adenosyltransferase I/III deficiency.** *AJNR Am J Neuroradiol* 2004; 25:1843–1845
2. Stabler SP, Steegborn C, Wahl MC, et al. **Elevated plasma total homocysteine in severe methionine adenosyltransferase I/III deficiency.** *Metabolism* 2002;51:981–988
3. Mudd SH, Braverman N, Pomper, et al. **Infantile hypermethioninemia and hyperhomocysteinemia due to high methionine intake: a diagnostic trap.** *Mol Genet Metab* 2003;79:6–16
4. Devlin AM, Hajipour L, Gholkar A, Fernandes H, Ramesh V, Morris AA. **Cerebral edema associated with betaine treatment in classical homocystinuria.** *J Pediatr* 2004;144(4):545–548

Comments on Time-efficient Technique for Improved Tissue Contrast in Neuroimaging

With reference to the article on phase-sensitive inversion recovery imaging published in the June/July 2005 issue of *AJNR* (1), the authors did not acknowledge in their references our original paper on phase-sensitive inversion recovery imaging pulse sequence, technique, and image reconstruction algorithm for tissue contrast enhancement published by Moran, Kumar, et al in 1986 in *Magnetic Resonance Imaging* (2). The article in the June/July 2005 issue of *AJNR* compared phase-sensitive inversion recovery imaging sequence with T1SE and T1FLAIR and found that the phase-sensitive inversion recovery sequence

has the highest contrast-to-noise ratio efficiency. However, we already published in detail phase-sensitive inversion recovery imaging technique for tissue contrast enhancement in our 1986 article. It is clear that the phase-sensitive inversion recovery imaging technique did not originate with these authors because, as noted, it was already documented in 1986. The authors used the phase-sensitive inversion recovery technique in their *AJNR* paper without acknowledging our original publication. It becomes an ethical issue when a published original article is not cited as a reference.

It is my request that this error be corrected based on merit and on ethical guidelines for publications.

Narinder Kumar
Department of Radiology
VA Medical Center
VA North Texas Health Care Center
Dallas, TX

References

1. Hou P, Hasan KM, Sitton CW, Wolinsky JS, Narayana PA. **Phase-sensitive T1 inversion recovery imaging: a time-efficient interleaved technique for improved tissue contrast in neuroimaging.** *AJNR Am J Neuroradiol* 2005;26:1432–1438
2. Moran PR, Kumar NG, Karstaedt N, Jackels SC. **Tissue contrast enhancement: image reconstruction algorithm and selection of T1 inversion recovery MRI.** *Magn Reson Imaging* 1986;4:229–235

Reply

As stated in our manuscript (1), the main purpose of our paper was to “describe the implementation of a new technique for generating high gray matter (GM) and white matter (WM) contrast in a short scan time, make a quantitative evaluation of the contrast efficiency, and explore its potential applications in neuroimaging.” It was never our intention to claim that we developed the phase-sensitive T1IR technique. This is obvious from the numerous references that we provided to this technique in our publication (1; see references 10–18). In contrast, the main purpose of the important publication by Moran et al (2), as stated in their paper, was “to develop the appropriate physical theory of both image reconstruction methods relevant to IR sequences.” Their publication never addressed the optimization of scan time, which is the main objective of our paper. Thus, we do not think that there is any overlap between their work and the current manuscript.

Ping Hou
Diagnostic and Interventional Imaging
UT Health Science Center at Houston
Houston, TX

References

1. Hou P, Hasan KM, Sitton CW, Wolinsky JS, Narayana PA. **Phase-sensitive T1 inversion recovery imaging: a time-efficient interleaved technique for improved tissue contrast in neuroimaging.** *AJNR Am J Neuroradiol* 2005;26:1432–1438
2. Moran PR, Kumar NG, Karstaedt N, Jackels SC. **Tissue contrast enhancement: image reconstruction algorithm and selection of T1 inversion recovery MRI.** *Magn Reson Imaging* 1986;4:229–235