

Are your MRI contrast agents cost-effective?

Learn more about generic Gadolinium-Based Contrast Agents.



**AJNR**

**Reappraisal of Flow Velocity Ratio in  
Common Carotid Artery to Predict  
Hemodynamic Change in Carotid Stenosis**

Masahiro Kamouchi, Kazuhiro Kishikawa, Yasushi Okada,  
Tooru Inoue, Setsuro Ibayashi and Mitsuo Iida

This information is current as  
of April 17, 2024.

*AJNR Am J Neuroradiol* 2005, 26 (4) 957-962  
<http://www.ajnr.org/content/26/4/957>

## Reappraisal of Flow Velocity Ratio in Common Carotid Artery to Predict Hemodynamic Change in Carotid Stenosis

Masahiro Kamouchi, Kazuhiro Kishikawa, Yasushi Okada, Tooru Inoue, Setsuro Ibayashi, and Mitsuo Iida

**BACKGROUND AND PURPOSE:** Various Doppler criteria have been used to predict hemodynamically significant carotid stenosis. This study was performed to elucidate whether hemodynamically significant stenosis can be predicted indirectly by the blood flow velocity in the common carotid artery (CCA) measured with duplex ultrasonography in patients with unilateral stenosis of internal carotid artery (ICA).

**METHODS:** Eighty-five patients who were scheduled to undergo carotid endarterectomy for unilateral stenosis of ICA origin were analyzed. The flow velocities and their side-to-side ratios in the CCA were calculated. The flow velocities in the CCA were measured with conventional ultrasonography and poststenotic blood flow with transoral carotid ultrasonography. Cerebral angiography was performed to evaluate the intracranial collateral flow.

**RESULTS:** Among the absolute values and side-to-side ratios of Doppler flow velocities in the CCA, the end diastolic flow velocity (EDV) ratio in the CCA best correlated with the residual lumen area ( $r = 0.35$ ;  $P = .0009$ ), stenosis of diameter ( $r = 0.48$ ;  $P < .0001$ ), and poststenotic flow ( $r = 0.60$ ;  $P < .0001$ ). EDV ratios in the CCA were significantly lower in patients with collateral pathways (anterior communicating artery,  $P = .0005$ ; posterior communicating artery,  $P = .004$ ; ophthalmic artery,  $P < .0001$ ; leptomeningeal collateral,  $P = .004$ ). The optimal threshold value of the EDV ratio in the CCA for the presence of intracranial collateral flow and stenosis of diameter  $\geq 70\%$  was 1.2. Those for tight stenosis in a cross-sectional area  $> 95\%$ , the reduction of poststenotic flow, and poststenotic narrowing were 1.4, 1.5, and 1.6, respectively.

**CONCLUSION:** The EDV ratio in the CCA appears to be an additional parameter for predicting hemodynamically significant stenosis in patients with unilateral ICA stenosis.

Atherothrombotic stenosis originating in the internal carotid artery (ICA) is a common cause of carotid territory ischemic stroke. Carotid endarterectomy (CEA) is recognized as a treatment for selected patients with severe symptomatic or asymptomatic extracranial ICA stenosis (1, 2). Ultrasonography, a widely used diagnostic tool, is the best screening test for ICA stenosis, which can be detected by the com-

ination of B-mode and color-encoded flow imaging. Power Doppler imaging reveals more detailed features of the intrastenotic lumen more precisely, particularly in complicated high-grade stenosis (3). Conventional carotid ultrasonography, however, is useless when the carotid lesion is heavily calcified or the carotid bifurcation is located in a high position (4).

If the stenotic area cannot be directly visualized, the diagnosis must depend on indirect signs. Doppler spectral analysis is used to confirm and quantify findings and is considered helpful when vascular segments are not unequivocally distinguishable in the color-coded image. In previous reports, various indices, parameters, and grading methods for detection of hemodynamically significant carotid stenosis have been proposed. Absolute measurements of the internal carotid peak systolic velocity (ICPSV), end-diastolic velocity (ICEDV), and the ratio of the intrastenotic internal carotid peak systolic velocity to the prestenotic common carotid peak systolic velocity

Received June 6, 2004; accepted after revision August 24.

From the Departments of Cerebrovascular Disease (M.K., K.K., Y.O.) and Neurosurgery (T.I.), Cerebrovascular Center and Clinical Research Institute, National Kyushu Medical Center; and the Department of Medicine and Clinical Science (M.K., S.I., M.I.), Graduate School of Medical Sciences, Kyushu University, Fukuoka, Japan.

Address correspondence to Masahiro Kamouchi, MD, PhD, Department of Medicine and Clinical Science, Graduate School of Medical Sciences, Kyushu University, Maidashi 3-1-1, Higashi-ku, Fukuoka 812-8582, Japan.

(ICPSV/CCPSV) have been suggested to estimate the degree of carotid stenosis (5–11). There is, however, no single cut-off point that precisely quantifies the stenosis. ICPSV/CCPSV ratios that predict >70% stenoses (according to the North American Symptomatic Carotid Endarterectomy Trial [NASCET]) ranged from 2.8 to 4.3 (12, 13). Thus, optimal duplex criteria for identification of severe stenosis differ markedly, depending on the sonography machine and laboratory (13–15).

The measurement of side-to-side velocity ratios is superior to the other methods because it is independent of the transducer's frequency, the course of the vessels, and the patient's general circulatory status. We performed the present study to elucidate whether it is possible to establish a discriminatory value of Doppler flow parameters in the common carotid artery (CCA) that can predict severe stenosis, the reduction of the poststenotic flow in the extracranial distal ICA, and intracranial collateral circulation in patients with ICA stenosis.

## Methods

### Patients

The subjects were recruited from patients who were candidates for CEA at the National Kyushu Medical Hospital, Fukuoka, Japan. Patients who had obstructive lesions in intracranial cerebral arteries, carotid arteries except ipsilateral ICA origin, or vertebro-basilar arteries exceeding 50%, which was determined by the same method as that used in the NASCET study (1), were excluded. Patients with a history of major stroke in ICA territory that was confirmed by MR imaging and considered to affect interpretation of cerebral hemodynamics were also excluded. Eighty-five patients were selected for further study (73 men; mean age,  $69.6 \pm 6.5$  years). The study was performed after the subjects granted informed consent to be examined by neuroradiologic tests within a month before CEA.

### Ultrasonography

Ultrasonography was performed by using a color-coded duplex ultrasonographic device (HDI 5000, Philips, Eindhoven, the Netherlands). Sonography beams (12–5 MHz and a 7–4 MHz) were used for conventional carotid imaging and pulsed Doppler. The peak systolic velocity (PSV), end diastolic velocity (EDV), and time-averaged mean velocity (TMV) were measured and then corrected with the incident angle. The side-to-side ratio was calculated by dividing contralateral flow parameter by ipsilateral one measured by using carotid ultrasonography. The pulsatility index (PI) and resistance index (RI) were calculated by using the following formulae:  $PI = (PSV - EDV)/TMV$  and  $RI = (PSV - EDV)/PSV$ . The lumen area at the point of greatest stenosis was measured, and the percent stenosis was calculated by using the cross-sectional area. The average degree of stenosis was  $87.9 \pm 10.6\%$ . Ultrasonography was performed by a neurosonographer who was blinded to the patient information.

To measure poststenotic flow of the extracranial distal ICA, transoral carotid ultrasonography (TOCU) was performed by using the 9–5-MHz convex array transducer in 63 patients. The methods for TOCU have been described elsewhere (16, 17). The properties of the blood vessel were evaluated by the B-mode as well as by color-flow imaging. Doppler blood flow measurements were also made. Blood flow was calculated by the following formula:  $(\text{diameter of poststenotic ICA})^2 \times \pi/4 \times (\text{TMV of poststenotic ICA})$ . An experienced examiner

performed all examinations without knowledge of the degree and side of the stenosis.

### Angiographic Assessment

Conventional selective angiography was performed by using the standard Seldinger technique. A neuroradiologist blinded to all information reviewed the angiograms. To assess the presence of collateral circulation, biplanar views were examined. Definite filling of the anterior communicating artery, posterior communicating artery, and ophthalmic artery was considered to demonstrate the presence of collaterals. The presence of leptomeningeal collaterals was defined, on the basis of a previous study, as retrograde middle cerebral artery flow reaching the surface of the insula (18). The degree of carotid stenosis assessed by the NASCET method was  $75.6 \pm 15.1\%$ . Four patients in whom intracranial collateral pathways were not fully examined were excluded from further analysis for intracranial collaterals.

### Statistics

Linear regression analysis was performed to examine the relationship between flow velocity parameters in the CCA and carotid stenosis or poststenotic blood flow. We analyzed the difference in the flow parameters dependent on intracranial collaterals by using an unpaired *t* test. One-way analysis of variance (ANOVA) comparing the grade of collateral circulation as a nominal variable with the velocity ratio in the CCA as a continuous variable was performed. A post-hoc Bonferroni test was done to detect the difference. A *P* value < .05 was considered significant. The values were expressed as the mean  $\pm$  SD. Receiver operator curves were used to calculate the sensitivity and specificity of the velocity parameters for diagnosing impaired hemodynamics.

## Results

### Doppler Parameters in CCA Related to Severity of Stenosis and Poststenotic Flow

The absolute values of the PSV ( $63.4 \pm 21.6$  cm/s), EDV ( $15.6 \pm 5.4$  cm/s), and TMV ( $28.5 \pm 8.9$  cm/s) in the affected CCA did not correlate with the residual lumen area, although they were associated with the degree of stenosis calculated by the NASCET method (PSV,  $r = 0.30$ ,  $P = .007$ ; EDV,  $r = 0.32$ ,  $P = .005$ ; TMV,  $r = 0.33$ ,  $P = .003$ ). The side-to-side ratios of the EDV ( $1.48 \pm 0.56$ ) and TMV ( $1.27 \pm 0.41$ ), but not the PSV ( $1.37 \pm 0.47$ ), were significantly correlated with the severity of the cross-sectional stenosis. All the ratios were associated with the degree of stenosis calculated by the NASCET method (Table 1).

The values of the PSV, EDV, and TMV in the affected CCA were significantly associated with poststenotic flow ( $4.0 \pm 2.3$  mL/s; PSV,  $r = 0.41$ ,  $P = .0009$ ; EDV,  $r = 0.56$ ,  $P < .0001$ ; TMV,  $r = 0.53$ ,  $P < .0001$ ) and poststenotic diameter ( $3.5 \pm 0.7$  mm; PSV,  $r = 0.28$ ,  $P = .03$ ; EDV,  $r = 0.40$ ,  $P = .001$ ; TMV,  $r = 0.30$ ,  $P = .02$ ) estimated by TOCU. This tendency was more evident in the side-to-side ratios of these flow velocities (Table 1). The relationship between the EDV ratios and the poststenotic flow is shown in Figure 1.

The absolute values, as well as the ratios of the PI ( $1.70 \pm 0.45$ ) and RI ( $0.75 \pm 0.07$ ), were associated

**TABLE 1: Linear regression analysis of the correlations of side-to-side ratios of CCA Doppler parameters, and severity of the stenosis or poststenotic status**

Side-to-side ratio	Area stenosis		NASCET stenosis		Poststenotic flow		Poststenotic diameter	
	<i>r</i>	<i>P</i>	<i>r</i>	<i>P</i>	<i>r</i>	<i>P</i>	<i>r</i>	<i>P</i>
PSV		NS	0.30	.008	0.39	.002	0.41	.0009
EDV	0.35	.0009	0.48	<.0001	0.60	<.0001	0.66	<.0001
TMV	0.25	.02	0.38	.0008	0.46	.0002	0.47	<.0001
PI		NS		NS		NS		NS
RI		NS		NS	0.23	0.03		NS

Note.—Coefficients of the correlation (*r*) are described. *P* value under .05 is considered to be significant. NS represents not significant.

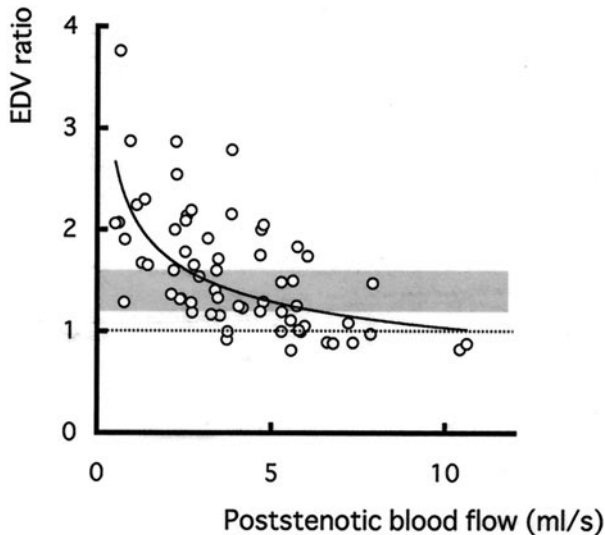


Fig 1. Scatter plot of poststenotic flow versus the side-to-side ratio of EDVs. The abscissa indicates the poststenotic flow. Dotted line and shaded area indicate the EDV ratio at 1.0 and the range between 1.2 and 1.6, respectively. The line was drawn on the basis of the following equation: ED ratio =  $2.16 \times (\text{poststenotic flow})^{-0.32}$ ;  $r = 0.63$ .

with neither degree of stenosis nor poststenotic diameter. Only a weak association was observed between the ratios of the RI and the reduction of the poststenotic flow (Table 1).

#### *Doppler Flow Parameters in CCA and Collateral Pathways*

EDV ( $P = .0003$ ) and TMV ( $P = .005$ ) in patients with an ophthalmic artery and EDV ( $P = .005$ ) and TMV ( $P = .03$ ) in patients with a leptomeningeal collateral were significantly lower. In patients with a posterior communicating artery, no difference was seen in these parameters. In patients having an anterior communicating artery, the absolute values of PI ( $P = .04$ ) were significantly lower than those without the collateral.

The PSV, EDV, and TMV ratios related to the collateral pathways are shown in Table 2. The EDV ratio in the CCA was significantly higher in patients with any type of collateral pathway (all  $P < .05$  by unpaired *t* test) and also tended to be higher in patients having more extensive collateral pathways

(ANOVA,  $P < .0001$ ; Fig 2). This tendency was less evident in the TMV ratio. The PSV ratio was independent of intracranial collaterals (Table 2).

Absolute measurements of PI and RI showed a similar tendency, but less evidently (data not shown). The PI ratio did not differ according to the presence of collaterals. The RI ratio was significantly higher only in patients with an anterior communicating artery.

#### *Sensitivity and Specificity of EDV Ratio Criteria in Predicting Hemodynamically Significant Carotid Stenosis*

Data derived from receiver operator curves were used to calculate the sensitivity and specificity of the side-to-side ratio of EDV in the CCA. Figure 3 shows the receiver operator curves for diagnosing various hemodynamically significant conditions. The optimal values that provide the maximum balance between sensitivity and specificity in detecting these hemodynamic changes due to ICA stenosis are listed in Table 3. Optimal threshold values of the EDV ratio ranged between 1.2 and 1.6, depending on the nature of the hemodynamically significant changes.

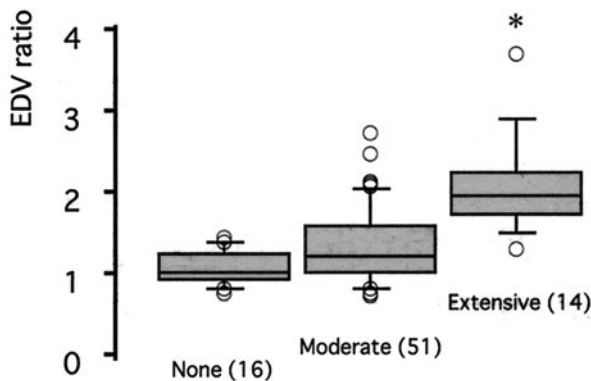
#### **Discussion**

There is currently a trend in vascular surgery toward less-invasive diagnostic methods (19). Thus, duplex scanning has emerged as a substitute for routine arteriography in selected patients who are candidates for CEA. There are various morphologically and hemodynamically based methods for grading stenoses of the ICA (4), but the absolute value of the flow velocity remarkably varies with the individual. By contrast, the velocity ratio in the CCA appears to be relatively unchanged and can be estimated even in case of technically inadequate duplex scanning of the ICA. In the present study, among the absolute values and side-to-side ratio of Doppler parameters in the CCA, the EDV ratio most closely correlated with the severity of stenosis and reduction of poststenotic flow estimated by TOCU. Moreover, the EDV ratio was significantly higher in patients with intracranial collaterals. We evaluated a decrease in poststenotic flow by using TOCU, because TOCU has been reported to be capable of measuring blood flow in the extracranial distal ICA in patients with stenosis of ICA origin

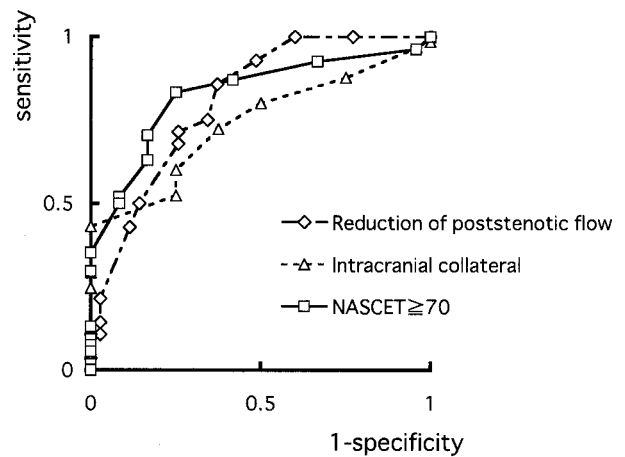
**TABLE 2: Difference in CCA Doppler parameters between patients with and without each intracranial collateral**

Side-to-side ratio	ACoA		PCoA		OA		LM	
	(56/25)	<i>P</i>	(19/62)	<i>P</i>	(21/60)	<i>P</i>	(14/67)	<i>P</i>
PSV	1.32 ± 0.43	NS	1.30 ± 0.30	NS	1.38 ± 0.38	NS	1.40 ± 0.42	NS
EDV	1.17 ± 0.37	.0005	1.27 ± 0.45	.004	1.24 ± 0.42	<.0001	1.25 ± 0.41	.004
	1.63 ± 0.59		1.81 ± 0.65		2.00 ± 0.66		1.88 ± 0.84	
TMV	1.18 ± 0.29	.009	1.39 ± 0.49	.05	1.31 ± 0.39	.003	1.41 ± 0.45	NS
	1.47 ± 0.52		1.57 ± 0.57		1.64 ± 0.44		1.51 ± 0.51	
PI	1.18 ± 0.28	NS	1.33 ± 0.43	NS	1.29 ± 0.45	NS	1.36 ± 0.47	NS
	0.90 ± 0.28		0.88 ± 0.30		0.91 ± 0.32		0.97 ± 0.29	
RI	1.00 ± 0.22	.01	0.95 ± 0.25	NS	0.94 ± 0.24	NS	0.92 ± 0.26	NS
	0.95 ± 0.11		0.95 ± 0.12		0.95 ± 0.13		0.95 ± 0.13	
	1.01 ± 0.08		0.97 ± 0.10		0.97 ± 0.09		0.97 ± 0.09	

Note.—ACoA indicates anterior communicating artery; PCoA, posterior communicating artery; OA, ophthalmic artery; and LM, leptomeningeal collateral. The number in parenthesis indicates the number of the patients with/without each collateral. The side-to-side ratios of Doppler parameters are described in the Table. Upper and lower columns indicate the ratio in patients with and without the collaterals, respectively; *P* value under .05 is considered to be significant; and NS represents not significant.



**FIG 2.** Side-to-side ratios of EDV in the CCA were plotted according to the grade of the development of collateral pathways. Patients who had one or two collaterals and more than three collaterals were defined as moderate and extensive groups, respectively. Numbers in parentheses indicate the number of patients. \**P* < .0001 versus control group and moderate group. The EDV ratio exceeded 1.35 in all patients in the extensive group, although it was not below 1.5 in any collateral group.



**FIG 3.** Receiver operator curves of the EDV ratio in the CCA for hemodynamic changes including severe reduction of poststenotic flow <3.4 mL/s (---◇---), presence of intracranial collateral (---△---), and stenosis of diameter ≥70% calculated by the NASCET method (—□—).

(16, 17, 20, 21). As a result, the EDV ratio in the CCA was associated with poststenotic flow. Although TOCU is not yet popular and is not widely available, the flow velocity in the CCA can be easily measured by using conventional methods. Therefore, the EDV ratio in the CCA may be useful to predict the poststenotic flow decrease and development of intracranial collaterals. The EDV ratio can help to detect hemodynamically significant change in conjunction with duplex imaging of ICA stenosis.

Recent reports have indicated that various techniques are capable of detecting hemodynamically significant stenosis. Previous reports showed that examinations such as the ophthalmic artery color duplex scanning signal intensity (22), transcranial Doppler (TCD) findings (23, 24), the combination of MR (MR) spectroscopy and MR angiography (MRA; 25), and the combination of TCD and MRA (26) are useful for detecting hemodynamically significant carotid stenosis. Compared with these techniques, the flow velocity ratio in the CCA appears to be a more

convenient criterion because it can be additionally obtained by routine examination.

Yasaka et al (27) reported that the side-to-side ratio of the EDV in the CCA can identify the side of the occlusion in the ICA in patients with acute cardioembolic stroke. They suggested that an EDV ratio ≥4.0 is indicative of ICA occlusion in patients with cardioembolic stroke. Kimura et al (28) reported that the finding of a CCA EDV ratio >1.4 is a likely indication of atherothrombotic occlusion of the ICA. In contrast to embolic occlusion, a collateral pathway develops more extensively in atherothrombotic stenosis, and, as a result, the criteria may be altered. No report has studied the significance of the EDV ratio in carotid stenosis. In the present study, the EDV ratio in the CCA was evaluated in patients with atherothrombotic ICA stenosis. The decrease in poststenotic flow beyond ICA stenosis was detected by using TOCU, and the best cut-off EDV ratio to predict the hemodynamic change was determined. The sensitivity-specificity curve revealed that the optimal threshold varies from 1.2 to 1.6 according to the



TABLE 3: Best cut-off EDV ratio for the detection of hemodynamic change and intracranial collaterals

	EDV ratio	Sensitivity	Specificity	PPV	NPV
Poststenotic flow decrease (moderate)	1.2	86	70	86	70
Intracranial collateral flow	1.2	72	63	89	36
Stenosis $\geq 70\%$ by NASCET	1.2	83	75	88	67
Stenosis $\geq 95\%$ in area	1.4	82	62	35	93
Poststenotic flow decrease (severe)	1.5	71	74	69	76
Poststenotic narrowing	1.6	76	71	57	85

Note.—PPV indicates positive predictive value; NPV, negative predictive value. Moderate decrease in poststenotic flow was defined as poststenotic flow  $< 5$  ml/s, since a poststenotic flow below 5 ml/s has been reported to be indicative of the development of intracranial collaterals (21). Severe decrease in poststenotic flow was also defined as  $< 3.4$  ml/s, the lower limit of 95% confidence interval. Poststenotic narrowing and severe stenosis were defined as the lower limit of 95% confidence interval. Best cut-off values of EDV ratio for predicting each hemodynamic change were obtained using receiver operator curve.

extent of hemodynamic change. When the EDV ratio exceeds 1.2, it is possible that stenosis of diameter is high-grade, exceeding 70% estimated by the NASCET method, and that poststenotic flow is reduced and intracranial collaterals develop. Ratios beyond 1.4, 1.5, and 1.6 may indicate a cross-sectional stenosis  $> 95\%$ , highly reduced poststenotic flow, and poststenotic narrowing, respectively. It has been reported that the extracranial ICA distal to tight stenosis is narrowed or collapsed (16, 17, 29, 30). Thus, a ratio  $> 1.6$  suggests the reduction of poststenotic flow below the critical level. When the ratio is  $> 2.2$ , the specificity for any hemodynamically significant parameter is 100%. Taken together, an EDV ratio in the CCA  $> 1.2$  indicates the presence of possible hemodynamic change in the poststenotic portion of the extracranial distal ICA and subsequent development of intracranial collaterals. A ratio in excess of 1.6 potentially indicates the collapse of the distal ICA due to severe stenosis that exceeds the critical level.

### Conclusion

There are some limitations in evaluation of the EDV ratio in the CCA. When the contralateral carotid artery is stenosed, the side-to-side ratio will be modified. Moreover, obstructive lesions in the external carotid artery or CCA may also affect the ratio. Although atherothrombotic stenosis often occurs in the origin of the ICA, the possible presence of other significant lesions should be taken into consideration in the assessment of the EDV ratio. Regardless of these limitations, the EDV ratio appears to be less laboratory-specific. We believe that this simple method can help distinguish hemodynamically significant stenosis in the ICA. Further study is needed to focus on the clinical significance of the EDV ratio.

### Acknowledgments

This study was supported by research grants for cardiovascular diseases (12A-2, 12C-10, and 14A-3) from the Ministry of Health, Labor, and Welfare of Japan.

### References

- Barnett HJ, Taylor DW, Eliasziw M, et al. Benefit of carotid endarterectomy in patients with symptomatic moderate or severe stenosis: North American Symptomatic Carotid Endarterectomy Trial Collaborators. *N Engl J Med* 1998;339:1415–1425
- Randomised trial of endarterectomy for recently symptomatic carotid stenosis: final results of the MRC European Carotid Surgery Trial (ECST). *Lancet* 1998;351:1379–1387
- Steinke W, Ries S, Artemis N, et al. Power Doppler imaging of carotid artery stenosis: comparison with color Doppler flow imaging and angiography. *Stroke* 1997;28:1981–1987
- Landwehr P, Schulte O, Voshage G. Ultrasound examination of carotid and vertebral arteries. *Eur Radiol* 2001;11:1521–1534
- Faught WE, Mattos MA, van Bemmelen PS, et al. Color-flow duplex scanning of carotid arteries: new velocity criteria based on receiver operator characteristic analysis for threshold stenoses used in the symptomatic and asymptomatic carotid trials. *J Vasc Surg* 1994;19:818–827
- Carpenter JP, Lexa FJ, Davis JT. Determination of sixty percent or greater carotid artery stenosis by duplex Doppler ultrasonography. *J Vasc Surg* 1995;22:697–703; discussion 703–695
- Suwanwela N, Can U, Furie KL, et al. Carotid Doppler ultrasound criteria for internal carotid artery stenosis based on residual lumen diameter calculated from en bloc carotid endarterectomy specimens. *Stroke* 1996;27:1965–1969
- Alexandrov AV, Brodie DS, McLean A, et al. Correlation of peak systolic velocity and angiographic measurement of carotid stenosis revisited. *Stroke* 1997;28:339–342
- AbuRahma AF, Robinson PA, Strickler DL, et al. Proposed new duplex classification for threshold stenoses used in various symptomatic and asymptomatic carotid endarterectomy trials. *Ann Vasc Surg* 1998;12:349–358
- Chen JC, Salvian AJ, Taylor DC, et al. Predictive ability of duplex ultrasonography for internal carotid artery stenosis of 70%–99%: a comparative study. *Ann Vasc Surg* 1998;12:244–247
- Koga M, Kimura K, Minematsu K, Yamaguchi T. Diagnosis of internal carotid artery stenosis greater than 70% with power Doppler duplex sonography. *AJNR Am J Neuroradiol* 2001;22:413–417
- Chang YJ, Golby AJ, Albers GW. Detection of carotid stenosis: from NASCET results to clinical practice. *Stroke* 1995;26:1325–1328
- Kuntz KM, Polak JF, Whittlemore AD, et al. Duplex ultrasound criteria for the identification of carotid stenosis should be laboratory specific. *Stroke* 1997;28:597–602
- Fillinger MF, Baker RJ Jr, Zwolak RM, et al. Carotid duplex criteria for a 60% or greater angiographic stenosis: variation according to equipment. *J Vasc Surg* 1996;24:856–864
- Howard G, Baker WH, Chambless LE, et al. An approach for the use of Doppler ultrasound as a screening tool for hemodynamically significant stenosis (despite heterogeneity of Doppler performance): a multicenter experience: Asymptomatic Carotid Atherosclerosis Study Investigators. *Stroke* 1996;27:1951–1957
- Kishikawa K, Kamouchi M, Okada Y, et al. Evaluation of distal extracranial internal carotid artery by transoral carotid ultrasonography in patients with severe carotid stenosis. *AJNR Am J Neuroradiol* 2002;23:924–928
- Kishikawa K, Kamouchi M, Okada Y, et al. Transoral carotid ultrasonography as a diagnostic aid in patients with severe carotid stenosis. *Cerebrovasc Dis* 2004;17:106–110
- Derdeyn CP, Shaibani A, Moran CJ, et al. Lack of correlation between pattern of collateralization and misery perfusion in patients with carotid occlusion. *Stroke* 1999;30:1025–1032
- Khaw KT. Does carotid duplex imaging render angiography redundant before carotid endarterectomy? *Br J Radiol* 1997;70:235–238

20. Yasaka M, Kimura K, Otsubo R, et al. **Transoral carotid ultrasonography.** *Stroke* 1998;29:1383–1388
21. Kamouchi M, Kishikawa K, Okada Y, et al. **Poststenotic flow and intracranial hemodynamics in patients with carotid stenosis: TOCU study.** *AJNR Am J Neuroradiol* 2005;26:76–81
22. Nuzzaci G, Righi D, Borgioli F, et al. **Duplex scanning exploration of the ophthalmic artery for the detection of the hemodynamically significant ICA stenosis.** *Stroke* 1999;30:821–826
23. Can U, Furie KL, Suwanwela N, et al. **Transcranial Doppler ultrasound criteria for hemodynamically significant internal carotid artery stenosis based on residual lumen diameter calculated from en bloc endarterectomy specimens.** *Stroke* 1997;28:1966–1971
24. Wilterdink JL, Feldmann E, Furie KL, et al. **Transcranial Doppler ultrasound battery reliably identifies severe internal carotid artery stenosis.** *Stroke* 1997;28:133–136
25. van der Grond J, Eikelboom BC, Mali WP. **Flow-related anaerobic metabolic changes in patients with severe stenosis of the internal carotid artery.** *Stroke* 1996;27:2026–2032
26. Anzola GP, Gasparotti R, Magoni M, Prandini F. **Transcranial Doppler sonography and magnetic resonance angiography in the assessment of collateral hemispheric flow in patients with carotid artery disease.** *Stroke* 1995;26:214–217
27. Yasaka M, Omae T, Tsuchiya T, Yamaguchi T. **Ultrasonic evaluation of the site of carotid axis occlusion in patients with acute cardioembolic stroke.** *Stroke* 1992;23:420–422
28. Kimura K, Yonemura K, Terasaki T, et al. **Duplex carotid sonography in distinguishing acute unilateral atherothrombotic from cardioembolic carotid artery occlusion.** *AJNR Am J Neuroradiol* 1997;18:1447–1452
29. Morgenstern LB, Fox AJ, Sharpe BL, et al. **The risks and benefits of carotid endarterectomy in patients with near occlusion of the carotid artery. North American Symptomatic Carotid Endarterectomy Trial (NASCET) Group.** *Neurology* 1997;48:911–915
30. Rothwell PM, Warlow CP. **Low risk of ischemic stroke in patients with reduced internal carotid artery lumen diameter distal to severe symptomatic carotid stenosis: cerebral protection due to low poststenotic flow? On behalf of the European Carotid Surgery Trialists' Collaborative Group.** *Stroke* 2000;31:622–630