Are your MRI contrast agents cost-effective?
Learn more about generic Gadolinium-Based Contrast Agents.
FRESENIUS KABI
caring for life

AJNR

Fatal Recurrent Subarachnoid Hemorrhage After Complete Endovascular Aneurysm Occlusion

M. Bendszus, C. Hagel, M. Maurer, A. Schütz, G.H. Vince, M.C. Monoranu and L. Solymosi

AJNR Am J Neuroradiol 2006, 27 (10) 2058-2060
http://www.ajnr.org/content/27/10/2058

This information is current as of April 18, 2024.

CASE REPORT

Fatal Recurrent Subarachnoid Hemorrhage After Complete Endovascular Aneurysm Occlusion

M. Bendszus
C. Hagel
M. Maurer
A. Schütz
G.H. Vince
M.C. Monoranu
L. Solymosi

SUMMARY: Endovascular treatment of aneurysms has become an alternative to the neurosurgical approach. Here, we describe a patient presenting with a subarachnoid hemorrhage (SAH) due to a basilar tip aneurysm, which was completely occluded with coils. Fourteen days later the patient died due to massive recurrent SAH. Histologic evaluation showed aneurysm rerupture with coil dislocation in the subarachnoid space. This is a rare histologically documented case of fatal recurrent hemorrhage early after coil embolization of cerebral aneurysms.

Endovascular occlusion of cerebral aneurysms has developed into a safe and effective therapeutic alternative to open surgery. In aneurysms suited both for surgical and endovascular treatment with coil embolization, there is substantial evidence that interventional procedures are superior in terms of outcome after 1 year.[1] Despite these favorable clinical results, there is still debate on the long-term occlusion of coiled aneurysms and the risk for recurrent subarachnoid hemorrhage (SAH). Here, we present the case of recurrent SAH despite complete endovascular aneurysm occlusion with coils. Histologic work-up demonstrated a rerupture as the source for the fatal rebleeding.

Case Description

A 42-year-old woman presented with a sudden onset of headache and nausea. On clinical examination, there was no focal neurologic deficit. CT of the brain demonstrated a massive basal subarachnoid hemorrhage, brain swelling, and enlarged ventricles. Primary treatment included the placement of an external ventricular drainage. Intra-arterial angiography of the cerebral vessels demonstrated a solitary aneurysm of the basilar tip. The aneurysm measured $3 \times 3 \times 2.5$ mm and presented a broad neck (2.5 mm, Fig 1). On the basis of the angiographic configuration and the localization of the aneurysm, coil embolization was chosen in an interdisciplinary conference. Under therapeutic heparinization (Liquemin, Hoffmann La Roche, Grenzach, Germany; intravenous bolus of 50 IU/kg of body weight, followed by a maintenance dose of 25 IU/kg of body weight per hour throughout the procedure), a 5F guiding catheter (Envoy, Cordis, Miami Lakes, Fla) was placed in the left vertebral artery. The aneurysm was probed by using a microcatheter (Prowler 14, Cordis). Because of the wide neck of the aneurysm, it was not possible to place a coil in the aneurysm without it prolapsing into the basilar artery. Therefore, a nondetachable balloon catheter (HyperForm 4×7 mm, Micro Therapeutics, Irvine, Calif) was introduced to transiently occlude the basilar artery at the aneurysm neck while placing a coil (remodeling technique). A total of 3 coils (Micrus, Sunnyvale, Calif; Spherical, 3 mm; Ultipaq, 2×4 mm; and Ultipaq, 2×2 mm) were positioned in the aneurysm. The aneurysm was angiographically completely occluded, and it was not possible to place another coil in the aneurysm because of coil migration, despite balloon protection of the parent artery (Fig 1).

The next day, the patient was without neurologic deficit. Heparin treatment was stopped on the third day after the endovascular treatment. In the postoperative course, the patient developed increased blood-flow velocities on Doppler sonography, suggestive of vasospasm (up to 180 cm/s in both middle cerebral arteries). Intra-arterial control angiography of the cerebral vessels was performed 1 day later; however, no evidence of vasospasm was detected. The aneurysm was still completely occluded, and the position of the coils was unchanged. No secondary aneurysm was present. Under peroral treatment with nimodipine, flow velocities on Doppler sonography regressed. The external ventricular drainage was removed, and the patient completely recovered from the SAH so that she could be scheduled for early rehabilitation. On the fourteenth postoperative day, the patient was seen awake in bed at 3:00 AM. Four hours later she was found dead.

Autopsy findings could not demonstrate a peripheral organ disorder as a potential cause for the sudden death of the patient. On opening of the dura massive, acute SAH was present in the basal cisterns and there was a diffuse swelling of the brain parenchyma (Fig 2). Basal leptomeninges were removed, and the basal arteries were carefully isolated, together with the aneurysm. The arteries of the circle of Willis as well as the peripheral branches were thoroughly inspected, but a secondary aneurysm was not seen. After preparation of the coiled aneurysm, a plastification process was performed.[2] The specimen was cut at an orientation perpendicular to the plane of the orifice of the aneurysm followed by sectioning of 1 surface. The sections were then mounted on glass slides, and the top surface was further sectioned to a thickness of 5–10 μm for histopathologic examination. The samples were stained with toluidine blue and embedded in Eukitt mounting medium (Kindler, Freiburg, Germany).

The aneurysm was seen filled with coils and a fresh thrombus. There was no significant accumulation of macrophages or scar tissue formation (Fig 2). The ventral wall of the aneurysm appeared discontinuous. On parasagittal sections, coils surrounded by fresh blood clots were found outside the aneurysm in the subarachnoid space ventral to the basilar tip (Fig 2). On both angiographic angiograms, the coil mass was located dorsal to the basilar tip. The histologic findings indicated a rerupture of the aneurysm at the ventral portion of the aneurysm sac with coil protrusion in the subarachnoid space (Figs 3 & 4).

Discussion

Most spontaneous subarachnoid hemorrhages are caused by rupture of a saccular aneurysm of the basal cerebral arteries. Treatment of the aneurysm is intended to prevent recurrent

Received August 17, 2005; accepted after revision November 3.

From the Departments of Neuroradiology (M.B., A.S., L.S.), Neuropathology (M.C.M.), Neurology (M.M.), and Neurosurgery (G.H.V.), University of Würzburg, Germany; and the Department of Neuropathology (C.H.), University of Hamburg, Germany.

Please address correspondence to: M. Bendszus, MD, Department of Neuroradiology, University of Würzburg, Josef-Schneider-Str 11, D-97080 Würzburg, Germany; e-mail: bendszus@neuroradiologie.uni-wuerzburg.de

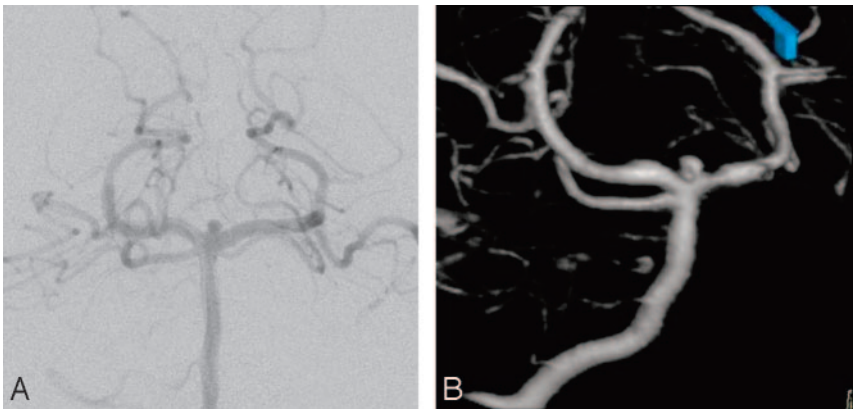

Fig 1. Preinterventional angiogram of the basilar tip aneurysm. Anteroposterior (*A*) and 3D view (*B*) demonstrate a basilar tip aneurysm, which is directed posteriorly.

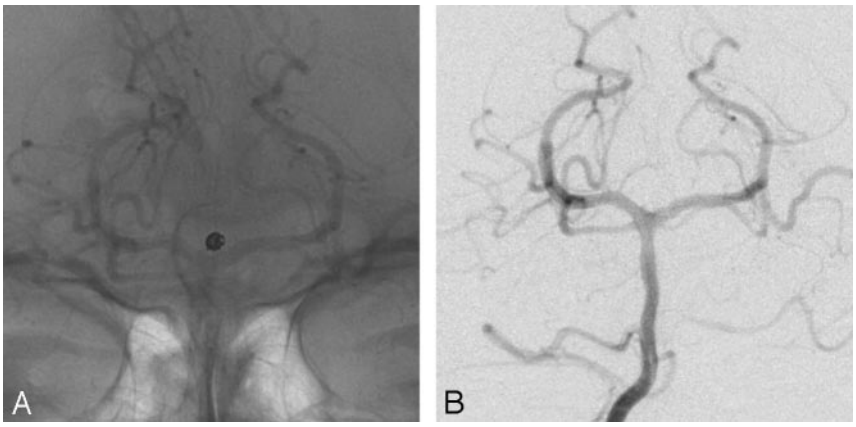

Fig 2. Postinterventional angiogram of the basilar tip aneurysm. Unsubtracted (*A*) and corresponding subtracted (B) anteroposterior view after endovascular treatment shows complete angiographic occlusion of the aneurysm. The coils are located inside the aneurysm.

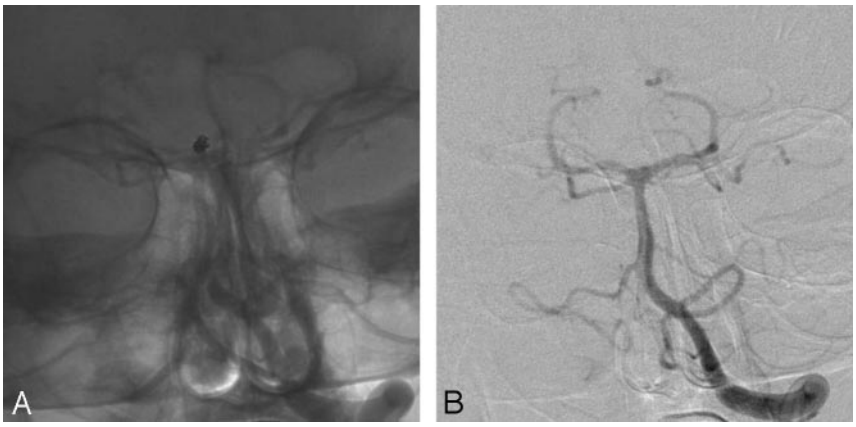

Fig 3. Control angiogram 4 days after coiling for suspected vasospasm. The coil package is in identical shape and position. The aneurysm is still completely occluded, and there is no evidence of vasospasm. This projection is slightly different from that shown in Fig 2.

hemorrhage, which is otherwise thought to occur in at least 50% of untreated ruptured aneurysms within the first 6 months.[3] The long-standing treatment of ruptured intracranial aneurysms is surgical clipping. In completely occluded aneurysms, the recurrence rate of SAH is very low in the acute phase. There is, however, an increase in the bleeding risk of up to 9% after 20 years.[4]

Endovascular occlusion of aneurysms by placing platinum coils has become an alternative treatment technique for aneurysms. A large multicenter study revealed a significantly improved outcome after 1 year in patients with endovascular treatment compared with surgically treated patients.[1] Nevertheless, there is debate on the efficacy of the endovascular approach in terms of complete aneurysm occlusion, recanalization, and the risk of recurrent hemorrhage. Coil treatment harbors a greater risk for aneurysm remnants and recanalization compared with surgical clipping.[1] However, even in incompletely occluded aneurysms, the risk for recurrent hemorrhage appears to be low.[1,5] Especially in the acute phase after the initial hemorrhage, recurrent SAH has rarely been reported and has been attributed to high-dose anticoagulation, incomplete occlusion of the aneurysm, or both.[6,7] Rarely, recurrent hemorrhage has been described in completely coil-occluded aneurysms in the acute phase.[1,8]

Sluzewski et al[8] reported that risk factors for early rebleeding included adjacent intracerebral hematoma and small (<6 mm) aneurysm size. None of these cases were analyzed on histopathology. Here, we describe a patient with complete angiographic aneurysm occlusion, which was confirmed in early follow-up angiography. Even though no anticoagulation was maintained, the patient died in the early phase because of recurrent aneurysm rupture and massive SAH. This case shows that even complete

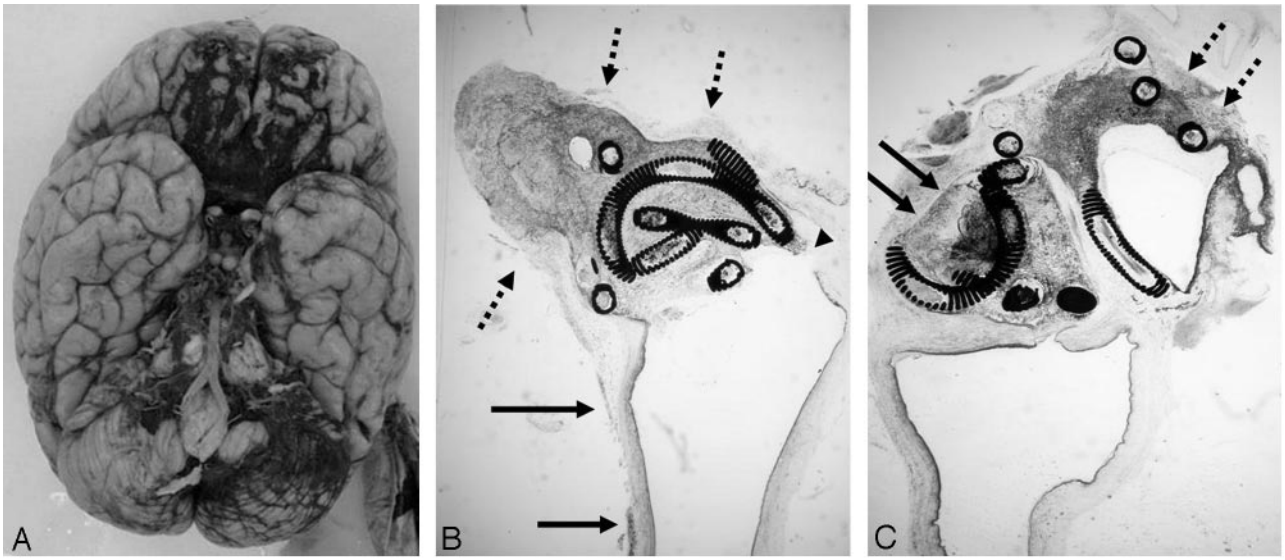

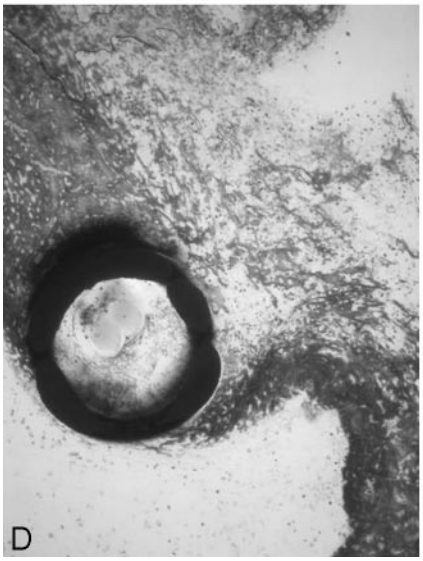

Fig 4. Postmortem changes of the brain and aneurysm. On autopsy, massive acute subarachnoid hemorrhage was present in the basal cisterns (*A*). Moreover, massive brain swelling was found. There is no evidence for basilar artery thrombosis. Histologic presentation of plastic-embedded toluidine-stained sections of the aneurysm (*B*) shows the basal artery (*arrow*) running into the sac of the aneurysm (*dotted arrows*), which is partially occluded by coils. The lumen of the aneurysm between the coils is filled by a fibrin meshwork and erythrocytes. No signs of organization or absorption, like macrophages, fibroblasts, or capillaries, are present. Note the discontinuity of the anterior wall of the aneurysm (*arrowhead*). The basal artery and aneurysm are shown at a parasagittal level in 4 *C*. At the top left the sac of the aneurysm, (*arrow*), at the top right (ie, anterior to the basilar artery, *dotted arrows*), a fresh coagulum with longitudinally and perpendicularly oriented coils is located outside the aneurysm ventral to the basilar tip. Close view of 1 of the coils outside of the aneurysm, (*D*) surrounded by fresh coagulum, shows the nylon guide within the coil in polarized light.

coil embolization of aneurysms cannot prevent recurrent hemorrhage in all patients. The size of the aneurysm measured on pretreatment CT was very similar to the aneurysm size on pretreatment angiography. Nevertheless, we cannot completely exclude that rebleeding of the aneurysm was caused by a larger partially thrombosed aneurysm or a component of a false aneurysm. In the presented case, no histologic signs of tissue response, such as thrombus organization, macrophages, or fibrin formation, were detected in the aneurysm. In contrast, patients who die of causes unrelated to the coil-embolized aneurysm generally have fibrin and macrophages within the aneurysm or even a thin membrane covering the orifice of the aneurysm at a similar time after treatment.[2,9,10] In certain select cases, the formation of an organized thrombus in the aneurysm does not occur. Based on our findings, an educated guess is that specially designed bioactive coils[11] will help to accelerate this organization process of the aneurysm and offer a safer and permanent occlusion of the aneurysm.

References

1. Molyneux A, Kerr R, Stratton I, et al, and the International Subarachnoid Aneurysm Trial (ISAT) Collaborative Group. **International Subarachnoid Aneurysm Trial (ISAT) of neurosurgical clipping versus endovascular coiling in 2143 patients with ruptured intracranial aneurysms: a randomised trial**. *Lancet* 2002;360:1267–74
2. Groden C, Hagel C, Delling G, et al. **Histological findings in ruptured aneurysms treated with GDCs: six examples at varying times after treatment.** *AJNR Am J Neuroradiol* 2003;24:579–84
3. Jane JA, Kassell NF, Torner JC, et al. **The natural history of aneurysms and arteriovenous malformations.** *J Neurosurg* 1985;62:321–23
4. Tsutsumi K, Ueki K, Usui M, et al. **Risk of recurrent subarachnoid hemorrhage after complete obliteration of cerebral aneurysms.** *Stroke* 1998;29:2511–13
5. Sluzewski M, van Rooij WJ, Rinkel GJ, et al. **Endovascular treatment of ruptured intracranial aneurysms with detachable coils: long-term clinical and serial angiographic results.** *Radiology* 2003;227:720–24
6. Sinson G, Bagley LJ, Flamm ES, et al. **Fatal rebleeding following coil embolization of cerebral aneurysms: the role of long-term systemic anticoagulation.** *Neuroradiology* 2001;43:398–404
7. Cognard C, Weill A, Castaings L, et al. **Intracranial berry aneurysms: angiographic and clinical results after endovascular treatment.** *Radiology* 1998;206:499–510
8. Sluzewski M, van Rooij WJ. **Early rebleeding after coiling of ruptured cerebral aneurysms: incidence, morbidity, and risk factors.** *AJNR Am J Neuroradiol* 2005 26: 1739–43
9. Bavinzski G, Talazoglu V, Killer M, et al. **Gross and microscopic histopathological findings in aneurysms of the human brain treated with Guglielmi detachable coils.** *J Neurosurg* 1999;91:284–93
10. Stiver SI, Porter PJ, Willinsky RA, et al. **Acute human histopathology of an intracranial aneurysm treated using Guglielmi detachable coils: case report and review of the literature.** *Neurosurgery* 1998;43:1203–08
11. Fujiwara NH, Kallmes DF. **Healing response in elastase-induced rabbit aneurysms after embolization with a new platinum coil system.** *AJNR Am J Neuroradiol* 2002;23:1137–44