Are your MRI contrast agents cost-effective?
Learn more about generic Gadolinium-Based Contrast Agents.
FRESENIUS KABI
caring for life

AJNR

Magnetic Stimulation in Clinical Neurophysiology. 2nd ed.

AJNR Am J Neuroradiol 2006, 27 (8) 1799-1780
http://www.ajnr.org/content/27/8/1799

This information is current as of April 19, 2024.

BOOK REVIEW

Magnetic Stimulation in Clinical Neurophysiology. 2nd ed.

M. Hallett and S. Chokroverty, eds. Philadelphia: Elsevier, Butterworth, Heinman; 2005, 580 pages, 150 figures, $125.

Since the first edition of this book, published in 1990, considerable advances have been made in the field of magnetic stimulation. This edition of the book contains 30 chapters and covers all the relevant topics in the field. The first chapter deals with the basics of electromagnetism, followed by a chapter on the basic physics and design of transcranial magnetic stimulation (TMS) devices and coils. The next few chapters address the physiologic mechanisms involved in the activation of peripheral nerves and roots and the brain, physiology and safety of repetitive TMS, and its clinical applications. The subsequent chapters deal with a variety of neurologic disorders, both central and peripheral, and also address cognitive functions, the somatosensory system, eye movements, stimulation of visual cortex, and TMS in children. The topics of intraoperative monitoring of corticospinal tract function by using TMS of the motor cortex, assessment of respiratory muscle pump, and clinical applications in patients with spinal cord injury are also addressed. It is not possible to review each of the 30 chapters, but the topics are well covered and up to date.

TMS is relatively new in the field of clinical neurophysiology and has been in use for about 20 years. During this period, the use of TMS has increased dramatically. Initially, it was used to stimulate the motor cortex to produce motor-evoked potentials (MEPs). The technique is simple and enables measurement of central motor conduction (CMC) in the corticospinal tract. Chapter 6 describes central motor conduction and its clinical applications and addresses the methods, cortical silent period, cortical motor threshold, and normal values. The best-studied neurologic condition by using TMS is multiple sclerosis, but it has been used in other neurologic diseases in which the corticospinal tract is involved. MEPs are most sensitive in cervical spondylotic myelopathy. TMS has also been used in amyotrophic lateral sclerosis and spinocerebellar ataxias. It is of special help in evaluating psychogenic weakness. Normal CMC time in a paralyzed extremity helps to confirm that the weakness is mostly psychogenic but cannot rule out a concomitant minor organic component.

Although TMS was initially used to stimulate the motor cortex, it soon became clear that it could be used for other purposes. TMS was found to help localize muscle representations and therefore could enable mapping of the motor strip. Technological advances helped in assessing excitability in a variety of ways. It was also possible to determine intracortical networks of excitation and inhibition.



In addition to the motor cortex TMS can be used to study the other regions of the brain, including the visual cortex, somatosensory cortex, and areas of the parietal and frontal cortex, including language and memory. These specific topics are discussed in detail in different chapters. TMS can be used to excite different regions of the brain as well as inhibit different regions transiently. Transient inhibition of specific areas of brain results in transient "reversible lesion" of the normal brain and is of great help in assessing the specific function of different regions of the brain. This conclusion cannot necessarily be made with MR imaging and functional MR imaging. Although they can localize the specific region for a specific task, they cannot determine whether that region is critical for that task.

By using a combination of TMS, neuroimaging, and a variety of neurophysiologic procedures—including electroencephalography, magnetoencephalography, somatosensory evoked potentials, and positron-emission tomography—it has been possible to gather important information about the pathophysiology of neurologic disorders.

The chapter on other cognitive functions addresses the current and future applications of TMS in cognitive neuroscience. The role of multitechnique approach to the study of cognitive neuroscience and the techniques of TMS in examining functional connectivity, functional interaction, and integration are described in detail. TMS is noninvasive and can be repeated at different times, and these features have proved to be invaluable in the study of learning plasticity and reorganization of function after injury and also in a variety of neurologic disorders. The use of TMS in neurorehabilitation is likely to increase in the future.

In recent years it has become evident that TMS may influence brain function even after the stimulation is finished. As a rule, slow rates of stimulation suppress function. On the other hand, rapid rates of stimulation enhance function. This feature has caught the attention of psychiatrists, and it is possible that TMS may replace electroconvulsive therapy. This has been discussed in detail in the chapter "TMS in Psychiatric Disorders."

Many other uses of TMS have been addressed in detail, but space does not permit discussion of these topics in detail. Chapters addressing evaluation of epilepsy and anticonvulsants, external modulation of visual perception by using TMS and direct-current stimulation of visual cortex, intraoperative monitoring, and clinical applications in patients with spinal cord injury are full of useful and current information.

The format of the book is quite appealing. Each chapter begins with an introduction, followed by crisp description of the topic ending with conclusion. Specific applications for routine clinical diagnosis, current state of the art in research, and new approaches to therapy are well described. The chapters are not voluminous, yet they pack a great deal of information in an easily readable style. It was enjoyable reading the book.

The book is well organized and evenly written, despite having contributions from more than 60 authors from 14 countries. The topics are covered adequately with comprehensive and current references. The disciplines interested in the role of magnetic stimulation in clinical neurophysiology will find the book immensely useful. These disciplines include neurology, physical medicine, psychiatry, and neuroscience.

The book is not meant for radiologists, though they may

find some of the topics of interest. The book is highly recommended for those using magnetic stimulation in clinical neurophysiology. Both the novice and the more experienced will find the book equally useful.

BOOK REVIEW

MR Imaging in White Matter Diseases of the Brain and Spinal Cord

M. Filippi, N. DeStefano, V. Dousset, and J.C. McGowan, eds. New York: Springer-Verlag; 2005, 478 pages, 610 illustrations, $279.

White matter lesions are ubiquitous and are the most common findings on brain MR imaging. This often leads to a laundry list of differential etiologic possibilities. Consequently, publications that attempt to clarify these findings and add more specificity to the diagnoses are welcome. *MR Imaging in White Matter Diseases of the Brain and Spinal Cord* is a relatively short, multiauthored (55 contributors) book that attempts to bring within a single volume these many diseases and their imaging appearances. In many respects, it succeeds.

The book is long on the general physics of MR and advanced applications of MR (nearly a third of the book) but short on pathologic correlates of most of the diseases illustrated. Many of the diseases described and illustrated would have benefited from inclusion of the pathologic counterparts (either histologic or gross anatomic). I was able to find illustrated pathology in just a few instances: for example in Balo concentric sclerosis; the histology and electron microscopy of the primary angiitis; the histology of 3 grades of gliomas and pleomorphic xanthroastrocytoma. This should not, however, be considered a major drawback of the book; it is mentioned with the hope that future editions of the book will include more of this type of material.

There are 5 major sections in the book: "MR Techniques and Principles," "Disorders of Myelination," "Demyelinating Diseases," "Immune-Mediated Disorders," "White Matter Disorders Related with Aging," and "White Matter Changes Secondary to Other Conditions." Multiple chapters, from 3 to 10, comprise each section.

The first third of the book, contains material on the physics of MR contrast, hardware considerations (magnets, shielding, gradient coils, radiofrequency coils, and so forth), spin-echo and gradient-echo imaging, concepts in fast imaging, magnetization transfer, diffusion imaging, perfusion imaging, functional MR, MR spectroscopy, and high-field MR. Although all of this material is readily available in other textbooks, the authors presumably felt the need to describe these basic principles for those readers who may have had little to no previous experience with MR. Some of these chapters are more complete than others but, in any event, should serve as basic introductory information.

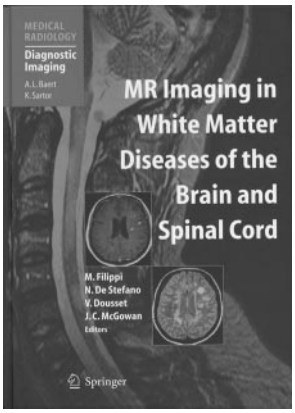

The strength of the book lies in the clinical imaging and its description. Charles Raybaud, on MR imaging of brain development, describes the problems involved in imaging premature and term infants in addition to presenting sound material on fetal brain imaging and developing/maturation of white matter. This chapter would have been strengthened by more information and illustrations of diffusion-weighted imaging and spectroscopy in infants. "Imaging of Inherited and Acquired Metabolic Brain Disorders," by Mauricio Castillo, is a good survey of these diseases and fortunately contains some spectra obtained in some patients (Canavan disease, adrenoleukodystrophy, Wilson disease). He rightly divides these entities into those associated with head sizes that are normal, enlarged, or small—this is certainly the most logical approach to these diseases, because there are similarities in their white matter abnormalities. Greater in-depth discussion of MR spectroscopy in metabolic disorders is contained in a chapter by Nicola DeStefano and Marzia Mortilla. Although this is a short chapter (12 pages), the reader is exposed to issues other than single voxel technique, such as chemical shift imaging, metabolic maps, and multivoxel analysis in MR spectroscopy. The demyelinating diseases naturally constitute a large part of the book, with, of course, multiple sclerosis (MS) leading the way. MS is discussed in 3 chapters: routine imaging, newer techniques, and variants of MS. Adequate clinical information supplements the imaging features and that helps to bring the MR findings down to clinical realities. Because most MR findings in MS are well known, the chapter by Jack Simon and Bette De Masters is particularly welcome. Here the authors nicely describe some of the historic background to what have been termed MS variants such as Devic, Schilder, Marburg, and Balo concentric sclerosis. The chapter goes a long way in clarifying what these diseases represent and how they present clinically and their MR imaging. It was particularly refreshing that in this chapter, as in some other chapters, radiologists coauthored the material with their clinical counterparts. Neuroradiologists will benefit from the side-by-side presentation of the imaging/clinical/pathologic features of these unusual diseases. Reinforced are a number of facts—such as why it is important from a treatment standpoint to distinguish Devic from MS where there can also be involvement of the cord and optic nerve, what the pathologic difference is between MS and Devic, and how magnetization transfer may potentially be used to distinguish common MS from Devic. In a similar manner the authors describe what the apparent differences are between Marburg disease and acute MS. It is not this reviewer's intent to dwell on this chapter, but it is discussed here because it shows the value of tight neuropathologic correlations, such as what stains and histologic characteristics enable the distinction between differing levels of demyelinating activity. Throughout this chapter, where MS variants are described, the differential diagnoses and the difficulties that arise in these cases are discussed.

In the chapter on acute disseminated encephalomyelitis (ADEM), in addition to describing the imaging and clinical features, the authors do try to come to grips with the issue of whether ADEM is an MS variant or a separate disease entity. This issue is troubling because, as the authors mention, as