

Are your MRI contrast agents cost-effective?

Learn more about generic Gadolinium-Based Contrast Agents.



**FRESENIUS
KABI**

caring for life

AJNR

Reply:

Richard H. Wiggins III

AJNR Am J Neuroradiol 2006, 27 (9) 1805a-1805

<http://www.ajnr.org/content/27/9/1805a>

This information is current as
of April 18, 2024.

Reply:

I would like to thank Dr. Stasolla for his kind words in reference to my article, "The Many Faces of Facial Nerve Schwannoma."¹ Although the "dural tail" sign has been reported with many pathologies, including acoustic schwannomas, none of the cases in my series demonstrated a dural tail on imaging. It is always difficult to interpret cases solely on the basis of a text description, but the case Dr. Stasolla describes in his letter is consistent with a facial nerve schwannoma. Both the clinical and imaging descriptions are consistent with the findings in my series, with a peripheral facial neuropathy in 10 cases (42%) and some type of hearing loss in 11 cases (46%), and for the radiologic description (benign osseous remodeling on CT and enhancing lesion along the course of the facial nerve on MR imaging).

I agree with Dr. Stasolla that there are a variety of etiologies that can lead to a dural tail sign in MR imaging, and I would be happy to review his case because I am always interested in seeing good head and neck cases.

Reference

1. Wiggins RH 3rd, Harnsberger HR, Salzman RL, et al. **The many faces of facial nerve schwannoma.** *AJNR Am J Neuroradiol* 2006;27:694–49

Richard H. Wiggins, III
University of Utah
Salt Lake City, Utah

A Case Meeting Clinical Brain Death Criteria with Residual Cerebral Perfusion

Cerebral blood flow (CBF) studies are often used to support the diagnosis of brain death, particularly when certain conditions such as severe facial trauma, drug toxicity, or other factors prevent reliable evaluation of the clinical examination. The absence of cerebral perfusion is consistent with brain death. Exceptional cases have been reported, however, in which CBF studies have documented residual perfusion despite the patients' meeting clinical criteria for brain death.¹ We would like to present to your readers another rare example of this dissociation between cerebral perfusion and neurologic function in which a patient's clinical examination was consistent with brain death, yet a CBF study performed shortly afterward demonstrated prominent hemispheric perfusion.

A 49-year-old man presented to our institution following cardiac arrest after a seizure. He was resuscitated in the field, with the total duration of asystole estimated to be 5 minutes. Results of urine toxicology and alcohol screens were negative. His CSF analysis was nondiagnostic. Electroencephalograms on day 1 and 3 showed low amplitude delta slowing without focality, paroxysmal activity, or interval change. A head MR imaging study on day 2

showed bilateral basal ganglionic and medial temporal lobe lesions consistent with a hypoxic-ischemic injury. He never awakened; and after an initial recovery of brain stem reflexes and respiratory effort, during the following days, he progressively lost neurologic function.

On day 5, a brain death examination was performed. His pupils were nonreactive at 4-mm diameter, and there were no corneal, cough, or gag reflexes and no ocular reflexes to either head movement or to 50 mL of ice water in each ear. He had no respiratory effort during an apnea test with a PaCO₂ of 72 mm Hg. No movements were elicited by nail-bed pressure, sternal rubbing, or supraorbital pressure. The examination was recorded as being consistent with clinical brain death.

Five hours later, a nurse reported that sternal rubbing would elicit movements of the arms, legs, head, and back. Upon the request of the organ donation personnel, a cerebral perfusion scintigraphy single-photon emission CT (SPECT) scan was ordered to confirm brain death, consistent with the policies of our institution. The CBF study unexpectedly demonstrated prominent hemispheric perfusion, and organ donation plans were suspended. See Fig 1 for representative images.

On day 6, his examination continued to show no brain stem function. During 1 of several sternal rubs, the patient's head turned to the left and his left arm rose slightly off the bed, flexed at the elbow approximately 15°, and tremored for several seconds. No other movements were observed. No further CBF, EEG, or head imaging studies were performed upon the request of the patient's family. Later that day the patient's heart was noted to be in asystole. Permission for autopsy was not obtained.

With the exception of the CBF study, the patient's examination on day 5 was consistent with many accepted criteria for the clinical diagnosis of brain death—for example, those defined by the American Academy of Neurology.² Coma, absence of brain stem reflexes, and apnea were documented, and the required prerequisites were satisfied, including neuroimaging evidence of an acute central nervous system catastrophe, the exclusion of complicating medical conditions, and a core temperature $\geq 32^{\circ}\text{C}$.

The most likely explanation for the dissociation between neurologic function and CBF in this case is that the CBF study was obtained relatively early in the course of brain death, before the intracranial pressure from cerebral edema overcame arterial pressure. A later CBF study would very likely have demonstrated the absence of perfusion. This phenomenon has been described by others,³ and some have even suggested that CBF studies performed

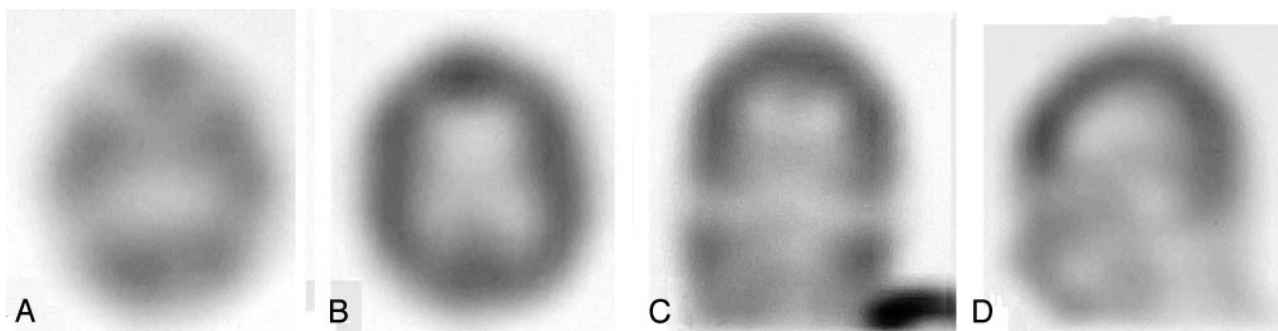


Fig 1. Representative axial (A and B), coronal (C), and sagittal (D) images from the SPECT study obtained 15 minutes after the intravenous injection of 24.5 millicuries of technetium Tc99m ethyl cysteinate dimer. Images demonstrate prominent residual hemispheric perfusion.

too early in the course of brain death may confound the process of brain death declaration.⁴

The patient's movements that initiated the request for the CBF study in this case are well-known in brain death.^{3,5} The movements may occur spontaneously or in response to stimulation, such as painful stimuli to the sternum, and are thought to be mediated at the level of the spinal cord. Such movements have included the tonic neck reflex, arm raising, and lateral head turning, similar to those observed in this patient.

We present this case to emphasize the potential difficulties that may be encountered in the evaluation of brain death. Whether to declare brain death in these rare situations is controversial, with some authorities claiming the CBF study to be a false-negative⁶ and others claiming that a CBF study showing residual perfusion is inconsistent with brain death.⁷ Physicians who deal with brain death should be aware of this possible dissociation of cerebral perfusion and the clinical brain death examination.

References

1. Flowers WM Jr, Patel BR. **Persistence of cerebral blood flow after brain death.** *South Med J* 2000;93:364–70
2. Wijdicks EFM. **Determining brain death in adults.** *Neurology* 1995;45:1003–11
3. Wijdicks EFM. **Clinical diagnosis and confirmatory testing of brain death in adults.** In: Wijdicks EFM, ed. *Brain Death*. Philadelphia, Lippincott Williams & Wilkins; 2001:61–90
4. Larar GN, Nagel JS. **Technetium-99m-HMPAO cerebral perfusion scintigraphy: considerations for timely brain death declaration.** *J Nud Med* 1992;33:2211–13
5. Saposnik G, Maurino J, Bueri JA. **Movements in brain death.** *Eur J Neurol* 2001;8:209–13
6. Flowers WM Jr, Patel BR. **Accuracy of clinical evaluation in the determination of brain death.** *South Med J* 2000;93:203–06
7. Bernat JL. **On irreversibility as a prerequisite for brain death determination.** *Adv Exp Med Biol* 2004;550:161–67

Thomas A. Ala
Southern Illinois University School of Medicine
Springfield, Ill

Matthew J. Kuhn
Anton J. Johnson
St. John's Hospital
Springfield, Ill

Poster previously presented at Annual Meeting of the American Academy of Neurology, April 16, 2002; Denver, Colo.

Radiation Worker Mortality: Intersociety Call for Survey Participation

Most physicians who use fluoroscopy during interventional procedures are aware of colleagues with cervical or lumbar spine problems. Previous surveys of interventional cardiologists and radiologists suggest a significant prevalence of orthopedic problems, very likely due, at least in part, to our work environment: long hours of wearing lead aprons and the awkward positions we sometimes must assume to treat patients.^{1–3} In addition, concern has been raised over possible radiation-related risks, including cancer and cataracts.^{4–6}

To clarify the magnitude and impact of these occupational health concerns, the Society for Cardiac Angiography and Intervention (SCAI), the Society of Interventional Radiology (SIR), the Heart Rhythm Society (HRS), and the American Society of Interventional

and Therapeutic Neuroradiology (ASITN) have formed a Joint Intersociety Working Group. This group is collaborating with the Radiation Epidemiology Branch of the National Cancer Institute (NCI) to perform several epidemiologic studies of the physician members of our societies. We need your help with these projects.

The first study that concerns you directly is a survey that all current members of the 4 societies (SCAI, SIR, HRS, ASITN) will be asked to complete. This survey will ask questions about your radiation work history and your health history as it pertains to work-related musculoskeletal disorders and radiation-related diseases. The results will be compared with a nonexposed group of physicians who do not work in an interventional environment and to the general population. All of the proposed studies have been approved by the leadership of each society, and all will be conducted with the review, approval, and supervision of the NCI Institutional Review Board. Your data will be provided the full privacy safeguards afforded to participants in NCI research studies. No individuals will be identified in the reports resulting from these studies. Your data will be collected by a nongovernmental third party, and all identifiers will be removed before data analysis.

When the survey is ready, each society will publicize it to their membership and make it available on its Website. You may also receive the survey in the mail. Please complete it and return it. The results will be of great importance and will benefit us all.

Why go to all this effort? If our work environment is causing us injuries, then it must be modified, but this change will not happen unless we can demonstrate that the problem is real. Scientifically valid results will be obtained only if there is a very high response rate to the survey. This is why we need your help.

References

1. Ross AM, Segal J, Borenstein D, et al. **Prevalence of spinal disc disease among interventional cardiologists.** *Am J Cardiol* 1997;79:68–70
2. Machan L. **A web-based survey of neck and back pain amongst interventional radiologists.** Presented at: Annual Meeting of the Society of Cardiovascular and Interventional Radiology; March 3–8, 2001; San Antonio, Tex
3. Goldstein JA, Balter S, Cowley M, et al. **Occupational hazards of interventional cardiologists: prevalence of orthopedic health problems in contemporary practice.** *Catheter Cardiovasc Interv* 2004;63:407–11
4. Finkelstein MM. **Is brain cancer an occupational disease of cardiologists?** *Can J Cardiol* 1998;14:1385–88
5. Vano E, Gonzalez L, Beneytez F, et al. **Lens injuries induced by occupational exposure in non-optimized interventional radiology laboratories.** *Br J Radiol* 1998;71:728–33
6. Junk A, Haskal ZJ, Machan L, et al. **Cataract in interventional radiology: an occupational hazard?** Paper presented at: Annual Meeting of the Society of Interventional Radiology; April 21, 2004; Phoenix, Ariz

James Goldstein
Society for Cardiac Angiography and Intervention

Donald L. Miller
Society of Interventional Radiology

David Haines
Heart Rhythm Society

John Barr
American Society of Interventional and Therapeutic Neuroradiology

Allan Ross
American College of Cardiology