

Are your **MRI contrast agents** cost-effective?

Learn more about generic **Gadolinium-Based Contrast Agents**.



**FRESENIUS  
KABI**

caring for life

**AJNR**

**Clinical Magnetic Resonance Imaging  
e-edition**

*AJNR Am J Neuroradiol* 2007, 28 (3) 597-600  
<http://www.ajnr.org/content/28/3/597>

This information is current as  
of April 18, 2024.

Chapters 4 and 8 provide a welcome and thorough discussion of underlying physiologic principles, including animal studies correlating histology with ischemic penumbra, which should remain pertinent despite future advances in human neuroprotective trials. Chapter 5, however, would have benefited from a more in-depth discussion of the potential future role of “vulnerable plaque” imaging in assessing stroke risk. Table 13.2 offers a good summary of DWI studies of lacunar stroke. Chapter 16 provides an off-the-beaten-path discussion of more diffuse global hypoxic-ischemic injury.

Stroke imaging is, without doubt, a very hot topic, and there are numerous current and in-press publications vying for the readers’ attention (as well as their professional fund budget!). Recent related texts—each with strengths and weaknesses of their own—include the 2-volume *Neuroimaging Clinics of North America: Stroke*, edited by M.H. Lev (Elsevier, 2005), and *Acute Ischemic Stroke: Imaging and Intervention*, edited by R.G. Gonzalez, J.A. Hirsch, W.J. Koroshetz, et al (Springer, 2006). Inherent in any textbook on stroke imaging is the risk that the material will become quickly dated. Despite this peril, *Magnetic Resonance Imaging in Ischemic Stroke* has largely enduring value to both clinical neuroradiologists and researchers interested in advancing acute stroke therapy through imaging triage. It addresses timeless pathophysiologic mechanisms and explores their clinical context and hence should continue to complement other textbooks as stroke neuroimaging progresses—by using not only MR imaging but also CT and other techniques.

## BOOK REVIEW

### Clinical Magnetic Resonance Imaging e-edition

Robert R. Edelman, John R. Hesselink, Michael B. Zlatkin, John V. Crues, III, eds. Vol 1–3. 3rd ed. Philadelphia; Saunders: 2006, 3649 pages, \$599.

As the applications for MR imaging expand, the number of publications and books on MR imaging increases logarithmically. The newest entry is the 3rd edition of *Clinical Magnetic Resonance Imaging* edited by Drs. Edelman, Hesselink, Zlatkin, and Crues. This 3649-page 3-volume text contains contributions from 251 authors, many of whom are leaders in the world of diagnostic radiology and MR imaging physics. These books cover the entire spectrum of MR imaging from the basics to all of its current clinical applications (heart, vascular system, brain, spine, head/neck, chest, breast, body, and musculoskeletal); in fact, it is so complete in the descriptions of each area that reviewing the text in detail would consume half an issue of the *AJNR*. So for the purposes of the *Journal* and the neuroimaging audience, this review will cover that portion of volume 1 that includes the physics, instrumentation, and

advanced techniques and of volume 2 that deals with brain, head/neck, and spine imaging. Volume 3 (not reviewed) deals with body and musculoskeletal MR imaging. Note is made that with the purchase of this publication, on-line access is possible with a PIN code given at the time of purchase.

Volume 1 begins with a 22-page summary of the history of MR imaging. Names and pictures of major figures in its development, along with a synopsis of each person’s contribution, constitute the first part of this chapter. You will now know what Jean Baptiste Joseph Fourier looked like and exactly why the Fourier transfer is so fundamental to current imaging. How about the appearance of Bloch, Purcell, Lauterbur, Henning, Mansfield, Rabi, Pauli, Gorter, and Damadian among others and what their specific contributions were or who first used the term “nuclear MR” in a publication? In addition, later you will view some of the very first images from the original MR imaging units and pictures of the scanners themselves, which became available in the late 1970s. Included are figures of the basic pulse sequences, and the names that the major MR imaging companies gave to their sequences. The stages of MR imaging development from the 1920s to its present status makes for fascinating reading, and 3 boxes outline the historic development of MR imaging and the Nobel Prizes (13 in total) awarded to those in physics, chemistry, and medicine who contributed to the development of MR imaging. This chapter was an excellent way of beginning a walk through all aspects of MR imaging.

Following the introductory/historic chapter, 7 of the next 8 chapters (226 pages) are devoted to the physical underpinnings of routine clinical MR imaging. The chapters, in order, are “Basic Principles,” “Practical Considerations and Image Optimization,” “Instrumentation” (magnet/gradients/receiver coils), “Pulse Sequence Design,” “Advanced Imaging Techniques,” and “Parallel Imaging Methods.” Why a chapter on the “Biochemical Basis of MR of the Cerebral Hemorrhage” got tossed in the middle of these chapters is not clear; it would have been better to integrate that information into the chapter in book 2 on “Intracranial Hemorrhage.” The points in the basic principles and practical considerations are familiar to almost all those involved with MR imaging on a daily basis; nonetheless, a periodic review of this material, as in this book, is always of value. The graphics are crisp, and the legends for each figure are complete and understandable. Because the jargon for pulse sequences and the many techniques varies from manufacturer to manufacturer, a 2-page table of acronyms reminds us of who calls the same imaging option by different names—for example, true FISP versus balanced FFE versus FIESTA. Although this chapter is an overview, it provides solid information (eg, sampling bandwidth, trade-off of imaging parameters, higher field imaging, and so forth) in a readable fashion. Safety issues are dealt with more completely by Dr. Shellock in a chapter later in this book.

Although a clinical neuroradiologist might quickly flip past the chapters on instrumentation and pulse sequence design, there are sections that are helpful when a physicist or a technical representative of a company tosses out unfamiliar concepts and hardware considerations. In these 2 chapters, a review of siting a magnet, magnet technology, and the layering of the various coils (shield, main, gradient, and radio-frequency) is presented. Here

and throughout the entire 3-book set, the liberal use of color makes many of these graphs, artists' drawings, and photographs more understandable. With the information in this section, you will not be intimidated any more (or be less intimidated) with discussions about gradient duty cycles, what exactly is and how does the gradient amplifier function, how the various parts of the radio-frequency subsystem work together, section profiling, phase-encode ordering, phase effects by motion, the concepts behind parallel imaging (SMASH, SENSE) acceleration factor, and so forth. This detailed text (8 chapters) is material only an MR imaging physicist could love and will not, in all likelihood, be read from beginning to end by anyone I know. The availability of this material for ready reference, however, is a major plus of the book.

The next 430 pages remain technical in nature but speak directly to the applications of advanced imaging to clinical practice. Of interest are the following chapters: "Basis of fMRI," "DWI," "Diffusion Tensor Imaging Fundamentals," "Perfusion Imaging," "Contrast Agents," "Molecular Imaging," "MR Spectroscopy Basics," "Intraoperative and Interventional MR," "High Field MR" (basically 3T and higher),

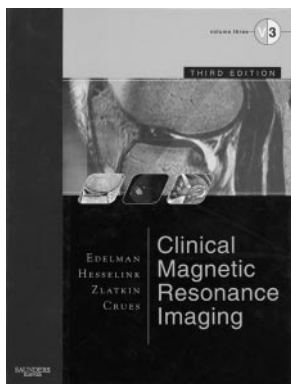
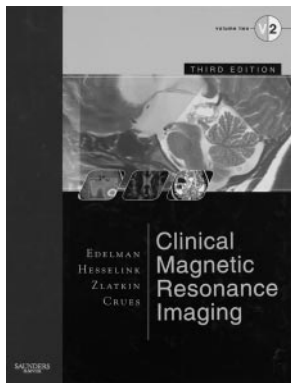
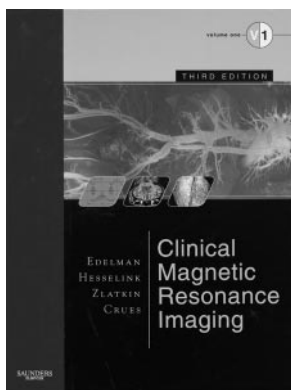
"Artifacts," "Image Processing," and "MR Safety." There is a chapter on screening MR imaging (talk about taking the debate about image screening to a higher level), and 2 chapters will attract the radiologist/administrator/entrepreneur: "The Magnetic Resonance Imaging Center and Measuring the Capacity" and "Productivity and Costs of Service of an MR Center." No longer should an SAC be primarily considered a "sub-arachnoid cyst," but rather a "service activity costing" system. So if on 1 side, there are physicists and technical people, you will be sanguine because you have gone over the areas of MR imaging physics that are bothersome; and if on the other side, there are suits firing terms like activity-based costing/budgeting at you, you will be in tune with them because an evening's reading of this chapter will give you some insights into the lexicon and processes of evaluating an imaging business.

Using MR spectroscopy as just 1 example, we can see how this set of books can appeal to basic scientists, physicists, and radiologists alike. The basic principles of MR spectroscopy are covered in detail (chapter

17) beyond what a clinical radiologist needs to know. On the other hand, I assume someone deeply involved in spectroscopy will find this amount of information useful. That chapter is contrasted with chapter 61 in book 2, in which the topic "neurospectroscopy" is covered in sufficient detail to satisfy a die-hard neuroradiologist; it contains appropriate clinical imaging, quantified data, and enough spectra to make you think you had stepped into seismographic research station. As far as this reviewer can see, that 60-page chapter covers all that you would need to know in 2006 on clinical proton MR spectroscopy. Even included is an analysis of the added value or cost/benefit of MR spectroscopy of the brain (no surprise that the authors found MR spectroscopy adds significant value).

Turning attention to the clinical aspects of MR imaging, book 2 deals with brain, head/neck, spine, and the peripheral nervous system. This book is 1325 pages long, not including the 19 pages of neuroradiology protocols, 1 set of which is protocols suggested for a GE Healthcare 1.5T scanner (Milwaukee, Wis) and 1 set for a 1.5T Siemens Symphony scanner (Erlangen, Germany). Most radiologists tend to implement scanning techniques from different sources, but certainly these parameters can be immediately put in place without fear of missing a major sequence.

The first chapter in book 2 (chapter 39) is entitled "Brain: Indications, Technique, and Atlas," but the bulk of this material (20 of 23 pages) is an atlas of MR images—T1-weighted inversion recovery images in the coronal and sagittal planes and T2-weighted fast spin-echo images in the axial plane with both a small FOV for the brain stem anatomy and a larger FOV for the entire brain. The following 3 chapters concern supratentorial adult brain tumors; brain stem, cranial nerves, and cerebellum; and pituitary gland and parasellar region; and the material presented is standard fare with a wide variety of cases shown as routine images for review and discussion. Individual philosophy dictates how to handle the more-advanced techniques in MR imaging when presenting this material. Clearly the editors opted not to integrate such material into these types of chapters but rather to present advanced techniques in separate chapters. Hence the chapters are "Perfusion and MR Spectroscopy for Brain Tumor Diagnosis," "Clinical Applications of fMRI," "Diffusion and Perfusion MR imaging," "Diffusion Tensor Imaging and Tractography," and "Neurospectroscopy." There is strength in presenting material this way because you are not diverted by going back and forth from routine descriptive material to advanced applications. There are several highlights worth mentioning. In Dr. Law's chapter on perfusion and MR spectroscopy for brain tumors, excellent background information on the histologic underpinning for perfusion and MR spectroscopy is presented. Then for those who plan to use both of these techniques, clear protocols are given and examples are shown for dynamic susceptibility contrast-enhanced perfusion MR imaging, multivoxel MR spectroscopy, and spectral maps. Numerous other issues are considered in this chapter, including the advantages/disadvantages of arterial spin labeling, the potential of phosphorus MR spectroscopy, and the determination of vascular permeability in brain tumors. The material is abundant and adequately shows the differentiating features of tumors and tumor mimics. This chapter will be important to all those venturing into the world of advanced MR imaging.



The stages in the evolution of intracranial hematomas and the signal-intensity alterations that accompany this evolution are described in biochemical depth in chapter 6 (book 1) and then put in a more clinical context in chapter 45. Here, sufficient background is given to appreciate the multifaceted appearance of blood in all pathologic hemorrhagic conditions (primary tumor, subarachnoid hemorrhage, trauma, metastasis, vascular malformations, and infarction; hypertensive, neonatal, and extra-axial) and mimickers of intracranial blood (fat, susceptibility changes due to air/bone, melanin, high-protein, and calcifications). A separate chapter is devoted to MR imaging of acute head trauma. It would have been beneficial to expand this material to include the long-term (ie, chronic) consequences from an imaging standpoint, rather than just dealing with acute trauma. Volume loss, selective tract degeneration, biochemical alterations (MR spectroscopy), and flow disturbances with subsequent hydrocephalus would have fit in well with the current material on head trauma.

Particularly welcome is the chapter by Drs. Friedland and Bronen on "MR Imaging of Epilepsy." The background information on classification of seizures and their etiology and a suggested decision pathway for work-up of uncontrolled and controlled seizures precede the anatomic basis for seizures. This latter area concentrates primarily on hippocampal anatomy and hippocampal sclerosis. Color drawings, histologic sections, and high-quality MR images help in the understanding of this often-confusing area. Of course, other causes of seizures are described and illustrated—that is, disruption in cortical development, tumors, vascular abnormalities, migrational defects, infection, and trauma. Surprisingly missing from this chapter are demonstrations of metabolic derangements (MR spectroscopy), tractography, fMRI, and the like. Hopefully, a future edition of this book will encompass additional advanced MR imaging in epilepsy.

The highly technical chapter in book 1, chapter 9, the "Basic Principles of fMRI," is supplemented by chapter 48 in book 2, "Practical Applications of fMRI," and chapter 60, "fMRI in Neuropsychiatric Disorders." Neuroradiologists will turn to these latter chapters when applying fMRI to their practice. Here the basic equipment/technical parameters and what the authors describe as "typical paradigms for presurgical imaging" are described. An important aspect of this chapter is the issue of incorporating fMRI into a PACS—that is, a means to offload the data into a workstation, postprocess the data, and then insinuate the new images back to the patient's file. The real borderland in fMRI is in chapter 60 ("Neuropsychiatric Disorders"), in which you begin to appreciate the immense undiscovered detail in brain function with MR imaging. This chapter is particularly intriguing because it opens up possibilities that radiologists seldom consider or in which, at least, they believe that they have no role. The authors of this chapter, all of whom have PhDs in psychology, bring to our attention current and potential future investigations in various diseases such as alcoholism, affective disorders, anxiety disorders, dementia, substance abuse, schizophrenia, and bipolar disorders. This information is unique because it is not found in other radiology/MR imaging textbooks. The editors deserve compliments for bringing this frontier material to their textbook.

In sequential chapters, stroke and cerebral ischemia, MR angiography of the head and neck, and diffusion/perfusion MR imaging are presented. As would be expected, similar information is repeated (albeit with different wording) from 1

chapter to another. This repetition is particularly true when talking of ischemic stroke and looking at the different parametric maps, and it falls into the category of learning that can be called reiteration without irritation. Under the section "DWI/PWI," other areas, such as tumor (and optimizing the site of biopsy), infection (particularly abscesses), and multiple sclerosis (MS) are briefly mentioned. Two chapters later, short but important material is presented on diffusion tensor imaging and tractography. By all indications, the techniques and imaging described here will be keys to future neuroimaging. The groundwork is laid for understanding how the techniques used allow the generation of color-coded white matter tracts. The authors then show fractional anisotropy in healthy individuals, in the normal-developing brain, and in a number of clinical conditions such as ischemia, trauma, MS, tumors, and epilepsy. In all probability once postprocessing becomes faster and this information can be used clinically in a more widespread manner, generating these types of images will be increasingly expected by our clinical colleagues.

The chapters on head/neck MR imaging (226 pages) cover the standard topics of orbital and ocular lesions, skull base/temporal bone, paranasal sinuses/nasal cavity, nasopharynx/deep facial compartments, lower face/salivary glands, and neck/lymph nodes. Although almost all of this is standard fare and can be found in other texts, it is beneficial to have this material in book 2. Each of the chapters contains imaging protocols, and in all chapters, there are useful tables and schematics containing information such as differential diagnoses, anatomic considerations, and labeled images. The MR imaging quality is good. Although it is an MR imaging text, I personally would like to have seen more CT-versus-MR imaging comparisons, particularly in the nasopharyngeal and lower neck region. Also, one of the most difficult image interpretations is the postoperative/postradiated neck. Although some of this information is found, a larger section of the neck chapter devoted to describing the various surgical procedures in the neck and the resultant imaging appearance would have been better. Because MR imaging of the neck is important, this chapter of 20 pages covering the hypopharynx, larynx, lymph nodes, thyroid, congenital lesions, and neurogenic tumors was too brief and was more of an overview than an authoritative chapter.

The spine section (257 pages) includes the following chapters: "Spine Atlas," "Spinal Cord and Intradural Disease," "Degenerative Disease," "Positional and Kinetic Spine Imaging," "Postoperative Lumbar Spine," "Pediatric Spine," "Vertebral and Paravertebral Abnormalities," and "Peripheral Nervous System." The spine anatomy is correlated with cryomicrotome sections and a plea from the authors for readers to draw out the pertinent anatomy on a sheet of paper. They even have 1 page showing someone drawing the beginning of a lumbar segment (how many readers of this chapter will actually do this is questionable). Spinal cord lesions, intradural disease, degenerative spine abnormalities, vertebral paravertebral lesions, the postoperative spine, and congenital and developmental disorders of the pediatric spine are discussed in a standard and complete fashion. An absence of diffusion imaging of the spinal cord or vertebrae reflects the current status of routine spine imaging. A separate chapter on "Positional and Kinetic Spine Imaging" gives a description of what, to this reviewer, is an underappreciated aspect of MR imaging: the



consequences of position and axial loading in imaging degenerative disease. For example, it is difficult to argue with the clinical/surgical potential of upright MR imaging, given alterations in appearance of the lumbar and cervical spine when prone-versus-upright images are evaluated.

Book 2 ends with a chapter that details information that could, in the near future, be a major source of nervous system imaging, MR imaging of the peripheral nervous system. Although Drs. Maravilla and Bowen have reviewed this subject elsewhere in the past, this chapter nicely brings together techniques, proper pulse sequences, the microscopic structure of peripheral nerves, the anatomy of the brachial plexus/lumbosacral plexus, and the myriad lesions involving the plexi and peripheral nerves.

Although the price of this 3-volume set of books along with the Internet access is hefty (\$599.00), it saves buying multiple individual textbooks. The material presented is complete, beautifully displayed, and well written. It is considered by this reviewer to be the prime publication resource in MR imaging today.

---


## BOOK REVIEW

### Neuroradiology Companion: Methods, Guidelines, and Imaging Fundamentals, 3rd ed.

Mauricio Castillo, ed. Philadelphia: Lippincott Williams & Wilkins: 2005, 428 pages, \$69.95.

**N**euroradiology Companion: Methods, Guidelines, and Imaging Fundamentals is the third edition of this paperback book that has slowly become a “must read” for all radiology residents before the start of their first neuroradiology rotation. As in the other editions, the author has achieved the goal of distilling the most basic and important material in neuroradiology into a concise book that can be easily read in a few hours. The book has increased in size from the previous edition by 60 pages; however, the changes made are well worth the additional reading.

The revisions made are primarily focused on the advances in neuroimaging that have taken place since the last edition, most of which have occurred in brain imaging. These changes include a more extensive and updated CT and MR protocols section to reflect technologic advances and the inclusion of images, data, and facts concerning advanced techniques such as MR spectroscopy, diffusion tensor imaging, MR perfusion imaging, and CT angiography. The section on MR imaging compatibility issues appropriately references MR imaging safety Websites, rather than trying to devise a list of commonly used devices; and the sections dealing with sedation, anxiolysis, and



drugs important to neuroimaging were expanded with discussions on how to manage a patient taking medications that increase bleeding time who requires a lumbar puncture and a patient taking drugs that lower seizure threshold before myelography. There are more than 600 new images.

The book is divided into 2 major parts. Part 1 is entitled “Imaging Protocols and Guidelines” and contains 7 chapters. These chapters deal with CT and MR imaging protocols, myelography, diagnostic conventional angiography, sedation and anxiolysis, drugs important in neuroimaging, and MR imaging compatibility issues. Part 2 is entitled “Imaging Fundamentals” and is divided into 3 sections: “Brain,” “Spine,” and “Head and Neck.” There are 24 chapters that include information on trauma, stroke, nontraumatic hemorrhages, aneurysms, vascular malformations, extra-axial tumors, intra-axial tumors, infections and inflammations, leukodystrophies, metabolic disorders, degenerative and iatrogenic disorders, congenital malformations, neurocutaneous syndromes in the brain section, degenerative disease, tumor and tumor-like conditions, vascular disorders, infections and inflammations, trauma, congenital malformations, brachial plexus in the spine section, neck masses, sinonasal cavities, temporal bone, and orbits in the head and neck section.

Each of the chapters in part 2 includes images of common diseases and entities and lists of key clinical and radiologic facts and provides 1 article for suggested reading. New chapters are those on the brachial plexus, degenerative and iatrogenic brain disorders, and metabolic brain disorders. The chapter “What Study to Order” was eliminated, though I believe this was an extremely useful chapter for trainees.

The major strengths of this book are similar to those of the previous edition and are its high-quality images, a concise text that summarizes key clinical and radiologic facts of each entity, its organized structure that allows for quick localization, and its brevity. This book is valuable for a resident who has had little exposure to neuroradiology. In a few hours, the trainee can experience the full breadth of common neuroradiologic entities as well as learn the important issues regarding imaging protocols and guidelines. The index is extensive and accurate.

There are only a few minor weaknesses. In the MR imaging compatibility section, it would be relatively easy to add a list of those devices that are known not to be safe. Some of the images could have been magnified and would not have resulted in an increase in the number of pages. There is no discussion of the standard nomenclature for lumbar disk herniations, and a few minor mistakes are noted. Figure 21–21 indicates a rightward disk herniation when in fact it is a leftward disk herniation. Figures 16–3 and 16–4 are more representative of adrenoleukodystrophy than “metachromatic leukodystrophy” indicated in the captions.

This companion is highly recommended for residents in radiology, neurology, and neurosurgery. In fact, I routinely recommend this book as a first read for all residents before their first rotation in neuroradiology. I also believe this book can serve as a quick resource for more experienced radiology residents and fellows. It can be used for quick access to imaging protocols and guidelines and can serve as a review before board examinations.