

Are your MRI contrast agents cost-effective?

Learn more about generic Gadolinium-Based Contrast Agents.



**FRESENIUS
KABI**

caring for life

AJNR


Pediatric Neuroradiology: Brain, Head, Neck, and Spine (2 Volumes)

AJNR Am J Neuroradiol 2007, 28 (7) 1420-1421

doi: <https://doi.org/10.3174/ajnr.A0577>

<http://www.ajnr.org/content/28/7/1420>

This information is current as
of April 9, 2024.



with understanding evidence, organizing acute stroke care, and general supportive acute stroke care.

In 14 chapters organized according to either the major causes of stroke or to therapeutic and preventive issues arising either because of a stroke or with the aim of preventing a stroke, Hankey has compiled a comprehensive data base of available literature. He then provides and analyzes in a meticulous fashion the available

evidence and its quality while also providing, in most cases, Forest plots of the reported studies. For the reader, this greatly simplifies a comparison of the reported results. Along with these clearly presented facts, he then adds his interpretation of the data, as well as a view on their implication for clinical practice. The unusual combination of an inclusive literature review with an analysis by someone with, “clinical experience, acumen and common sense” (from his preface) is rare.

This is not a book for the bedside table; it is packed with facts that, while clearly presented, require concentration and contemplation for full understanding and application. It is a book that should be available in the “trenches” wherever acute stroke diagnosis and care are provided. I would suspect that its value to students and house officers will be clearly demonstrated by the number of copies that mysteriously disappear from departmental libraries, finding their way into on-call rooms and other haunts regularly occupied by those having first-line responsibility for making decisions about the diagnosis and treatment of stroke. No matter what their level of training or experience, this book will be useful to anyone interested in the topic of stroke.

The only meaningful criticism of this book, as recognized by Hankey, is that it will over a relatively short time become dated. It will remain, however, an extremely useful source as long as it is available.

DOI 10.3174/ajnr.A0579

BOOK REVIEW

Pediatric Neuroradiology: Brain, Head, Neck, and Spine (2 Volumes)

P. Tortori-Donati and A. Rossi, eds. New York: Springer; 2005. 1752 pages, 4480 illustrations, \$779.

For years, the standard against which I have judged texts on the subject of pediatric neuroimaging has been A. J. Barkovich's classic *Pediatric Neuroimaging*, currently in its fourth edition and still going strong. After having read the impressive new opus, *Pediatric Neuroradiology*, by Tortori-Donati and Rossi, I may very well have to rethink that standard. In creating this textbook, Tortori-Donati and Rossi set out with the audacious

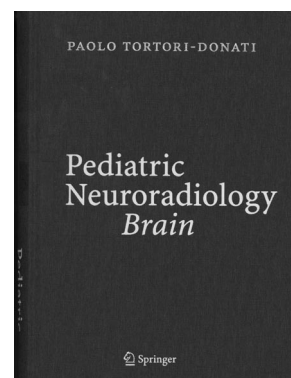
goal of creating perhaps the most comprehensive and sweeping textbook on the subject of pediatric neuroimaging to date, and it appears as if they have done just that.

The 2-volume text spans 45 chapters and 1752 pages. The larger first volume, which accounts for more than two thirds of the book's content, is devoted to imaging of the brain. The second volume covers imaging of the pediatric head, neck, and spine. Topics reviewed in the 27 chapters of the first volume include embryology of the brain, MR of the preterm infant brain, neonatal hypoxic-ischemic encephalopathy, vascular malformations (including a review of endovascular treatment), brain tumors, neurodegenerative disorders, the phakomatoses, and epilepsy. The last 5 chapters of volume 1 focus on state-of-the-art brain imaging techniques and feature in-depth and up-to-date discussions on MR spectroscopy; diffusion-weighted, perfusion-weighted, and functional MR imaging; brain sonography; and MR imaging of the fetal central nervous system.

The considerably shorter second volume is divided nearly evenly between head and neck imaging and spine imaging. Both parts begin with a chapter reviewing embryology and conclude with chapters covering sonographic applications in the head, neck, and spine (including chapters on prenatal sonography). Topics covered in the head and neck section include abnormalities of skull development, craniosynostoses, imaging of the orbits and temporal bones, sinonasal diseases, and cervicofacial vascular malformations. The section on spine imaging includes chapters on congenital malformations, spine and spinal cord tumors, infectious and inflammatory disorders, trauma, and arteriovenous shunts.

A considerable emphasis is placed on understanding imaging in the context of current knowledge about disease pathogenesis, which results in a richer understanding of several diseases that neuroradiologists see on a day-to-day basis. In addition, several topics that have in the past been dealt with superficially in other texts finally get much-deserved attention in this book. Hemolymphoproliferative diseases and treatment-related disorders, rare phakomatoses, pediatric sellar and suprasellar disorders, and spinal arteriovenous shunts are among the more esoteric topics that receive their own chapters. Thankfully, the authors do not allow themselves to become bogged down by excessive minutiae, which is a potential danger in writing a textbook of this scope. Although topics are discussed in exceptional detail within each chapter, none of the information seems superfluous.

The chapters follow a set format and are generally well organized. Within each chapter, sections and subsections are individually numbered. For example, the chapter on brain tumors (Chapter 10) includes discussions on intra-axial tumors and extra-axial tumors, labeled sections 10.2 and 10.3, respectively. The section on intra-axial tumors is further subdivided into subsections on tumors of the posterior cranial fossa (Section 10.2.1) and tumors of the cerebral



hemispheres (Section 10.2.2), and so on. The first page of each chapter presents a table of contents, which lists the sections and subsections contained within and their respective page numbers, making it fairly easy to locate a specific topic within any given chapter.

Given the large number of contributing authors (57 to be exact) and the wide range of topics covered, one might expect to encounter significant variability in organization, content, and quality among each of the individual chapters, but I did not get this sense as I read the book, which is a testament to the editorial efforts of Tortori-Donati and Rossi. Not one of the chapters felt out of place or particularly lacking when held up against the others. This is not to say, however, that certain chapters do not stand out.

Perhaps the most impressive contribution to the textbook is the chapter on metabolic disorders by Dr Zoltán Patay, which spans 181 pages and could easily make up an entire textbook on its own. This chapter is among the most exhaustive reviews of metabolic brain disorder imaging I have come across, yet Patay's treatment of the subject keeps the material interesting and accessible. The chapter is well organized, first presenting an overview of metabolic disease and describing a number of approaches to classifying metabolic disorders. This is followed by discussions on the use of various imaging modalities in metabolic disease work-ups, clinical and laboratory aspects of the disorders, and management. The last two thirds of the chapter are devoted to discussing individual metabolic disorders (more than 60 of them, in fact) and their imaging features. One section within the chapter that I found particularly useful provided a systematic approach to analyzing MR images in metabolic disorders, including a table of important structures to analyze and a list of specific disorders with suggestive or pathognomonic patterns on MR imaging. I suspect that this will be the first textbook I turn to the next time I encounter a complicated case of metabolic disease in a child.

Figure quality throughout the book is, for the most part, excellent, and a healthy number of photographs, schematic diagrams, and tables are included, which substantially enhance the readability of the text. Unfortunately, I encountered a smattering of errors while perusing the figure legends, including some mislabeled figure parts. Occasional figures might also have benefited from additional annotations (though this is an entirely subjective complaint). These are relatively minor squabbles, and for the first edition of a textbook of this scope, a few copyediting errors are to be expected. Hopefully these issues will be addressed in future editions.

The great depth and detail with which topics are discussed within this book can at times be overwhelming, particularly to the casual reader. This is not the first textbook I would reach for if I were in search of a few quick and easily digested facts about a specific disease entity, but it was not the authors' intent for this to be such a book. There are a number of books in print that already serve that purpose. As such, this is probably not the ideal first textbook on pediatric neuroradiology for radiology residents, general radiologists, or even first-year neuroradiology fellows, though the book is written such that the material is certainly understandable at a basic level. As Tortori-Donati writes in his preface, the book is "deliberately encyclopedic," and therein resides the true strength of *Pediatric Neuroradiology*. The amazing lengths to which Tortori-Do-

nati and the contributing authors have gone to provide the most up-to-date and comprehensive information possible make this book an invaluable resource to those whose interest in pediatric neuroimaging extends well beyond surface comprehension. For pediatric neuroradiologists and neuroradiologists with a genuine enthusiasm for pediatric neuroimaging, I could not recommend this book more highly. *Pediatric Neuroradiology* is a most welcome addition to the existing canon of texts on the subject and one that I expect will withstand the test of time.

DOI 10.3174/ajnr.A0577

BOOK REVIEW

Atlas of Morphology and Functional Anatomy of the Brain

T. Scarabino, U. Salvolini, F. DiSalle, H. Duvernoy, and P. Rabischong, eds. Berlin, Germany: Springer; 2006. 127 pages, 166 illustrations, \$99.00.

The rapid expansion of advanced imaging techniques is generating new insights into the clinical neurosciences and has fostered growth in the field of neuroradiology. Techniques, such as functional MR imaging (fMRI) and diffusion tensor imaging (DTI), have already begun to have significant effect on presurgical risk assessments in patients with brain tumors and other respective lesions. Evolving applications of brain mapping for functional neurosurgery and for understanding cognitive and neurodegenerative disorders are just over the horizon. Driven by these imaging developments, neuroradiology is shifting its emphasis toward a greater understanding of the pathophysiology of neurologic disease and the implications of such to brain functions. The integral nature of clinical neuroimaging suggests that neuroradiologists should acquire a thorough appreciation of brain functional organization and the capacity to extract information about brain pathology and disease-induced brain dysfunction, provided by 2D image data. Deeper insights into functional brain imaging anatomy are the critical first steps in realizing the potential of functional imaging.

The *Atlas of Morphology and Functional Anatomy of the Brain*, edited by T. Scarabino and U. Salvolini, in collaboration with F. DiSalle, H. Duvernoy, and P. Rabischong, is a resource that answers the call of functional neuroradiology training. The atlas includes more than 160 images detailing sulcal and gyral landmarks and functional anatomic regions using both cadaveric and normal imaging anatomic designations. The material is directed at radiolo-

