

Are your MRI contrast agents cost-effective?

Learn more about generic Gadolinium-Based Contrast Agents.



**FRESENIUS
KABI**

caring for life

AJNR

CT Recognition of Lateral Lumbar Disk Herniation

Alan L. Williams, Victor M. Haughton, David L. Daniels and Robert S. Thornton

AJNR Am J Neuroradiol 1982, 3 (3) 211-213

<http://www.ajnr.org/content/3/3/211>

This information is current as of April 17, 2024.

CT Recognition of Lateral Lumbar Disk Herniation

Alan L. Williams¹
Victor M. Haughton
David L. Daniels
Robert S. Thornton

Although computed tomography (CT) has been shown to be useful in diagnosing posterolateral and central lumbar disk herniations, its effectiveness in demonstrating lateral herniated disks has not been emphasized. The myelographic recognition of those herniations may be difficult because root sheaths or dural sacs may not be deformed. A total of 274 CT scans interpreted as showing lumbar disk herniation was reviewed. Fourteen (5%) showed a lateral disk herniation. The CT features of a lateral herniated disk included: (1) focal protrusion of the disk margin within or lateral to the intervertebral foramen; (2) displacement of epidural fat within the intervertebral foramen; (3) absence of dural sac deformity; and (4) soft-tissue mass within or lateral to the intervertebral foramen. Because it can image the disk margin and free disk fragments irrespective of dural sac or root sheath deformity, CT may be more effective than myelography for demonstrating the presence and extent of lateral disk herniation.

The recognition of a herniated lumbar intervertebral disk by myelography, even with water-soluble contrast agents, may be difficult where the anterior epidural space is large, such as at L5-S1, or when the herniation is lateral [1-5]. Computed tomography (CT) has been shown to be effective in the diagnosis of herniated disks [6-10], particularly the central and posterolateral ones. We illustrate the usefulness of CT in the diagnosis of lateral lumbar disk herniations.

Materials and Methods

During a 3 year period, 1,523 patients with low back and/or sciatic pain were studied with CT at the Milwaukee County Medical Complex. Our CT scanning techniques have been described [6, 8, 10]. In 274 patients (18%), evidence of a herniated lumbar disk was seen by CT. We reviewed the CT scans in these 274 patients to determine the frequency and CT appearance of lateral lumbar disk herniation. We defined a lateral disk herniation as one within or lateral to the intervertebral foramen. These criteria were satisfied in 14 patients. Six of them were confirmed surgically and eight were managed conservatively.

Results

In the 14 cases, displacement of fat within the intervertebral foramen was identified in each one, whereas a dural sac deformity was noted in only one. Focal protrusion of the disk margin resulting in narrowing of the intervertebral foramen was seen in 12 patients, and a soft-tissue mass lateral to the foramen was identified in three.

Representative Case Reports

Case 1

A 40-year-old woman had 6 weeks of severe left sciatic pain. Neurologic examination revealed left L5 and S1 radiculopathy. CT demonstrated displacement of fat within the left L5-S1 intervertebral foramen and a large soft-tissue mass lateral to the foramen (fig. 1).

This article appears in the May/June 1982 issue of *AJNR* and the August 1982 issue of *AJR*.

Received September 22, 1981; accepted after revision December 28, 1981.

Presented at the annual meeting of the American Society of Neuroradiology, Chicago, April 1981.

¹All authors: Department of Radiology, Medical College of Wisconsin, and Milwaukee County Medical Complex, 8700 W. Wisconsin Ave., Milwaukee, WI 53226. Address reprint requests to A. L. Williams.

AJNR 3:211-213, May/June 1982
0195-6108/82/0303-0211 \$00.00
© American Roentgen Ray Society

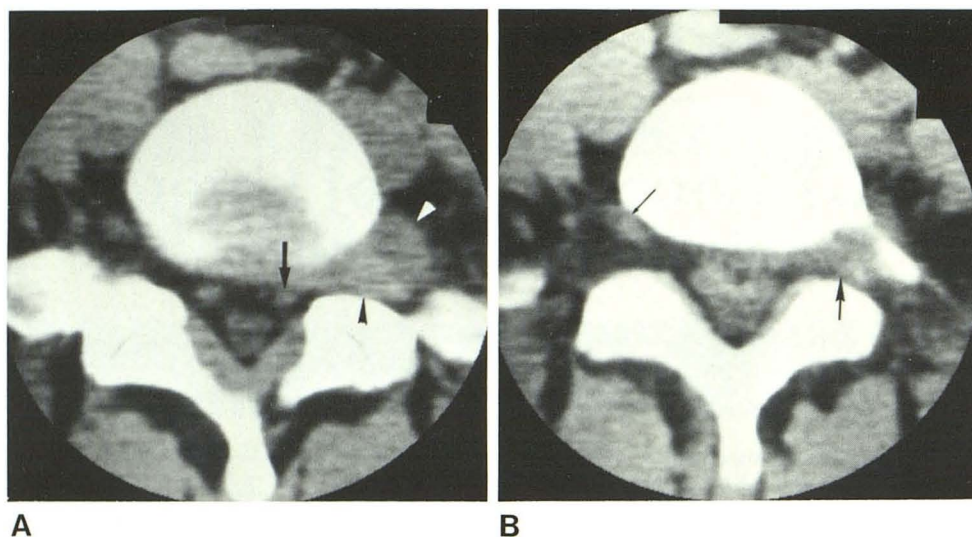


Fig. 1.—Case 1. Lateral L5–S1 disk herniation. **A**, CT image through disk. Large soft-tissue mass (*arrowheads*) within left intervertebral foramen and paravertebral tissues. Fat within foramen has been displaced. Left S1 root sheath (*arrow*) contacted by extruded disk material and displaced posteriorly. **B**, 5 mm cranial. Displacement of fat within left intervertebral foramen by disk material (*large arrow*). Ipsilateral L5 nerve obscured, although contralateral one (*small arrow*) is clearly demonstrated.

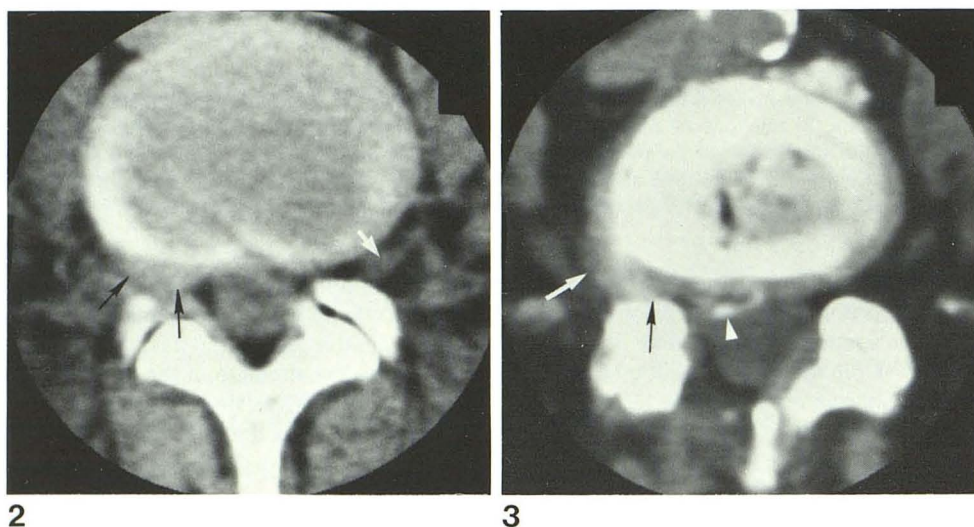


Fig. 2.—Case 2. Lateral L4–5 disk herniation. Disk protrudes focally (*black arrows*), displacing fat within right intervertebral foramen. L4 nerve, although demonstrated clearly on contralateral side (*white arrow*), is obscured on right. Lack of dural sac deformity.

Fig. 3.—Case 3. Lateral L4–5 disk herniation. Focal disk protrusion (*arrows*) contains calcification (*arrow-head*) and displaces fat within right intervertebral foramen.

Myelography was not performed. The patient underwent laminectomy, which revealed three large extruded disk fragments within and lateral to the intervertebral foramen.

Case 2

A 52-year-old man had sudden onset of right sciatic pain. Right L4 radiculopathy was detected on neurologic examination. CT demonstrated focal protrusion of the L4–5 disk with displacement of fat within the right intervertebral foramen (fig. 2). Myelography was not performed. Laminectomy confirmed lateral disk herniation.

Case 3

A 64-year-old woman had acute onset of right sciatica. Neurologic examination suggested right L4 and L5 radiculopathy as well as a possible thoracic cord lesion. A gas myelogram, obtained to evaluate the conus medullaris and lower thoracic cord, demon-

strated some deformity of the dural sac on the right at L4–5, but no thoracic or upper lumbar abnormality. A subsequent CT scan revealed focal protrusion of the L4–5 disk with displacement of fat within the right intervertebral foramen (fig. 3). At operation, lateral disk herniation with compression of the L4 and L5 nerve roots was identified.

Discussion

In 8% of patients, laminectomy for suspected disk herniation fails to reveal any abnormality of the disk, despite clinical evidence of nerve root irritation [11]. Sixteen percent of patients with a negative disk exploration subsequently have an extruded disk fragment within or lateral to the intervertebral foramen [11]. Disk protrusions at the lateral-most part of the intervertebral foramen cause nerve compression [12], but may not produce a myelographic defect because the root sheath terminates near the dorsal

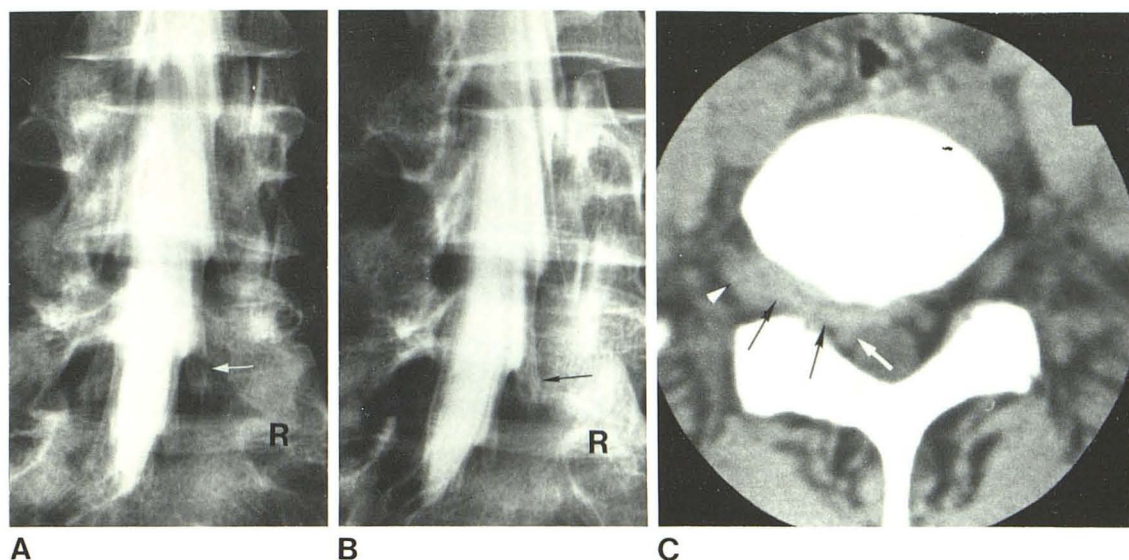


Fig. 4.—Lateral L5-S1 herniated disk on myelography and CT. **A** and **B**, Oblique spot films from metrizamide myelogram. Satisfactory opacification of right S1 root sheath (arrows). No deformity of dural sac or displacement of root sheath. **C**, Axial CT image at L5-S1 level. Extensive lateral disk herniation (black arrows) displaces fat within intervertebral foramen and anterior epidural space. Right L5 nerve (arrowhead) displaced laterally and right S1 root sheath (white arrow) displaced posteriorly. Lack of dural sac deformity despite extensive disk herniation. (This case, courtesy of O. Petter Eldevik, Ulleval Hospital, Oslo, Norway, was included because few of our patients with herniated disks were studied with both myelography and CT.)

root ganglion, which lies within the intervertebral foramen. Thus, lumbar nerve root sheath opacification with metrizamide may be normal despite a lateral disk herniation [3] (fig. 4). However, CT visualizes the disk margin and any extruded disk fragments that may lie within or lateral to the foramen (fig. 1). One would anticipate that in cases of lateral disk herniation, CT would be superior to myelography, as one prospective study showed [13]. Further prospective studies comparing these two methods are desirable.

MacNab [11] indicated that incomplete exploration of the nerve root explained the negative findings at laminectomy in some patients and emphasized that the nerve root should be fully exposed in all patients in whom more central nerve root compression is not found [11]. Our neurosurgical and orthopedic colleagues have found CT extremely useful in planning surgical exploration in patients with sciatica, particularly when CT has demonstrated disk protrusion or extruded disk fragments within or lateral to the foramen. Good correlation between neurologic examination and CT in the patient with a herniated disk, whether lateral, posterolateral, or central, may obviate other diagnostic tests.

To summarize, the diagnosis of lateral disk herniation by CT may be made when there is: (1) focal protrusion of the disk margin within or lateral to the intervertebral foramen; (2) displacement of fat within the intervertebral foramen; (3) absence of dural sac deformity; and (4), in some cases, soft-tissue mass lateral to the intervertebral foramen. In some instances, the soft-tissue findings suggesting lateral herniated disk have been due to epidural lymphoma and neurofibroma. In most cases, careful examination of the adjacent osseous structures, density measurements of abnormal soft tissue adjacent to the disk, and a detailed clinical history should assist the radiologist in arriving at the correct diagnosis.

REFERENCES

1. Shapiro R. *Myelography*, 3d ed. Chicago: Year Book Medical, 1975:377
2. Shapiro R, Galloway SJ, Goodrich I. The evaluation of the patient with a negative or indeterminate myelogram. In: Post MJD, ed. *Radiographic evaluation of the spine*. New York: Masson, 1980:603-622
3. Sackett JF, Strother CM. *New techniques in myelography*. Hagerstown, MD: Harper & Row, 1979:84
4. Finneson BE. *Low back pain*. Philadelphia: Lippincott, 1973:59-60
5. Epstein BS. *The spine*, 4th ed. Philadelphia: Lea & Febiger, 1976:634-647
6. Williams AL, Haughton VM, Syvertsen A. Computed tomography in the diagnosis of herniated nucleus pulposus. *Radiology* 1980;135:95-99
7. Meyer GA, Haughton VM, Williams AL, Syvertsen A. Diagnosis of lumbar herniated disc with computed tomography. *N Engl J Med* 1979;301:1166-1167
8. Carrera GF, Williams AL, Haughton VM. Computed tomography in sciatica. *Radiology* 1980;137:433-437
9. Glenn WV, Rhodes ML, Altschuler EM, et al. Multiplanar display computerized body tomography application in the lumbar spine. *Spine* 1979;4:202-352
10. Haughton VM, Williams AL. *Computed tomography of the spine*. St. Louis: Mosby, 1982
11. MacNab I. Negative disc exploration—an analysis of the cause of nerve-root involvement in 68 patients. *J Bone Joint Surg [Am]* 1971;53:891-903
12. Lindblom K. Protrusions of discs and nerve compression in the lumbar region. *Acta Radiol [Diagn]* (Stockh) 1944;25:195-212
13. Haughton VM, Eldevik OP, Magnaes B, Amundsen P. A prospective comparison of computed tomography and myelography in the diagnosis of herniated lumbar discs. *Radiology* 1982;142:103-110