

Are your **MRI contrast agents** cost-effective?

Learn more about generic **Gadolinium-Based Contrast Agents**.



FRESENIUS
KABI

caring for life

AJNR

**Traumatic longitudinal atlanto-occipital
distraction injuries in children.**

R A Kaufman, J S Dunbar, J A Botsford and R L McLaurin

AJNR Am J Neuroradiol 1982, 3 (4) 415-419

<http://www.ajnr.org/content/3/4/415>

This information is current as
of April 19, 2024.

Traumatic Longitudinal Atlanto-occipital Distraction Injuries in Children

Robert A. Kaufman¹
 J. Scott Dunbar¹
 John A. Botsford²
 Robert L. McLaurin³

Traumatic atlanto-occipital dislocation with survival is possible and, in fact may be relatively more common than once thought. The spectrum of neurologic manifestations is broader than previously described and does not necessarily end in death or tragic neurologic deficit. Radiographic diagnosis of this injury may be difficult, particularly in the longitudinal distraction-dislocation type. Although several methods have been proposed to evaluate the atlanto-occipital relationship, none of these is infallible in the recognition of distraction injury in children. Immobilization rather than skeletal traction provides sufficient immediate stabilization when the dislocation at the atlanto-occipital junction is of the longitudinal distraction type. Three cases are reported: in one, death occurred early; in the second, recovery was partial, but sudden death occurred 2 years later; the third child recovered fully.

Traumatic atlanto-occipital dislocation is a rare injury of the craniovertebral junction and is thought to be immediately fatal in most instances [1]. There are but 16 well documented cases of survival following this injury; in three, death occurred within 36 hr. Nine of these 16 cases were adults. We report three children who were seen recently, two of whom survived this injury. The importance of longitudinal atlanto-occipital distraction is stressed, and several new aspects of this injury, its radiographic evaluation, and its treatment are suggested.

Case Reports

Case 1

A 5½-year-old girl was a passenger in the front seat of an auto when it hit a tree. Her head hit the dashboard and she slumped unresponsive in the front seat. She became apneic and cyanotic and immediate cardiopulmonary resuscitation (CPR) led to improvement in color.

On arrival at Children's Hospital Medical Center (CHMC) emergency room she had no palpable blood pressure, no spontaneous movement, and no spontaneous respiration. Neurologic examination revealed flaccid paralysis and absent deep tendon reflexes, but a positive response to deep pain in the lower extremities. Slight toe flexion occurred in response to plantar stimulation. Cranial nerves were intact. Her blood pressure responded to intravenous fluids and manual ventilation by resuscitation bag. She was cautiously intubated and placed on a ventilator, her neck immobilized. Bedside radiographs of the cervical spine showed longitudinal atlanto-occipital distraction (fig. 1), and the child was thought to have a brain stem contusion as well.

Within the first 10 days of admission she awoke and could respond to communication by blinking. There was some recovery of deep tendon reflexes in her lower extremities. She required posterior wiring of C1 to the occiput for atlanto-occipital stabilization. During the next 10 months she progressed slowly and eventually could vocalize weakly and move all four extremities weakly. She was alert and oriented and her mental status was normal. However, she suffered from speech difficulties and was unable to swallow solid foods. She continued to experience occasional nocturnal dusky episodes and required an apnea monitor at home. She died suddenly 2 years after injury. No autopsy was performed.

Received June 12, 1981; accepted after revision January 6, 1982.

¹ Department of Radiology, University of Cincinnati College of Medicine, Children's Hospital Medical Center, Elland & Bethesda Ave., Cincinnati, OH 45229. Address reprint requests to R. A. Kaufman.

² Department of Radiology, University of Cincinnati College of Medicine, Cincinnati General Hospital, Cincinnati, OH 45267.

³ Department of Surgery, University of Cincinnati College of Medicine, Cincinnati, OH 45267.

AJNR 3:415-419, July/August 1982
 0195-6108/82/0304-0415 \$00.00
 © American Roentgen Ray Society

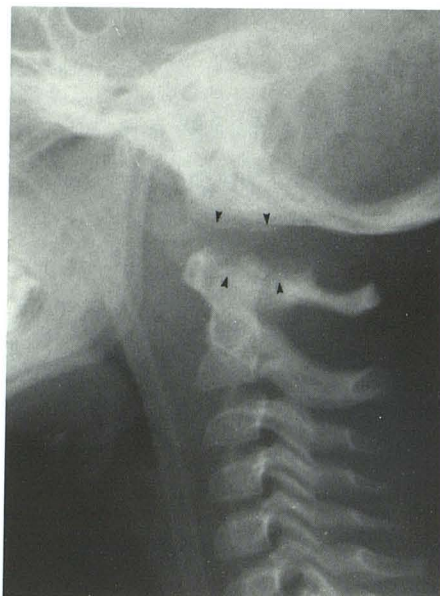


Fig. 1.—Case 1. Brow-up lateral cervical spine radiograph. Longitudinal distraction at atlanto-occipital junction and considerable prevertebral soft-tissue swelling. There is nearly 9 mm of vertical separation between occipital condyles and C1 articular facets (arrowheads) accompanied by mild anterior displacement of occiput on C1. An os odontoideum is present, and there is probably separation of posterior arches of C1 and C2.

Case 2

A 12-year-old boy was struck by a car in the left flank. He immediately became unresponsive, apneic, and his pupils dilated. Immediate CPR led to improvement in color. On arrival at CHMC emergency room he was unresponsive to commands, had no spontaneous movement or respiration, and had a blood pressure of 80/40 mm Hg. Neurologic examination revealed flaccid paralysis and absent deep tendon reflexes, but there was toe flexion in response to plantar stimulation. Cranial nerves were intact. Bedside radiographs of the cervical spine showed a longitudinal atlanto-occipital distraction (fig. 2). Sequential chest radiographs revealed mediastinal widening that increased rapidly. A peritoneal tap was positive for blood and the patient had an immediate exploratory laparotomy.

Surgery revealed massive retroperitoneal bleeding. The patient was supported with fluids and blood transfusion, but had a cardiac arrest and died about 24 hr after admission.

At autopsy there was nearly complete disruption of both the intraspinal and extraspinal supporting atlanto-occipital ligaments. This atlanto-occipital dislocation was accompanied by a 64 mm laceration at the pontomedullary junction, subarachnoid hemorrhage about the upper cervical spinal cord, and contusion of the brain stem and upper cervical spinal cord. In addition, fractures of C2 and C6 were present, as was massive mediastinal and retroperitoneal hemorrhage.

Case 3

A 7-year-old boy was struck by a car in the lower back and thigh. He lost consciousness immediately after injury, but was arousable and remained semiresponsive. On arrival at CHMC emergency room, he had spontaneous movement in the upper extremities and

spontaneous respiration, but was unresponsive to commands. Neurologic examination revealed weakness in the lower extremities, but normal deep tendon reflexes. Cranial nerves were intact. There was a 1.5 cm submental laceration, a fracture of the left superior pubic ramus, and a comminuted fracture of the proximal left femur. Bedside radiographs of the cervical spine showed longitudinal atlanto-occipital distraction (fig. 3A) with an occipital fracture (not shown), and suggested posterior ligamentous injury at C1–C2. The neck was immobilized with sandbags, and he was placed in skeletal traction for his lower extremity.

Subsequent plain film examination and laminography revealed some reduction of the atlanto-occipital distraction 5 days later (fig. 3B). He was kept immobilized by sandbags for 10 days and then placed in a cervical collar for the rest of his hospitalization.

This child was reevaluated 3 months after the injury and plain film radiography as well as cinefluorography evaluation of the atlanto-occipital junction demonstrated no instability or evidence of anterior displacement of the occiput on C1. Very mild limitation of flexion was present. No surgery was performed. He is currently free of any neurologic deficit 15 months after injury.

Discussion

On the basis of cadaver studies, Werne [2] concluded that it was necessary to sever both the tectorial membrane and the alar ligaments at the occipito-atlanto-axial articulation for atlanto-occipital dislocation to occur. He and others [3, 4] speculated that dislocation of the atlanto-occipital joint without associated fracture was rare in adults because of the strength of these supporting ligaments. In children, however, the atlanto-occipital joint is less stable than in adults, possibly because of the more horizontal plane of the joint and the smaller size of the occipital condyles [5].

While it has been thought that atlanto-occipital dislocation is an extremely rare injury [4], an autopsy study of multiple trauma victims by Bucholz and Burkhead [1] disclosed that nine of 26 cadavers with cervical spine injuries suffered atlanto-occipital dislocation, making it the most common cervical spine injury in this group. Moreover, they found that atlanto-occipital dislocation was 2.5 times more common in children than in adults. In none of the children was there an associated fracture. Six of those nine victims of atlanto-occipital dislocation were injured in motor vehicle–pedestrian accidents. These investigators suggested that children may be more susceptible than adults to atlanto-occipital injury. However, they also observed that children are more often involved in motor vehicle–pedestrian accidents than adults and that motor vehicle–pedestrian accidents seem to be a more frequent cause of this injury than vehicle–vehicle collisions.

Clinical histories and autopsy studies have suggested to some authors that hyperextension with a distraction force applied to the head is the likely mechanism of traumatic atlanto-occipital dislocation [1], while others have implicated a severe lateroflexion force [3]. The evidence for both theories is inconclusive. Because some element of hyperflexion seems likely in two of our patients who had posterior spinous process separation, we are not convinced that the hyperextension theory is correct.

Survival after traumatic atlanto-occipital dislocation appears to be quite rare, even for short periods [3, 4, 6–15].

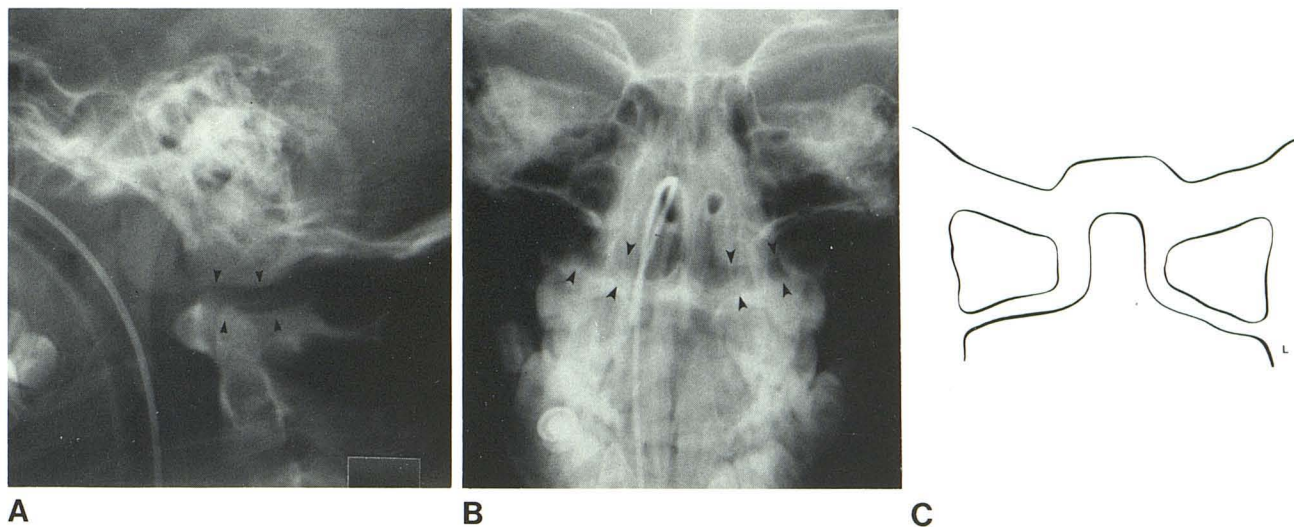
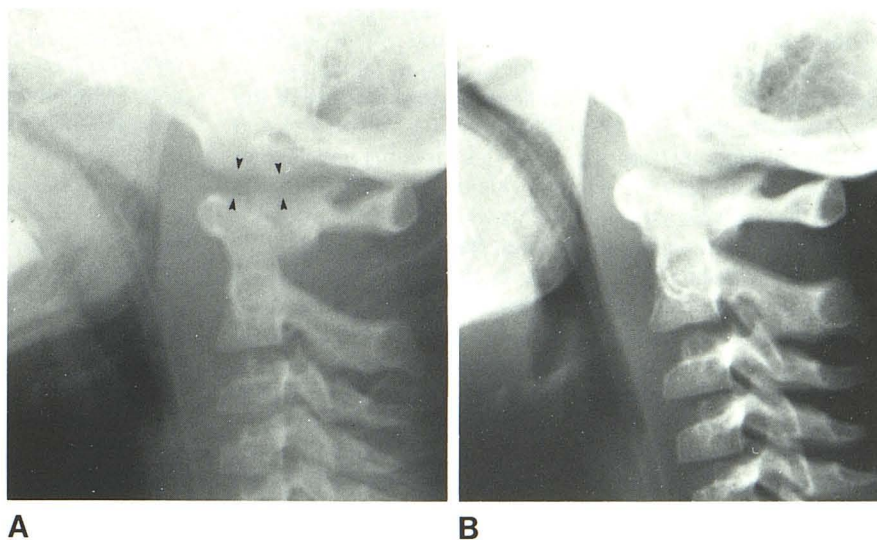


Fig. 2.—Case 2. **A**, Horizontal beam lateral skull film. Mild longitudinal atlanto-occipital distraction accompanied by prevertebral soft-tissue swelling. There is about 6.5 mm of atlanto-occipital separation (*arrowheads*). At autopsy there was complete atlanto-occipital dislocation and probable sep-

aration of posterior elements of C1 and C2. **B**, Anteroposterior skull film. Atlanto-occipital joints (*arrowheads*). Left atlanto-occipital separation is 6 mm and right is 5 mm. **C**, Magnified line tracing of **B** emphasizes greater distraction of left atlanto-occipital joint. Mild lateral subluxation of C1 on C2.

Fig. 3.—Case 3. **A**, Initial brow-up lateral film of the cervical spine. Slight vertical distraction (6 mm separation) of atlanto-occipital junction (*arrowheads*). Widening is most obvious in anterior part of joints. Considerable prevertebral soft-tissue swelling. Widening of interspinous distance at C1–C2 suggests posterior ligamentous injury. An os odontoideum is present. **B**, 5 days after injury. Diminished distraction of atlanto-occipital junction and decreased soft-tissue swelling.



Pang and Wilberger [14] recently reviewed the spectrum of clinical manifestations of atlanto-occipital dislocation in those few cases of survival. Neurologic compromise is usually significant, with cranial nerve palsy among the most common findings. There have been only two previously reported cases of dislocation with a normal neurologic examination on presentation [6, 13], one of these a child. In addition to these two and our case 3, two other survivors of atlanto-occipital dislocation have made a complete neurologic recovery [3, 11].

Prompt radiographic diagnosis of this injury is essential so that the craniocervical junction can be stabilized to prevent further damage to the brainstem and spinal cord and possibly permanent paralysis, neurologic deficit, or

death. However, evaluation of the atlanto-occipital articulation is difficult. Soft-tissue swelling is usually present with traumatic cervical spine injury, and it is frequently not specific to the level of injury. Although gross anteroposterior dislocation may be obvious, longitudinal distraction, particularly when subtle, may be quite difficult to evaluate. Several methods of analyzing the atlanto-occipital articulation in trauma have been proposed, but none of these standards is applicable for use in children. Perhaps more importantly, none of them addresses the *longitudinal* distraction-dislocation injury.

Pang and Wilberger [14] recently reviewed the radiographic criteria for diagnosis of atlanto-occipital dislocation. We agree with their conclusions regarding the unreliability

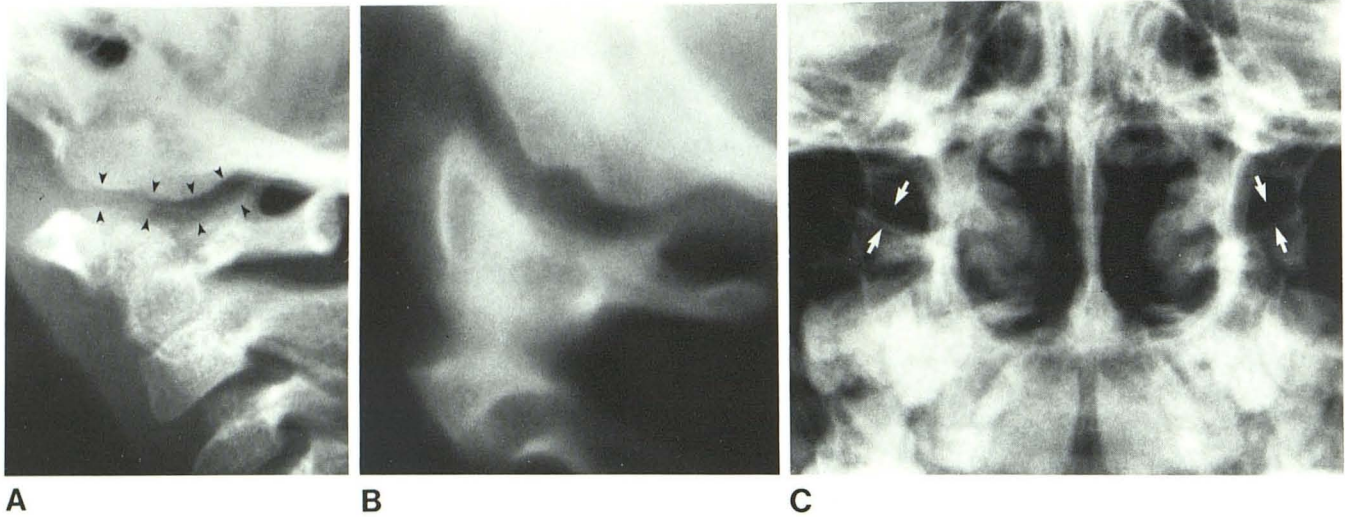


Fig. 4.—A, Brow-up lateral view of atlanto-occipital junction in normal 3-year-old child. Joint on one side (*arrowheads*). Overlying structures such as earlobe, mastoid tip, and opposite joint may cause some confusion in interpretation. B, Lateral polytome through an atlanto-occipital joint in normal 9-

year-old child. Occipital condyle occasionally has lobulated appearance, making analysis easier anteriorly or posterior to this notch. C, Anteroposterior skull film. Normal atlanto-occipital joints (*arrows*) almost unobscured by overlying structures.

of the dens-basion measurement standards proposed by Wholey et al. [16] and, similarly, the failure of the Dublin et al. [8] method, which is dependent upon an intact, nonrotated mandible to accurately reflect the true relation of the skull base to the atlas in all cases. They have also stated that the method of Powers et al. [11] is the most sensitive to changes in the atlanto-occipital alignment, and have restated that its reliability suffers only when there is a congenital anomaly of the atlas or foramen magnum.

The method of Powers et al. is based on the ratio of basion–posterior atlantic arch distance (BC) to anterior arch of atlas–opisthion distance (AO). They claim that the BC/AO ratio is a good discriminator of atlanto-occipital dislocation when greater than or equal to 1.0. Using this method, however, two of our three cases of longitudinal atlanto-occipital distraction measured within normal limits (case 2, 0.86; case 3, 0.91) and the third case was barely abnormal (case 1, 1.01). Woodring et al. [15] pointed out that this ratio may also fail in the case of the more uncommon posterior type of atlanto-occipital distraction.

Our experience further illustrates the difficulty encountered in assessing the atlanto-occipital junction. While these published standards may be useful at times, they must not be regarded as entirely reliable under all circumstances, particularly in children, and especially in the longitudinal distraction type of injury.

We found it useful to assess the *actual* distance between the occipital condyle and the condylar facet of C1, rather than using adjacent structures (e.g., mandible, basion, dens) as markers. The information is often available even from bedside examinations, and measurement of this distance gives direct evidence of atlanto-occipital integrity.

On the lateral view it is usually possible to judge the atlanto-occipital distance accurately, and this may be the key to correct diagnosis (fig. 4A). We found that head

rotation and flexion, and overlying structures such as ear lobe and mastoid tip, may add some confusion to interpretation until one becomes familiar with the anatomy. In addition, the distance between the cortical margin of the occipital condyle and the ossified condylar facet does vary slightly in most children from anterior to posterior, as well as from medial to lateral. Often the condyle is not smoothly rounded but may have a central groove, adding somewhat to the difficulty in measurement (fig. 4B). However, we have not yet found a case where that distance in normal children exceeded 5 mm, regardless of age, and in most cases the distance was 1.5–3.5 mm. Obviously, further work is needed to test this impression.

Measurement can be done on the anteroposterior (AP) film as well. Because it is often impossible to obtain a high quality open mouth AP view of the craniocervical junction, the AP skull film should be carefully assessed. In this view it is particularly important to look for widening of the articular facet joints because they are often not obscured by overlying structures (fig. 4C). However, it is sometimes difficult to assess the joint if there is head rotation, if the film is poorly penetrated, or if the x-ray beam is not parallel to the joint.

The radiographs in our three cases demonstrate the different degree of dislocation-distraction that can occur at the atlanto-occipital joint. Case 1 is the most graphic of the three and demonstrates considerable longitudinal distraction and mild anterior displacement. Case 2 is a more subtle longitudinal distraction injury, yet at autopsy there was disruption of virtually all of the internal ligaments, with only the nuchal ligament and the atlanto-occipital membrane intact. Case 3 is perhaps the most subtle injury, with a mild longitudinal distraction accompanied by an occipital fracture. This may account for the relatively benign clinical course and lack of neurologic impairment.

It has been suggested that skeletal traction is useful in

the acute management of atlanto-occipital dislocation; however, there is considerable disagreement about the amount of weight indicated. While some authors used as much as 7 kg of traction with apparent success [4], more recent reports [8, 9, 11, 12, 15] recommend minimal traction (1–2 kg) as a temporary stabilization measure, cautioning that the amount must be tempered by worsening symptoms and neurologic deficit.

We believe that skeletal traction is not indicated in a longitudinal atlanto-occipital distraction injury, and may cause further harm by increasing the tension on the spinal cord, brain stem, and vertebral arteries as well as the joints and supporting structures at the atlanto-occipital junction that have already been injured by distraction. We speculate that minimal traction (less than 2¼ kg) may not be so innocuous in a child, and may impair stability and healing of the atlanto-occipital junction. We have found no evidence that traction is a necessary part of the treatment of atlanto-occipital distraction-dislocation without anteroposterior displacement. On the contrary, the therapeutic objectives are immobilization and eventual skeletal fixation if needed, as was the case in one of our three patients (case 1).

Perhaps because of more general familiarization with and public emphasis on cardiopulmonary resuscitation, we will see more survivors of atlanto-occipital dislocation and distraction in trauma and emergency facilities in the future. Both radiologists and clinicians need to be aware of this unusual injury and its potential for successful outcome when diagnosis is made and proper treatment is instituted promptly.

ACKNOWLEDGMENTS

We thank Robert Lukin for helpful suggestions, Marlena Tyre for preparing the manuscript, and Richard Isham for photography work.

REFERENCES

1. Bucholz RW, Burkhead WZ. The pathological anatomy of fatal atlanto-occipital dislocations. *J Bone Joint Surg [Am]* **1979**;61:248–250
2. Werne S. Studies in spontaneous atlas dislocation. *Acta Orthop Scand [Suppl]* **1957**;23:1–159
3. Gabrielsen TO, Maxwell JA. Traumatic atlanto-occipital dislocation. *AJR* **1966**;97:624–629
4. Evarts CM. Traumatic occipito-atlantal dislocation. *J Bone Joint Surg [Am]* **1970**;52:1653–1660
5. Englander O. Non-traumatic occipito-atlanto-axial dislocation. *Br J Radiol* **1942**;15:341–345
6. Eismont FJ, Bohlman HH. Posterior atlanto-occipital dislocation with fractures of the atlas and odontoid process. *J Bone Joint Surg [Am]* **1978**;60:397–399
7. Blackwood NJ. Atlo-occipital dislocation. Case of fracture of the atlas and axis, and forward dislocation of the occiput in the spinal column, life being maintained for thirty-four hours and forty minutes by artificial respiration, during which a laminectomy was performed upon third cervical vertebra. *Ann Surg* **1908**;47:654–658
8. Dublin AB, Marks WM, Weinstock D, Newton TH. Traumatic dislocation of the atlantooccipital articulation (AOA) with short term survival. *J Neurosurg* **1980**;52:541–546
9. Fruin AH, Pirotte TP. Traumatic atlantooccipital dislocation. *J Neurosurg* **1977**;46:663–666
10. Page CP, Story JL, Wissinger JP, Branch CL. Traumatic atlanto-occipital dislocation. *J Neurosurg* **1973**;39:394–397
11. Powers B, Miller MD, Kramer RS, Martinez S, Gehweiler JA. Traumatic anterior atlanto-occipital dislocation. *Neurosurgery* **1979**;4:12–17
12. Rockswold GL, Seljeskog EL. Traumatic atlantocranial dislocation with survival. *Minn Med* **1979**;62:151–152
13. Farthing JW. Atlantocranial dislocation with survival. *North Carolina Med J* **1948**;9:34–36
14. Pang D, Wilberger JE. Traumatic atlanto-occipital dislocation with survival: case report and review. *Neurosurgery* **1980**;7:503–508
15. Woodring JH, Selke AC, Duff DE. Traumatic atlanto-occipital dislocation with survival. *AJNR* **1981**;2:251–254, *AJR* **1981**;137:21–24
16. Wholey MH, Bruwer AJ, Baker HL. The lateral roentgenogram of the neck (with comments on the atlanto-odontoid-basion relationship). *Radiology* **1958**;71:350–356

Addendum

Since the acceptance of this manuscript we have been alerted to another case of atlanto-occipital distraction injury with survival. A 7-year-old boy was found unresponsive after apparently striking his head against a windshield in an automobile accident. He was unconscious, but could move all four extremities appropriately. There was no focal neurologic deficit. Lateral cervical spine film demonstrated mild atlanto-occipital distraction injury. The degree of distraction began to diminish after 3 days of immobilization and Pavulon paralysis, and appeared to return to normal by about 20 days after injury. He recovered fully from the injury without neurologic deficit. This additional case of atlanto-occipital distraction was sent to us courtesy of Richard L. Goldman, Hartford, Conn.