

Are your **MRI contrast agents** cost-effective?

Learn more about generic **Gadolinium-Based Contrast Agents**.



**FRESENIUS
KABI**

caring for life

AJNR

Ruptured Maxillary Retention Cyst: Cause of Unilateral Rhinorrhea after Trauma

J.K. Hoang, E.C. Smith and D.P. Barboriak

AJNR Am J Neuroradiol 2009, 30 (6) 1121-1122

doi: <https://doi.org/10.3174/ajnr.A1457>

<http://www.ajnr.org/content/30/6/1121>

This information is current as of April 19, 2024.

Ruptured Maxillary Retention Cyst: Cause of Unilateral Rhinorrhea after Trauma

CASE REPORT

J.K. Hoang
E.C. Smith
D.P. Barboriak

SUMMARY: This study describes a case of a patient with traumatic rupture of a maxillary sinus retention cyst, which had an interesting clinical presentation of unilateral rhinorrhea, mimicking a CSF leak. The diagnosis was made fortuitously by comparison of a posttraumatic CT brain examination with a CT sinus study performed 1 day earlier.

Maxillary sinus retention cysts are common incidental findings on imaging and are usually of no clinical significance. Retention cysts that resolve on follow-up imaging are thought to spontaneously rupture, but there is rarely any clinical history or imaging to support this theory. We present the case of a patient with traumatic rupture of a maxillary sinus retention cyst that presented with unilateral rhinorrhea, a symptom concerning for a CSF leak.

Case Report

An 18-year-old white woman presented with neck pain after a traumatic injury during a cheerleading maneuver. She was holding another cheerleader overhead when her partner lost balance and abruptly landed on top of the patient's head. Immediately after the accident, the patient noticed clear drainage from the left nostril for approximately 10 seconds, which ceased spontaneously. There was no clear loss of consciousness, facial pain, or headache. Medical history was significant for classic migraine headache and inflammatory sinus disease. Results of neurologic and facial soft tissue examinations were normal.

CT brain examination after trauma demonstrated a fluid-level in the left maxillary sinus (Fig 1) without a facial bone fracture. There was no skull base fracture on thin-section multidetector CT. Further questioning revealed that the patient had a CT sinus study performed the day earlier at another institution. This study was retrieved for comparison and showed a smooth, convex soft tissue mass in the left maxillary sinus consistent with a retention cyst (Fig 2). The cyst was

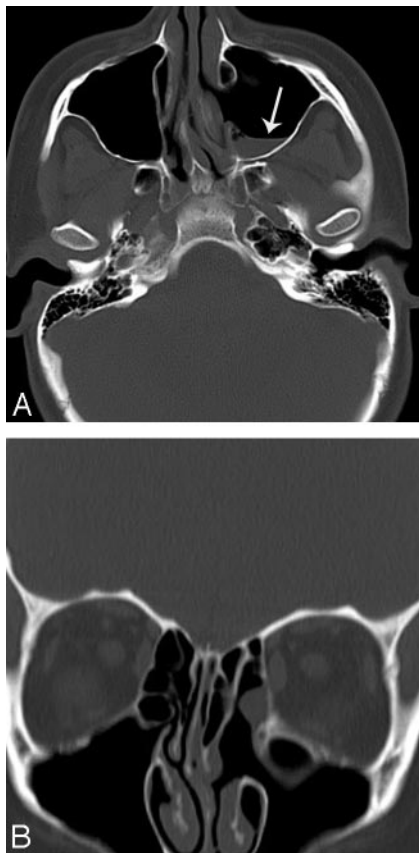


Fig 1. A, Axial CT in an 18-year-old woman performed after head trauma shows a fluid-level (arrow) in the left maxillary sinus. B, Reformatted coronal CT scan shows no evidence of fracture. Changes of previous left functional endoscopic sinus surgery are noted.

Received November 4, 2008; accepted after revision November 10.

From the Department of Radiology (J.K.H., D.P.B.), Division of Neuroradiology; and Department of Pediatrics (E.C.S.), Division of Child Neurology, Duke University Medical Center, Durham, NC.

Please address correspondence to Jenny K. Hoang, Duke University Medical Center, Box 3808, Erwin Rd, Durham, NC 27710; e-mail: jennykh@gmail.com

DOI 10.3174/ajnr.A1457

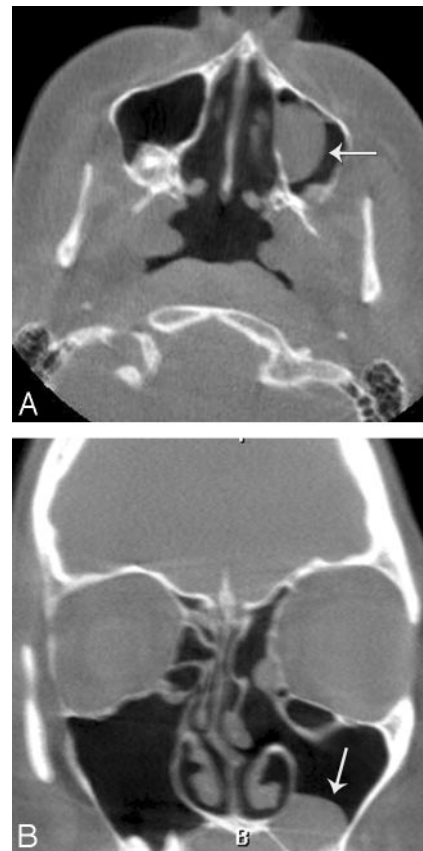


Fig 2. Axial (A) and coronal (B) CT scans from CT sinus study performed the day before the head trauma show a retention cyst (arrows) in the left maxillary sinus.

also noted on a MR imaging study of the brain from 1 month earlier. These serial imaging studies confirmed the diagnosis of left maxillary retention cyst rupture as the cause of unilateral rhinorrhea and left maxillary sinus fluid-level. The patient made an uneventful recovery.

Discussion

In patients with head trauma, the most important differential for unilateral rhinorrhea is CSF leak or fistula. This is the result of an osseous and dural defect at the skull base, connecting the subarachnoid space to the paranasal sinus. There are several invasive and noninvasive imaging options to investigate CSF leaks,¹ but before such studies are performed, the radiologist and clinician should consider benign differentials for post-traumatic rhinorrhea. This case illustrates that unilateral rhinorrhea and a sinus fluid-level on imaging can be caused by a ruptured maxillary sinus retention cyst.

Retention cysts are a common incidental and asymptomatic finding in the paranasal sinuses, which are seen in up to 13% of CT and MR imaging examinations.² Although commonly known as “mucous retention cysts,” 2 types of retention cysts exist: mucous and serous.³ Mucous retention cysts are more common and are caused by the obstruction of a seromucinous gland. Serous retention cysts result from the accumulation of fluid in the submucosal layer. Both types of retention cysts appear as smooth, outwardly convex soft tissue masses on imaging.

Most retention cysts remain unchanged between studies, but in some cases the retention cyst may resolve completely.⁴ The accepted theory is that the fluid-filled sac ruptures and the cyst disappears. Despite the high incidence of the retention cysts, to our knowledge, there is no literature describing the symptoms of retention cyst rupture. Only 1 case report describes the spontaneous cyst-rupture sequence documented on plain radiographs.⁵

The case of this patient shows that maxillary retention cysts can rupture with blunt head trauma. It is more important to note that it serves as a reminder to consider ruptured retention cyst as a benign cause of unilateral rhinorrhea and a maxillary sinus fluid-level. Although comparison with previous imaging is helpful, even without previous studies the diagnosis should be considered before embarking on invasive and costly investigations for traumatic CSF leak.

References

1. Lloyd KM, DelGaudio JM, Hudgins PA. **Imaging of skull base cerebrospinal fluid leaks in adults.** *Radiology* 2008;248:725–36
2. Bhattacharyya N. **Do maxillary sinus retention cysts reflect obstructive sinus phenomena?** *Arch Otolaryngol Head Neck Surg* 2000;126:1369–71
3. Eggesbo HB. **Radiological imaging of inflammatory lesions in the nasal cavity and paranasal sinuses.** *Eur Radiol* 2006;16:872–88
4. Casamassimo PS, Lilly GE. **Mucosal cysts of the maxillary sinus: a clinical and radiographic study.** *Oral Surg Oral Med Oral Pathol* 1980;50:282–86
5. Ruprecht A, Lau W. **Rupture of a mucous retention cyst.** *Oral Surg Oral Med Oral Pathol* 1990;70:683