

Are your **MRI contrast agents** cost-effective?

Learn more about generic **Gadolinium-Based Contrast Agents**.



**FRESENIUS
KABI**

caring for life

AJNR

Osteoblastoma of the Hyoid Bone

C.M. Rivera-Serrano, B.F. Branstetter IV and J.T. Johnson

AJNR Am J Neuroradiol 2010, 31 (6) 1080-1081

doi: <https://doi.org/10.3174/ajnr.A1872>

<http://www.ajnr.org/content/31/6/1080>

This information is current as
of April 20, 2024.

C.M. Rivera-Serrano
B.F. Branstetter IV
J.T. Johnson

SUMMARY: Osteblastoma is a rare bone tumor that usually affects the vertebrae. We present the first known case of osteblastoma arising in the hyoid bone, in a patient who presented with a neck mass and dysphagia. The radiographic appearance of the tumor is similar to that of low-grade chondrosarcoma, with well-defined expansion of the bone and central chondroid matrix.

ABBREVIATIONS: NSAIDs = nonsteroidal anti-inflammatory drugs

Solid primary tumors of the hyoid bone are exceedingly rare. Reported cases have included chondrosarcoma, plasmacytoma, osteosarcoma, giant cell tumor, aneurysmal bone cyst, and benign osteoma.¹ Patients with hyoid bone tumors usually present with dysphagia and may have a palpable neck mass. The goal of imaging is to distinguish benign from malignant causes and to assist in surgical planning.

Osteblastoma is a rare benign bone tumor first described in 1956. In the head and neck, osteblastoma may arise in the maxilla, mandible, temporal bone, and, very rarely, in the larynx.² Surgical excision, when feasible, is usually curative. We present the first known case of an osteblastoma arising in the hyoid bone.

Case Report

A healthy 51-year-old man presented with a mass in the left side of the neck, which he had noticed 3 weeks earlier. He reported pain in the contralateral neck for the past 5 years and mild dysphagia of recent onset, but his voice was unchanged. Thirty years ago the patient had undergone chemoradiation and surgery for a fibrosarcoma in the soft tissues in his posterior neck. Physical examination was remarkable for a hard nontender left-sided neck mass at the level of the hyoid bone. This mass was freely mobile and moved up and down with swallowing. The overlying skin was intact. Flexible transnasal laryngoscopy showed indentation of the left lateral pharyngeal wall at the level of the hyoid bone.

CT revealed a 3-cm well-defined spheric mass with a calcified ring and a partially calcified central matrix, arising within the left hyoid bone, causing extrinsic compression of the hypopharynx (Fig 1). On the basis of these imaging features, a diagnosis of low-grade chondrosarcoma of the hyoid bone was proposed. Differential considerations included bony tumors such as osteosarcoma, enchondroma, and ossifying fibroma.

The patient underwent resection of the left hyoid bone, from which he recovered uneventfully. The pathologic diagnosis was a 3-cm hyoid osteblastoma with a secondary aneurysmal bone cyst component. Focally, the tumor broke through the cortex into the adjacent soft tissue, but the surgical margin in this area appeared free. A specimen radiograph showed the internal calcified matrix in greater detail (Fig 2).

Discussion

Solid primary tumors of the hyoid bone are exceedingly rare, and reported cases have included plasmacytoma, osteosarcoma, giant cell tumor, aneurysmal bone cyst, osteoma, and chondrosarcoma.¹

Osteblastoma is a rare bone tumor first described by Lichtestein and Jaffe as a distinct neoplasm in 1956. This disease accounts for 1%^{3,4} or less⁵ of all bone tumors and most commonly involves the spine and sacrum of young individuals.² The second most common location is the mandible, followed by other craniofacial bones.³ Other more rare locations in the head and neck include the temporal bone, where 10 cases have been reported.⁴ Osteblastomas of the larynx are also extremely rare, with only 4 cases reported up to 2008. Presumably most of these laryngeal osteblastomas arose within ossifying cartilage, but one of them was thought to be extraosseous.⁶

Clinically, osteblastomas present mainly with pain, swelling, and expansion of the bone cortex.² An osteoid osteoma is histopathologically similar but is smaller and is associated with pain that is often nocturnal and relieved with the use of aspirin or other NSAIDs.³ These typical symptoms occur in approximately 80% of the patients.³ Unlike osteoid osteoma, the pain of osteblastoma usually does not respond to NSAIDs and is not generally more severe at night.⁵

Radiographic features of osteblastoma are variable, usually showing a combination of radiolucent and radiopaque patterns, depending on the degree of lesional calcification, but without a sclerotic border or periosteal reactions.² An osteoid osteoma should demonstrate a radiographic nidus of <1 cm, whereas an osteblastoma should measure >2 cm in greatest dimension. Neoplasms that measure between 1 and 2 cm fall into an arbitrary zone in which classification is determined by individual preference.³

The radiographic differential diagnosis for osteblastoma includes other benign bone tumors. If a central calcified matrix is present, chondrosarcoma or enchondroma is an important consideration. If the lesion is lucent, aneurysmal bone cyst or other bone cysts should be considered. Other calcification patterns may suggest diagnoses such as ossifying fibroma or fibrous dysplasia.

Histologically, osteblastoma is considered benign.⁵ It is a bone-forming tumor characterized by osteoid and woven bone deposition and abundant osteoblasts that are frequently in close association with newly formed bone. Occasionally, osteblastomas may appear richly cellular, contain an abundant osteoclast-like component, and show plump osteoblasts that may evoke a diagnosis of osteosarcoma, thus leading to unnecessary overtreatment.² The histopathologic features are

Received June 9, 2009; accepted August 5.

From the Departments of Otolaryngology (C.M.R.-S., B.F.B., J.T.J.) and Radiology (B.F.B.), University of Pittsburgh School of Medicine, Pittsburgh, Pennsylvania.

Please address correspondence to Barton F. Branstetter IV, MD, Department of Radiology, University of Pittsburgh School of Medicine, 200 Lothrop St, PUH Room D132, Pittsburgh, PA 15215; e-mail: bfb1@pitt.edu

DOI 10.3174/ajnr.A1872

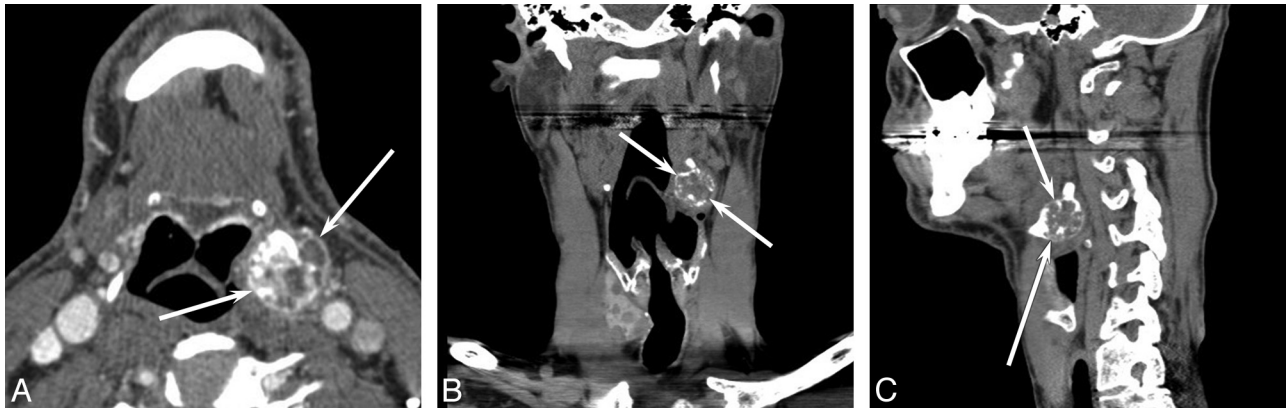


Fig 1. Hyoid osteoblastoma. Contrast-enhanced neck CT in axial (A), coronal (B), and sagittal (C) planes demonstrates a well-defined mass (arrows) arising from the left side of the hyoid bone. The enhancement pattern of the mass is heterogeneous, and there is a calcified central tumor matrix. The relationship to the hyoid bone is most clear on the sagittal image (C).

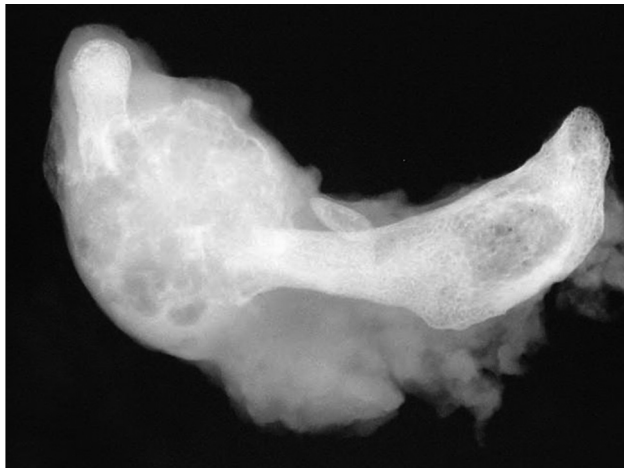


Fig 2. Specimen radiograph demonstrates more clearly the central chondroid matrix of the tumor.

similar to those described for osteoid osteoma,³ and such resemblance is a particular challenge to the pathologist.⁵

In summary, this is the first report of a proved osteoblastoma of the hyoid bone. The radiographic appearance is most easily confused with low-grade chondrosarcoma or other benign calcifying bone tumors.

References

1. Hirunpat S, Prueganusak K, Sinruk Y, et al. **Chondrosarcoma of the hyoid bone: imaging, surgical, and histopathologic correlation.** *AJNR Am J Neuroradiol* 2006;27:123–25
2. Capodiferro S, Maiorano E, Giardina C, et al. **Osteoblastoma of the mandible: clinicopathologic study of four cases and literature review.** *Head Neck* 2005;27:616–21
3. Jones AC, Prihoda TJ, Kacher JE, et al. **Osteoblastoma of the maxilla and mandible: a report of 24 cases, review of the literature, and discussion of its relationship to osteoid osteoma of the jaws.** *Oral Surg Oral Med Oral Pathol Oral Radiol Endod* 2006;102:639–50. Epub 2006 Apr 17
4. Doshi SV, Frantz TD, Korol HW. **Benign osteoblastoma of the temporal bone: case report and literature review.** *Am J Otolaryngol* 2001;22:211–14
5. Berry M, Mankin H, Gebhardt M, et al. **Osteoblastoma: a 30-year study of 99 cases.** *J Surg Oncol* 2008;98:179–83
6. Mirbagheri N, Galloway S, Iseli TA, et al. **Extraosseous osteoblastoma of larynx presenting with acute airway obstruction.** *J Laryngol Otol* 2008;122:1265–58. Epub 2008 Feb 21