

Are your MRI contrast agents cost-effective?

Learn more about generic Gadolinium-Based Contrast Agents.



**AJNR**

**The Emerging Echogenic Tract Sign of  
Pyriform Sinus Fistula: An Early Indicator in  
the Recovery Stage of Acute Suppurative  
Thyroiditis**

N.H. Park, H.J. Park, C.S. Park, M.S. Kim and S.I. Park

This information is current as  
of April 17, 2024.

*AJNR Am J Neuroradiol* 2011, 32 (3) E44-E46

doi: <https://doi.org/10.3174/ajnr.A2015>

<http://www.ajnr.org/content/32/3/E44>

# The Emerging Echogenic Tract Sign of Pyriform Sinus Fistula: An Early Indicator in the Recovery Stage of Acute Suppurative Thyroiditis

## CASE REPORT

N.H. Park  
H.J. Park  
C.S. Park  
M.S. Kim  
S.I. Park

**SUMMARY:** AST is commonly associated with pyriform sinus–thyroid fistula in children. Radiologic findings of AST are documented in a few reports. We report a new sign we term the “emerging echogenic tract sign,” which reflects a patent air-containing pyriform sinus–thyroid fistula on follow-up US. Recognition of this sign is an important finding suggesting an associated pyriform sinus–thyroid fistula in a patient with AST and also suggesting the adequate timing of barium esophagography to confirm the fistula.

**ABBREVIATIONS:** AST = acute suppurative thyroiditis; US = sonography

AST is a rare infectious disease affecting mainly children and young adults.<sup>1</sup> That pyriform sinus fistula often causes suppurative thyroiditis has been well documented.<sup>2–4</sup> However, when a pyriform sinus fistula is not readily identified in a patient with AST, the correct diagnosis can be difficult.

In the active phase of AST, demonstration of pyriform sinus fistula on US or esophagography is often difficult due to the inflammatory exudates within the fistula as well as a compression of the fistula by edema. With recovery of the thyroiditis, an echogenic tract suggesting the pyriform sinus fistula may emerge on US, and we termed this the “emerging echogenic tract sign.” This finding is suggestive of an associated pyriform sinus fistula and also suggests that a subsequent barium esophagography will be helpful in demonstrating it.

We report the emerging echogenic tract sign in the quiescence stage of AST with associated pyriform sinus fistula.

## Case Reports

### Case 1

A 7-year-old girl was referred for evaluation of high fever and painful swelling in the left side of the neck for 5 days.

US after admission (Fig 1A) showed swelling of the left lobe of the thyroid gland with heterogeneous hypoechoic change of perithyroidal soft tissue. On a color Doppler study, increased signals of blood flow within the lesion were detected. Definite abscess formation was not seen. CT of the neck and US performed 6 days later (Fig 1B, -C) showed marked improvement of the inflammatory change of the left lobe of thyroid gland and perithyroidal soft tissue. Subsequent barium esophagogram (Fig 1D) was performed for possible presence of associated pyriform sinus–thyroid fistula as the cause of AST, but it failed to demonstrate a fistula.

Received November 10, 2009; accepted after revision December 2.

From the Department of Diagnostic Radiology (N.H.P., H.J.P., C.S.P., M.S.K.), Myongji Hospital, Kwandong University, College of Medicine, Goyang, South Korea; and Department of Diagnostic Radiology (S.I.P.), Soonchunhyang University Bucheon Hospital, Bucheon, South Korea.

Please address correspondence to Noh Hyuck Park, MD, Department of Diagnostic Radiology, Myongji Hospital, Kwandong University, College of Medicine, 412-270, 697-24 Hwajeung-Dong, Deogyang-Gu, Koyang-Si, Gyeong Gi-Do, South Korea; e-mail: nhpark904@kd.ac.kr

DOI 10.3174/ajnr.A2015

Follow-up US performed 3 months after the initial US (Fig 1E, -F) showed a newly developed echogenic tract within the left lobe of the thyroid gland, suspicious for associated pyriform sinus–thyroid fistula. Repeat barium esophagography (Fig 1G) was performed and demonstrated this fistula.

### Case 2

A 7-year-old girl presented with fever, poor oral intake, sore throat, and cough for 3 days and was referred for US. Initial US of the neck (Fig 2A) showed an ill-defined hypoechoic lesion with suspected microabscess in the left lobe of the thyroid gland and inflammatory change of overlying perithyroidal soft tissue. CT of the neck (Fig 2B) showed a heterogeneous low-attenuated lesion in the left lobe of the thyroid gland and inflammatory swelling of the overlying strap muscle.

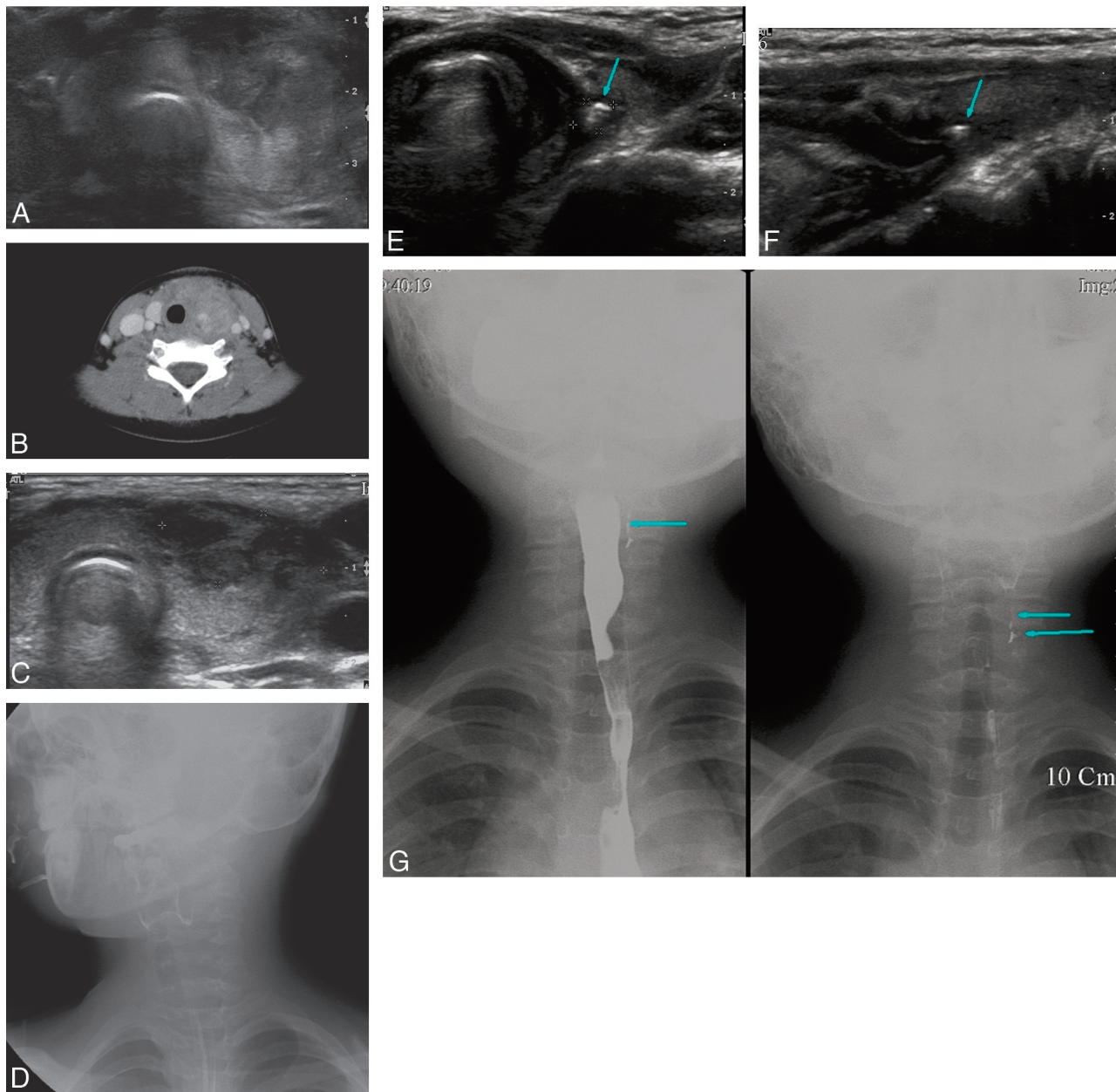
Follow-up US (Fig 2C, -D) performed 6 days after initial US showed an improved state of intrathyroidal and perithyroidal inflammation and a newly developed echogenic tract in the left lobe of the thyroid gland. Barium esophagogram (Fig 2E) successfully demonstrated a pyriform sinus–thyroid fistula.

## Discussion

AST and thyroid abscess are extremely rare disorders. A rich blood supply, a generous lymphatic drainage, a high iodine level that inhibits bacterial growth, and a complete protective fibrous capsule have been proposed as the contributing factors to the relatively high resistance of the thyroid gland to infections.<sup>1,5,6</sup> Congenital pyriform sinus fistula is a remnant of the fourth branchial cleft and has recently been recognized as an underlying cause of AST or acute deep neck infection.<sup>2–4,6</sup>

Recurrent AST due to persistent pyriform sinus–thyroid fistula is likely more common than previously believed and usually becomes symptomatic before 10 years of age. Eighty percent of patients with recurrent AST due to persistent pyriform sinus–thyroid fistula present during the first decade of life (mean age, 7.6 years; age range, birth to 56 years) and 8%, during adulthood.<sup>3,7–10</sup>

In the acute phase, the echogenic tract sign was not demonstrated within the inflamed thyroid gland or perithyroid soft tissue, and it is presumed to be due to an obstruction of the fistula by inspissated inflammatory exudates.



**Fig 1.** Images of a 7-year-old girl with fever and painful neck swelling for 5 days. *A*, Initial US of the thyroid gland shows a heterogeneous hypoechoic inflammatory change of perithyroid soft tissue with invasion into the anterior portion of the left lobe of the thyroid gland. *B*, CT scan at the level of the thyroid gland reveals a heterogeneous low-attenuated inflammatory mass anterior to the left lobe of the thyroid gland with invasion into the thyroid gland, displacing the ipsilateral carotid sheath laterally. *C*, Follow-up US 5 days after initial US shows improvement of the inflammatory change of the perithyroid soft tissue and the left lobe of the thyroid gland. *D*, Subsequent barium esophagography shows no demonstrable pyriform sinus fistula. *E* and *F*, Follow-up US obtained 3 months after the initial US shows marked improvement of the inflammatory change and a newly developed echogenic tractlike lesion (arrow) in the left lobe of the thyroid gland, suggestive of an associated pyriform sinus fistula. *G*, Subsequent barium esophagography shows the pyriform sinus fistula (arrows) originating from its apex.

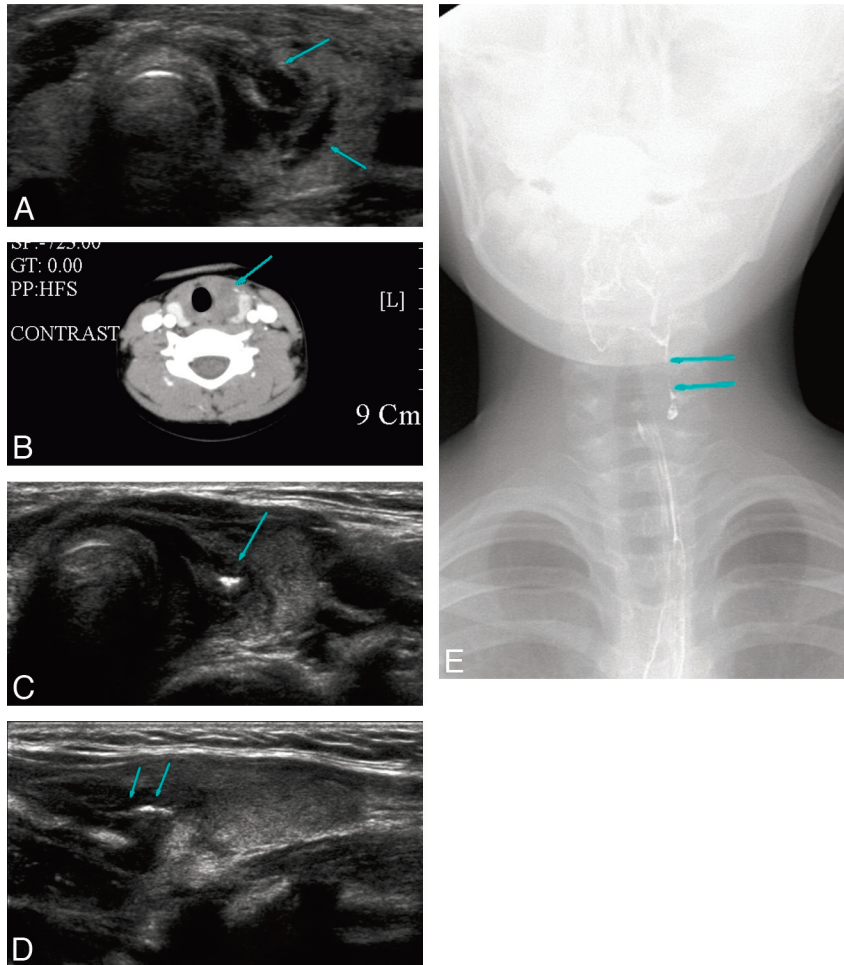
After recovery from AST, follow-up US showed an echogenic tract, which we speculate represents an air-filled pyriform sinus fistula within the parenchyma of the left lobe of the thyroid gland. This emerging echogenic tract sign is highly suggestive of a pyriform sinus–thyroid fistula as the cause of AST and should lead to barium esophagography for confirmation.

In conclusion, the emerging echogenic tract sign, suggesting a pyriform sinus–thyroid fistula, may be appreciated only on follow-up US in the quiescence stage of AST. This finding

appears helpful for the diagnosis of an associated pyriform sinus–thyroid fistula and should effect a confirmatory barium esophagography.

**References**

1. Berger SA, Zonszein J, Villamena P, et al. Infectious disease of the thyroid gland. *Rev Infect Dis* 1983;5:108–22
2. Park SW, Han MH, Sung MH, et al. Neck infection associated with pyriform sinus fistula: imaging findings. *AJNR Am J Neuroradiol* 2000;21:817–22
3. Bar-Ziv J, Slasky BS, Sichel JY, et al. Branchial pouch sinus tract from the piriform fossa causing acute suppurative thyroiditis, neck abscess, or both:



**Fig 2.** Images of a 7-year-old girl with a sore throat and neck pain for 3 days. *A*, US shows an ill-defined heterogeneous hypoechoic lesion in the left lobe of the thyroid gland (*arrows*) and inflammatory change of the overlying strap muscle. *B*, CT scan shows a heterogeneous low-attenuated inflammatory change (*arrow*) in the medial aspect of the left lobe of the thyroid gland and overlying soft tissue. Tracheal deviation is noted by the inflammatory mass. *C* and *D*, Follow-up US performed 6 days after the initial US examination shows improvement of inflammatory change and a newly developed echogenic tractlike lesion (*arrows*) in the left lobe of the thyroid gland. *E*, Subsequent barium esophagography shows a pyriform sinus fistula (*arrows*) originating from the apex of the pyriform sinus.

CT appearance and the use of air as a contrast agent. *AJR Am J Roentgenol* 1996;167:1569–72

4. Hatabu H, Kasagi K, Yamamoto K, et al. Acute suppurative thyroiditis associated with pyriform sinus fistula: sonographic findings. *AJR Am J Roentgenol* 1990;155:845–47
5. Womack NA, Cole WH. Thyroiditis. *Surgery* 1944;16:770–82
6. Miller D, Hill JL, Sun CC, et al. The diagnosis and management of pyriform sinus fistula in infants and young children. *J Pediatr Surg* 1983;18:377–81
7. Himi T, Kataura A. Distribution of C cells in the thyroid gland with pyriform sinus fistula. *Otolaryngol Head Neck Surg* 1995;112:268–73
8. Burge D, Middleton A. Persistent pharyngeal pouch derivatives in the neonate. *J Pediatr Surg* 1983;18:230–34
9. Roediger WE, Kalk F, Spitz L, et al. Congenital thyroid cyst of ultimobranchial gland origin. *J Pediatr Surg* 1977;12:575–76
10. Tucker HM, Skolnick ML. Fourth branchial cleft (pharyngeal pouch) remnant. *Trans Am Acad Ophthalmol Otolaryngol* 1973;77:ORL368–71