

Are your **MRI contrast agents** cost-effective?

Learn more about generic **Gadolinium-Based Contrast Agents**.



AJNR

**Neonatal Tract-Based Spatial Statistics
Findings and Outcome in Preterm Infants**

B.J.M. van Kooij, L.S. de Vries, G. Ball, I.C. van Haastert,
M.J.N.L. Benders, F. Groenendaal and S.J. Counsell

AJNR Am J Neuroradiol 2012, 33 (1) 188-194

doi: <https://doi.org/10.3174/ajnr.A2723>

<http://www.ajnr.org/content/33/1/188>

This information is current as
of April 18, 2024.

**ORIGINAL
RESEARCH**

B.J.M. van Kooij
L.S. de Vries
G. Ball
I.C. van Haastert
M.J.N.L. Benders
F. Groenendaal
S.J. Counsell



Neonatal Tract-Based Spatial Statistics Findings and Outcome in Preterm Infants

BACKGROUND AND PURPOSE: WM injury is associated with different disabilities that children born prematurely may experience during their lives. The aim of this study was to use TBSS to test the hypothesis that WM microstructure at TEA in preterm infants is correlated with cognitive and motor outcome at 2-year corrected age.

MATERIALS AND METHODS: Sixty-three preterm infants, born at a mean gestational age of 28.7 weeks, underwent MR imaging and DTI at TEA. Neurodevelopmental performance was assessed by using the BSITD-III. Voxelwise analysis of the DTI data was performed by using TBSS to assess the relationship among FA, AD, and RD at TEA, and cognitive, fine-motor, and gross-motor scores at 2-year corrected age.

RESULTS: Cognitive scores were correlated with FA values in the CC. Fine-motor scores were correlated with FA and RD throughout the WM. Gross-motor scores were associated with RD in the CC, fornix, and internal and external capsule.

CONCLUSIONS: WM microstructure in preterm infants at TEA was associated with cognitive, fine-motor, and gross-motor performance at 2-year corrected age. This study suggests that TBSS of DTI data at TEA has the potential to be used as a biomarker for subsequent neurodevelopment.

ABBREVIATIONS: AD = axial diffusion; BSITD-III = Bayley Scales of Infant and Toddler Development, Third edition; CC = corpus callosum; FA = fractional anisotropy; FMRI = Functional MR Imaging of the Brain; PLIC = posterior limb of the internal capsule; RD = radial diffusion; TBSS = tract-based spatial statistics; TEA = term-equivalent age; TFCE = threshold-free cluster enhancement

With improvements in neonatal care, the mortality rate of preterm infants is decreasing. However, they remain at risk for neurodevelopmental impairments in later childhood.^{1,2} MR imaging is increasingly performed to assess brain damage in preterm infants. With the reduction in major focal lesions such as cystic periventricular leukomalacia, diffuse WM injury is now the most common abnormality observed on MR imaging.³

DTI is an MR imaging technique that may be used to assess WM development and injury.⁴ Image contrast in DTI is based on the Brownian motion of water molecules. In WM, water molecular motion is influenced by various factors (eg, axonal attenuation and degree of myelination).⁵ Water diffuses preferentially along WM fibers and is restricted across fiber bundles. Thus, the location and direction of cerebral WM tracts

can be determined by assessing the preferential direction of water diffusion.⁶ Objective measures such as FA, AD (diffusion parallel to WM tracts) [λ_1]; and RD (diffusion perpendicular to WM tracts [$(\lambda_2 + \lambda_3) / 2$]), can be derived from DTI and can provide information regarding WM microstructure. DTI studies of the preterm brain have shown that FA increases with age,⁷⁻¹⁰ which is mainly driven by a decrease in RD,^{11,12} and that FA is reduced and apparent diffusion coefficient values are increased in WM injury.^{13,14}

TBSS is a recently developed observer-independent tool for analyzing DTI data.¹⁵ With TBSS, WM microstructural abnormalities have been identified in the absence of focal injury in the preterm brain at TEA.¹⁶ Additionally, Counsell et al¹⁷ demonstrated a relationship between FA in specific WM tracts and neurodevelopment, assessed by using the Griffiths Mental Developmental Scales, in children who were born preterm and studied at 2 years of age.

The aim of the present study was to test the hypothesis that WM microstructure, assessed by TBSS, in preterm infants at TEA is associated with neurodevelopmental performance at 2-year corrected age.

Materials and Methods

Patients

Neonates who were born before 31 weeks' gestation and reached TEA between January 2007 and July 2008 were recruited for a prospective preterm cohort study. Neonates with dysmorphic features or an infection of the central nervous system were excluded. Of the 174 consecutively admitted neonates, 22 died in the neonatal period, informed parental consent was not obtained for 14 neonates, and 15 neonates were not examined with our 3T system. MR imaging of the

Received March 23, 2011; accepted after revision May 2.

From the Department of Neonatology (B.J.M.v.K., L.S.d.V., I.C.v.H., M.J.N.L.B., F.G.), Wilhelmina Children's Hospital/University Medical Centre Utrecht, Utrecht, the Netherlands; Imaging Sciences Department (G.B., S.J.C.), Medical Research Council Clinical Sciences Centre, Imperial College London, London, UK; and Hammersmith/St Mary's Comprehensive Biomedical Research Centre (S.J.C.), London, UK.

This work was supported by the Young Investigator Exchange Program Fellowship of the International Pediatric Research Foundation and the Netherlands Organization for Health Research and Development (project 94527022).

Paper previously presented at: 11th International Congress of the European Society of Magnetic Resonance in Neuropediatrics, March 24-26, 2011; Amsterdam, the Netherlands.

Please address correspondence to L.S. de Vries, MD, Department of Neonatology, Wilhelmina Children's Hospital, KE 04.123.1, PO Box 85090, 3508 AB Utrecht, the Netherlands; email: L.S.deVries@umcutrecht.nl



Indicates open access to non-subscribers at www.ajnr.org

<http://dx.doi.org/10.3174/ajnr.A2723>

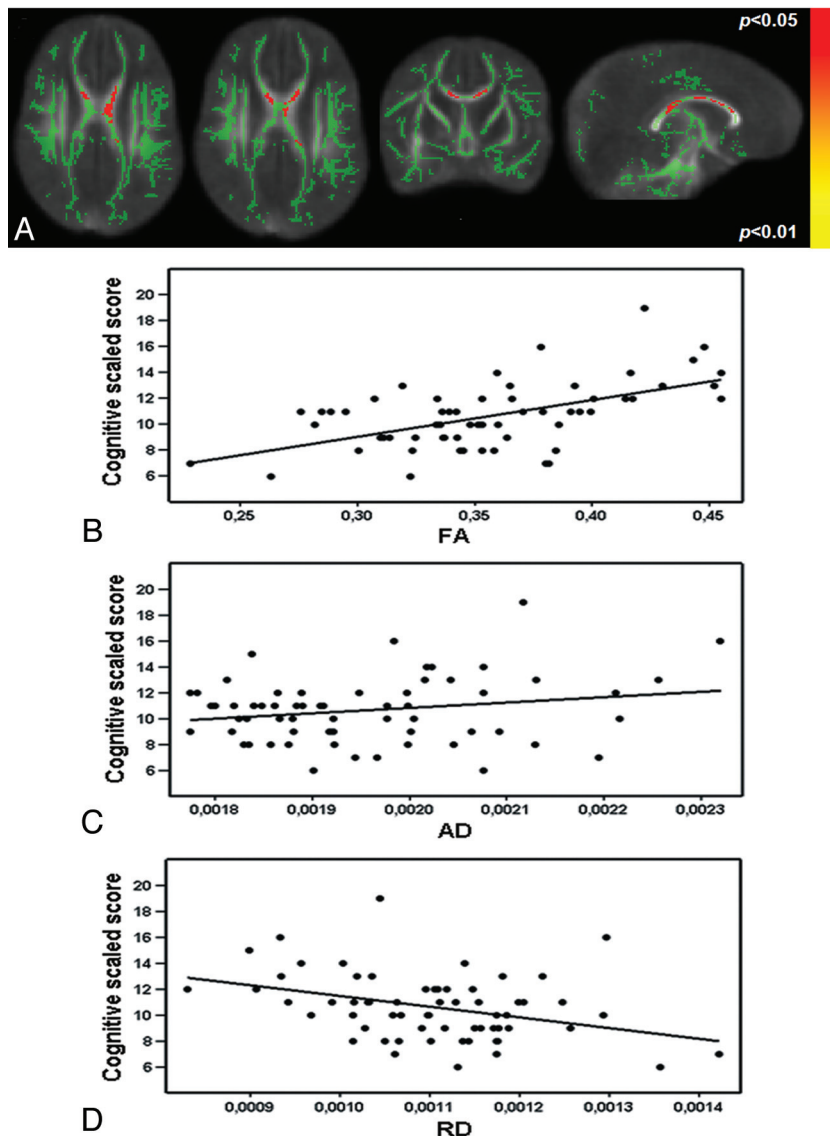


Fig 1. Diffusion parameters in relation to cognitive outcome. Mean FA skeleton (green) overlaid on the mean FA map in the axial, coronal, and sagittal planes. Regions of the mean FA skeleton in green voxels in which there is no correlation between FA and cognitive score. A, Voxels showing a significant correlation between FA and cognitive scores are shown in red-yellow. The graphs demonstrate the relationship between FA ($R^2 = 0.31$, B), AD ($R^2 = 0.04$, C), and RD ($R^2 = 0.13$, D) and cognitive scaled scores from voxels in the CC (170 voxels), which showed a significant correlation between FA and cognitive score.

brain was performed around TEA. Written informed parental consent was obtained for all neonates, and this prospective study was approved by the medical ethics committee of our institution.

MR Imaging

MR imaging investigations were performed on a 3T MR imaging system (Achieva, Philips Medical Systems, Best, the Netherlands) by using an 8-channel phased-array SENSE head coil. The infants were sedated with 50–60 mg/kg of chloral hydrate orally, 15 minutes before the MR imaging. Heart rate, transcutaneous oxygen saturation, and respiratory rate were monitored during scanning (Nonin Pulse Oxymeter, Nonin Medical, Plymouth, Minnesota). For hearing protection, MiniMuffs (Natus Europe, Munich, Germany) were used. A neonatologist was present throughout the MR imaging examination.

The MR imaging protocol included sagittal T1-weighted (TR =

886 ms, TE = 15 ms, section thickness = 3.0 mm, number of sections = 31), axial 3D T1-weighted (TR = 9.4 ms, TE = 4.6 ms, section thickness = 2.0 mm, number of sections = 50), and axial T2-weighted imaging (TR = 6293 ms, TE = 120 ms, section thickness = 2.0 mm, number of sections = 50). WM injury was scored as reported previously.¹⁸

In 117/123 neonates, DTI was performed by using a single-shot echo-planar imaging sequence with diffusion gradients in 32 noncollinear directions (TR = 7745 ms, TE = 48 ms, voxel size = $1.41 \times 1.41 \times 2$ mm, number of sections = 50, FOV = 180 mm; scan matrix = 128, foldover direction = anteroposterior, b-value = 800 s/mm^2). In 6 infants, DTI was not performed due to time constraints. The quality of the DTI data and the derived FA maps were evaluated by 2 researchers. Data with artifacts arising from patient motion or technical errors in reconstruction were discarded; the resulting 66/117 (56.4%) neonates had DTI images eligible for further analysis.

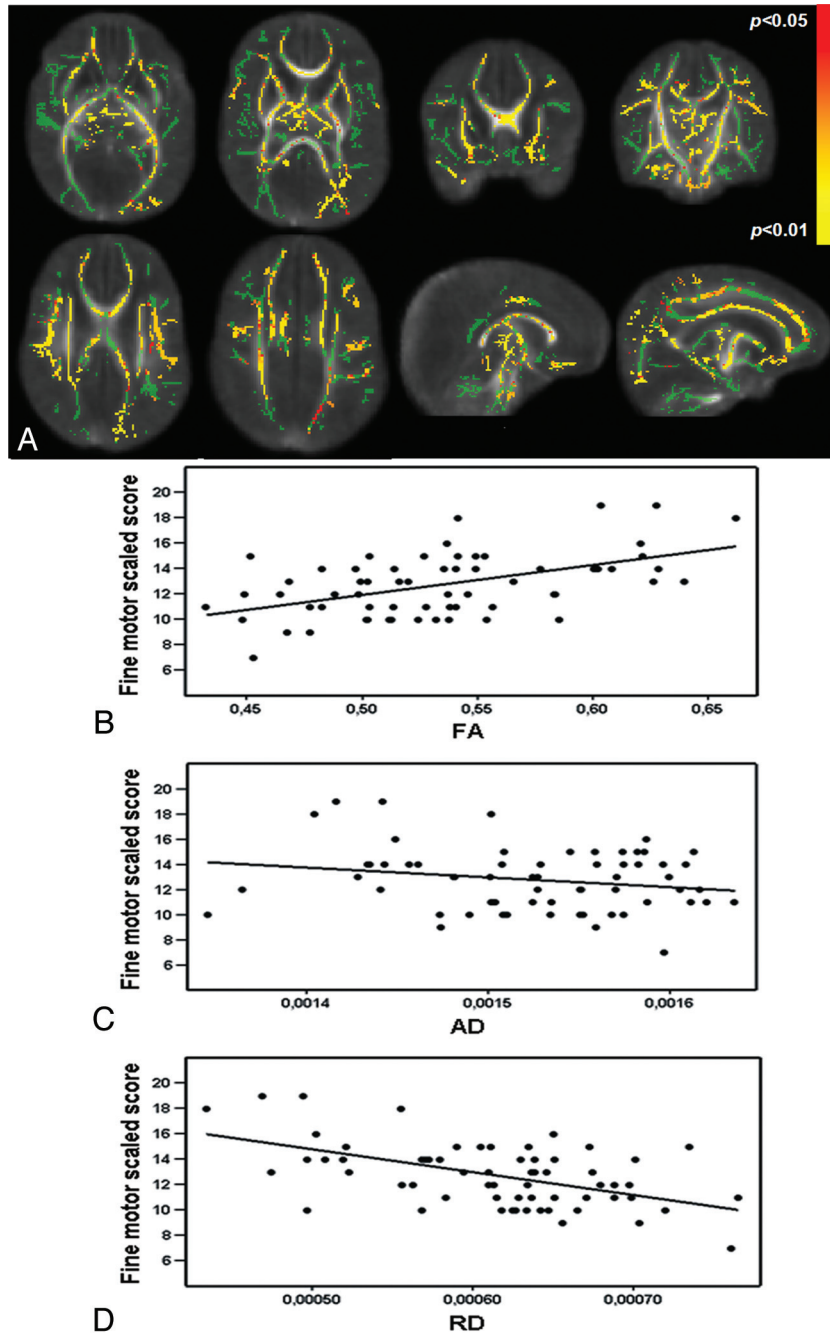


Fig 2. Diffusion parameters in relation to fine-motor scores. Mean FA skeleton (green) overlaid on the mean FA map in the axial, coronal, and sagittal planes. Regions of the mean FA skeleton in green represent voxels in which there is no correlation between FA and fine-motor score. A, Voxels showing a significant correlation between FA and fine-motor scores are in red-yellow. The graphs demonstrate the relationship between FA ($R^2 = 0.26$, B), AD ($R^2 = 0.04$, C), and RD ($R^2 = 0.28$, D) and fine-motor scaled scores from voxels in the left PLIC (45 voxels), which showed a significant correlation between FA and fine-motor score.

Neurodevelopmental Assessment

At 2-year corrected age (mean 24.1 ± 0.3 months), the children were assessed with the BSITD-III by a single developmental specialist who was blinded to the MR imaging findings.¹⁹ Cognition and both fine- and gross-motor function were assessed. The language subtest was not assessed, due to the limited time children are able to concentrate during 1 session. Scaled scores of the 3 subtests and cognitive and total motor composite scores (ie, an overall score for fine- and gross-motor function) were calculated, corrected for prematurity (mean in a normative population: 10 ± 3 and 100 ± 15 , respectively). Three of the 66 children were lost to follow-up; consequently, 63 neonates were included in this study.

Data Analysis

DTI data were analyzed with the FMRIB software library, Version 4.1.4 (www.fmrib.ox.ac.uk/fsl/fsl/downloading.html).²⁰ The DTIs were registered to the $b=0$ image to minimize image artifacts due to eddy current distortions. The skull was removed from the images with the Brain Extraction Tool of FMRIB.²¹ FA, AD, and RD maps were calculated by using the Diffusion Toolbox in FMRIB. All subjects' FA images were aligned to a target in a common space by using an optimized TBSS protocol for neonates.²² Two linear registration steps were performed before nonlinear registration (6° *df* and 12° *df*), to register every subject's FA map to every other one. We selected the

Characteristics	Total (n = 63)
Gestational age, mean in weeks (range)	28.7 ± 1.7 (25.1–30.9)
Birth weight, mean in grams (range)	1146 ± 335 (650–1910)
Male, No. (%)	36 (57.1)
Birthset: singleton/twins, No. (%)	51 (81.0)/12 (19.0)
PPROM, no (%) ^a	13 (20.6)
Antenatal steroids, No. (%) ^b	47 (74.6)
Race, No. (%)	
Caucasian	50 (79.4)
Other	12 (9.0)
Mixed	1 (1.6)
Apgar at 5 minutes, median (range)	9 (5–10)
Late-onset sepsis positive blood culture, No. (%)	23 (36.5)
Days of ventilation, median (range)	5 (0–23)
IVH, No. (%)	
No IVH	46 (73.0)
IVH I	5 (7.9)
IVH II	7 (11.1)
IVH III	4 (6.3)
IVH IV	1 (1.6)
Educational level of mother, No. (%) ^c	
Low	14 (22.2)
Middle	21 (33.3)
High	26 (41.3)
Postmenstrual age, mean in weeks (range) ^d	41.6 ± 1.0 (39.6–44.7)

^a PPRM indicates preterm prolonged rupture of membranes.

^b Two doses of steroids administered 24 hours before labor.

^c Education level according to the CBS (Statistics Netherlands, The Hague, The Netherlands; <http://www.cbs.nl/en-GB/menu/home/default.htm>).

^d Postmenstrual age at the time of the scanning.

target with the minimum mean warp displacement score, and then each infant's FA map was aligned in target space. Following alignment to the target, a mean FA map was created.

A second set of registrations was then performed to register every individual FA map to the mean FA map. The aligned images were then used to create another mean FA map and a mean FA skeleton, which represented the centers of all tracts common to the group. This FA skeleton was thresholded at $FA \geq 0.15$ to exclude peripheral tracts with high intersubject variability and/or partial volume effects with gray matter. Each subjects' aligned FA, AD, and RD data were projected onto this mean FA skeleton. Voxelwise cross-subject statistics was performed to assess the relationship between FA, AD, and RD and performance scores of the BSITD-III, corrected for gestational age and postmenstrual age at the time of the scanning. The results were corrected for multiple comparisons by controlling the family-wise error rate following TFCE.²³

To visualize the relationship between local tissue abnormalities and neurodevelopmental performance scores, we generated regions of interest from areas that demonstrated a significant correlation with FA. Scores for cognitive, fine-motor, and gross-motor performance were plotted against FA, AD, and RD values in these regions (Figs 1–3). In all analyses, a P value $< .05$ was considered statistically significant.

Results

Neonatal details are presented in Table 1. There were no differences in neonatal parameters between the infants included in this study and infants excluded due to the absence of DTI images (of adequate quality), though included infants tended to be older at birth (gestational age, 28.7 and 28.1 weeks, respectively; $P = .054$).

Table 2: Cognitive and motor outcome on the BSITD-III at 2-year corrected age

	Median	Range	Infants with Scores ≤ 1 SD (No.)
Cognition			
Scaled score corrected age ^a	11	6–19	5
Composite score corrected age ^{b,c}	105	80–145	5
Composite score chronologic age ^{c,d}	95	75–130	13
Fine motor: scaled score corrected age ^{a,b}	13	7–19	1
Gross motor: scaled score corrected age ^{a,b}	9	6–15	6
Total motor			
Composite score corrected age ^{b,c}	107	88–133	0
Composite score chronologic age ^{c,d}	97	82–121	4

^a The mean scaled score in a normative population is 10 ± 3 .

^b Corrected age indicates the score corrected for prematurity.

^c The mean composite score in a normative population is 100 ± 15 .

^d Chronologic age indicates the score uncorrected for prematurity.

MR Imaging Findings

During the neonatal period, 17 neonates were diagnosed as having an IVH on cranial sonography, and 3/17 developed posthemorrhagic ventricular dilation requiring treatment. On the basis of the WM scoring system of Woodward et al,¹⁸ 54 (85.7%) neonates displayed normal or mildly abnormal WM and only 9 (14.3%) had moderately abnormal WM. No neonates had severe WM injury or cystic periventricular leukomalacia, though 1 neonate showed a small subcortical cyst frontally and 1 child had a cyst due to a hemorrhage in the temporal lobe.

Neurodevelopmental Outcome

Table 2 shows the results for the BSITD-III scores. Fine-motor scores were significantly higher than gross-motor scores ($P < .001$). No infant developed cerebral palsy or had other major motor deficits. Girls tended to have better cognitive scores than boys ($P = .063$; median scores 11 and 10, respectively). TBSS did not reveal significant differences in FA between females and males.

WM Diffusion Parameters and Neurodevelopment

Cognitive Outcome. Following TFCE correction for multiple comparisons, TBSS showed a positive relationship between FA values in the body and the splenium of the CC and the cognitive scores of the BSITD-III (Fig 1A). The relationship between FA values in the fornix and cognitive outcome just failed to reach significance ($P = .051$). No voxels showed a negative correlation between FA and cognitive score. There was no relation between cognition and AD or RD.

Mean FA, AD, and RD data were extracted from voxels in the CC, showing a significant relationship between FA and cognitive scores. The data were plotted in a graph to visualize the relationship between cognitive scores and FA (Fig 1B, $R^2 = 0.31$), AD (Fig 1C, $R^2 = 0.04$), and RD (Fig 1D, $R^2 = 0.13$).

Fine-Motor Outcome. FA was significantly correlated with fine-motor scores throughout the WM, with many regions significant at a threshold of $P < .01$. The significant regions included the whole CC, fornix, corona radiata, external cap-

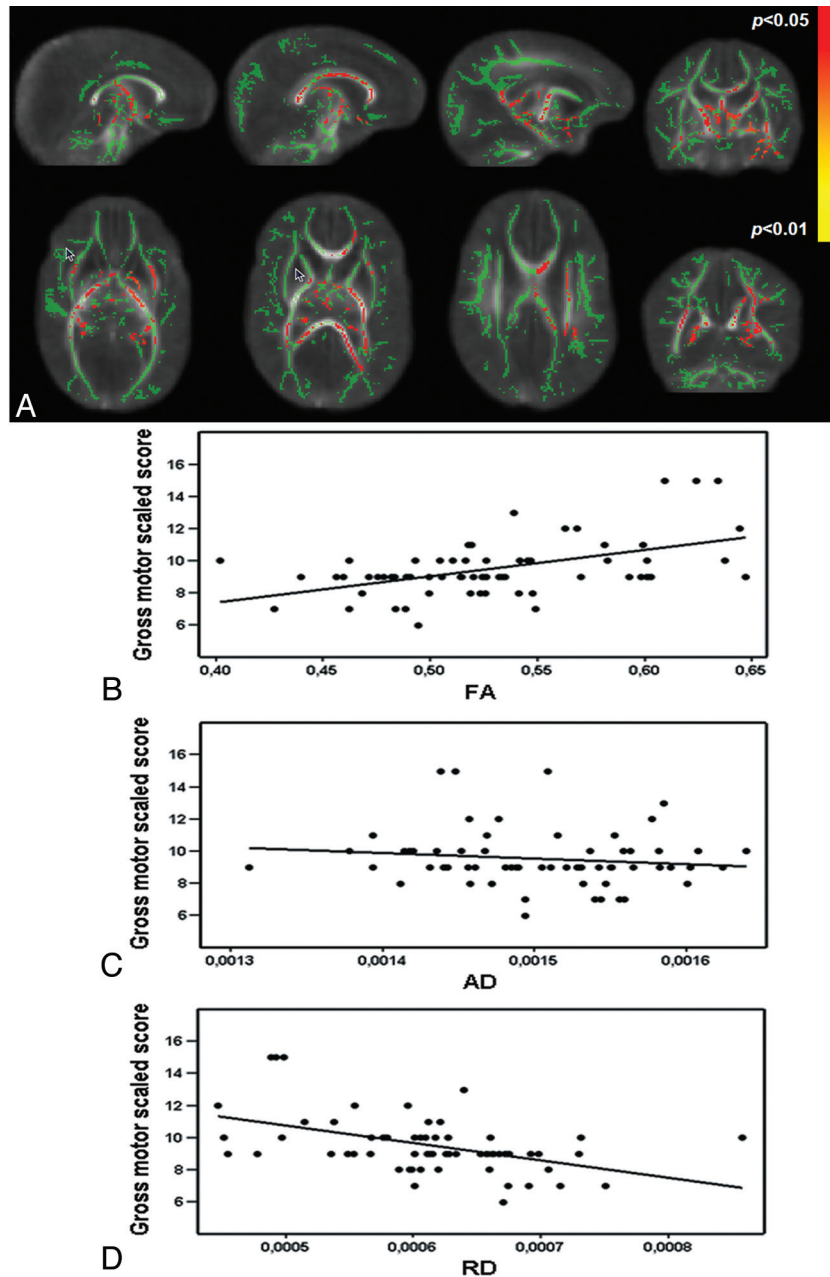


Fig 3. Diffusion parameters in relation to gross-motor scores. Mean FA skeleton (green) overlaid on the mean FA map in the axial, coronal, and sagittal planes. Regions of the mean FA skeleton in green represent voxels where there was no correlation between FA and gross-motor score. A, Voxels showing a significant correlation between RD and gross-motor scores are in red-yellow. The graphs demonstrate the relationship between FA ($R^2 = 0.26$, B), AD ($R^2 = 0.02$, C), and RD ($R^2 = 0.22$, D) and gross-motor scaled scores from voxels in the left PLIC (52 voxels), which showed a significant correlation between FA and gross-motor score.

sule, corticospinal tract from the level of the PLIC to the cerebral peduncle, superior longitudinal fasciculus, inferior longitudinal and fronto-occipital fasciculi, cingulum, and uncinate fasciculus (all bilaterally, except for the uncinate fasciculus and the cingulum, which were only significant on the right side) (Fig 2A). No voxels showed a negative correlation between FA and fine-motor score. There was a significant negative relationship between RD in the PLIC on the right and the corticospinal tract from the level of the PLIC to the cerebral peduncle on the left. There was no relationship between fine-motor score and AD.

Mean FA, AD, and RD data were extracted from voxels in the left PLIC showing a significant relationship between FA and fine-

motor outcome. The data were plotted in a graph to visualize the relation between FA (Fig 2B, $R^2 = 0.26$), AD (Fig 2C, $R^2 = 0.04$), and RD (Fig 2D, $R^2 = 0.28$) and fine-motor score.

Gross-Motor Outcome. Gross-motor function was significantly correlated with FA values in the fornix, the left PLIC, and the thalamus. No voxels showed a negative correlation between FA and gross-motor score. RD displayed a significant negative relationship with gross-motor scores more extensively throughout the WM, including the fornix, CC (mainly left side), PLIC, and posterior part of the cingulum bilaterally (Fig 3A). There was no relation between gross-motor outcome and AD.

Mean FA, AD, and RD data were extracted from voxels in

the left PLIC showing a significant relationship between FA and gross-motor scores. The data were plotted in a graph to visualize the relation between FA (Fig 3B, $R^2 = 0.26$), AD (Fig 3C, $R^2 = 0.02$), and RD (Fig 3D, $R^2 = 0.22$) and gross-motor score.

Total Motor Scores. There was a significant correlation between total motor score and FA values throughout the WM, and many WM regions were significant at a threshold of $P < .01$. The regions included the CC, fornix, corona radiata, external capsule, corticospinal tract from the level of the PLIC to the cerebral peduncle, superior longitudinal fasciculus, inferior longitudinal and fronto-occipital fasciculi, cingulum, and uncinate fasciculus bilaterally. No voxels showed a negative correlation between FA and total motor score. There was a significant negative relationship between total motor score and RD in the CC, fornix, left external capsule, left inferior longitudinal and fronto-occipital fasciculi, corticospinal tracts bilaterally, and the left uncinate fasciculus. There was no relationship between total motor outcome and AD.

Discussion

In this study, TBSS, optimized for the neonatal brain,²² was used for the first time at TEA in preterm infants born before 31 weeks' gestation to assess the relationship between diffusion parameters and neurodevelopmental performance at 2 years of age. TBSS provides an objective and reproducible voxelwise survey of cerebral WM, which reveals features that are consistent across a group of subjects, and avoids subjective selection of locations of interest or hypothesis-based selections of WM regions.¹⁵ Using this approach, we have shown that higher FA in the CC at TEA was associated with better cognitive performance. In addition, a widespread association was demonstrated between FA in the major WM tracts and fine-motor performance whereas gross-motor scores were associated with FA values in the PLIC, fornix, and thalamus. The findings for total motor scores were similar to those for fine-motor scores, suggesting that our results for the total motor scores were largely influenced by fine-motor performance and not by gross-motor abilities.

The increase in FA with respect to better BSITD-III scores observed here was mainly driven by a decrease in RD. The relationship between diffusion measures (eg, FA and RD) and underlying WM microstructure is complex. The increase in FA observed with increasing maturation is largely due to a decrease in RD.^{11,12} FA is largely dependent on axonal thickness, axonal attenuation, and myelination.^{24,25} The development of oligodendroglia precursors induces anisotropy in WM in a process primarily driven by changes in RD.²⁶ At TEA, only the PLIC and the brain stem are myelinated,²⁷ so the reduction in FA in association with subsequent poor neurodevelopment demonstrated here probably represents deficits or delays in premyelination events such as increasing axonal thickness, alterations in axonal permeability, and premyelination wrapping of the oligodendrocyte around the axon.²⁸

We recognize that cognitive deficits are difficult to diagnose in early childhood and usually first become evident at school age.² Nevertheless, our findings of altered WM microstructure in the CC and impaired cognitive ability are supported by previous studies that assessed callosal macrostructure and demonstrated that reduced callosal volume on

conventional MR imaging was related to impaired cognitive development in children and adolescents born prematurely.^{29,30} Furthermore, Schmithorst et al³¹ observed a positive relationship between FA in association fibers and intelligence quotient in a healthy pediatric population, consistent with our findings of higher FA in association tracts and better neurocognitive performance.

Using a region-of-interest–based approach to assess DTI data, Rose et al³² examined FA in the anterior limb of the internal capsule, PLIC, and genu and splenium of the CC. They observed a relationship between FA in the PLIC at TEA and the psychomotor score of the BSITD-II at 18-month corrected age. Using TBSS to survey whole brain WM, we have shown that this relationship exists more extensively throughout the WM. The regions where we observed a positive correlation between fine-motor score and FA values were more extensive than those for gross-motor score. In addition to the PLIC and the corticospinal tracts, a correlation with FA was found in the association tracts, including the cingulum, fornix, uncinate fasciculus, and frontal WM.

The frontal lobes are involved in working memory, planning, monitoring, and organizing retrieval processes.³³ The uncinate fasciculus provides a corticocortical link between the frontal and temporal lobes and is thought to be important in episodic memory.³⁴ The cingulum is involved with high-order motor control and organization of motor-control processes.³⁵ Lesions in this region are associated with deficits in working-memory performance,³⁶ and reduced FA in the cingulum in schizophrenia is associated with attention and working-memory deficits.³⁷ The fornix connects the hippocampus to the hypothalamus, and lesions in this structure are associated with memory and learning dysfunctions.^{38,39} These regions, therefore, are associated with working memory and manipulating information, processes that are assessed in the fine-motor component of the BSITD-III. In this study, we observed that better gross-motor function was related to a region of higher FA in the left PLIC, while decreased RD was correlated with gross-motor outcome in many regions throughout the brain. On examination of those voxels in the left PLIC showing a significant relationship between FA and gross-motor scores, we observed a strong positive correlation between AD and RD. These findings may explain the lack of association between FA and gross-motor scores, because an increase in both AD and RD could leave FA relatively unchanged.

Previous studies have used voxel-based approaches to assess the relationship between WM microstructure and performance in children who were born preterm. Skranes et al⁴⁰ assessed adolescents born prematurely and age-matched term-born controls. They found lower FA in the internal and external capsules, CC, and the inferior and superior longitudinal fasciculi in the preterm group. Most important, lower FA in these areas was related to worse performance on the visual-motor integration and the Grooved Pegboard tests. At 2 years of age, subscores of the Griffiths Mental Developmental Scales were related to FA in the CC, cingulum, fornix, anterior commissure, and the right uncinate fasciculus.¹⁷ Our results suggest that the relationship between WM integrity and neurodevelopment, demonstrated by others in children born prematurely, is already evident at TEA.

We were able to analyze only 56% of the DTI data. DTI data

are inherently sensitive to artifacts due to patient motion. Although the infants were sedated and noise reduction was administered, some infants woke up during the DTI sequence. In addition, some data were acquired with a sensitivity encoding factor of 3, which resulted in a lower signal intensity-to-noise ratio and visible artifacts across the brain, so these datasets were rejected. Nevertheless, our study group was relatively large, consisting of 63 infants with data amenable to analysis by using TBSS. This study used DTI data acquired at 3T, which offers a higher signal intensity-to-noise ratio and allows improved spatial resolution than could be achieved at lower field strengths. However, at the resolution achievable in vivo, the imaging voxels will inevitably contain fiber populations with different orientations, resulting in a reduction in the measured FA.

A further limitation of this approach is that TBSS is not always able to assess WM where there is an abrupt change in direction of the fiber pathway, for example at the junction of tracts.¹⁵ Finally, these findings were restricted to preterm infants, without the possibility to compare the results with healthy full-term controls. We accept that the lack of healthy term-born controls is a limitation of this study. However, previous studies have already shown differences between preterm infants at term and healthy term-born controls.^{9,16} Our aim here was to explore the relationship between WM injury and early neurodevelopmental performance in the preterm population.

Conclusions

An increase in FA and a decrease in RD in specific WM regions in preterm infants at TEA were related to cognitive, fine-motor, and gross-motor outcome at 2-year corrected age. These findings support the potential of diffusion parameters, obtained in preterm infants at TEA, as biomarkers for subsequent neurodevelopmental performance.

Acknowledgments

We are grateful to the families who took part in the study and to our colleagues of the neonatal intensive care unit and the MR imaging technicians for their expertise and enthusiastic help.

References

- Saigal S, Doyle LW. An overview of mortality and sequelae of preterm birth from infancy to adulthood. *Lancet* 2008;371:261–69
- Latal B. Prediction of neurodevelopmental outcome after preterm birth. *Pediatr Neurol* 2009;40:413–19
- Volpe JJ. Cerebral white matter injury of the premature infant: more common than you think. *Pediatrics* 2003;112:176–80
- Huppi PS, Dubois J. Diffusion tensor imaging of brain development. *Semin Fetal Neonatal Med* 2006;11:489–97
- Le Bihan D, Breton E, Lallemand D, et al. MR imaging of intravoxel incoherent motions: application to diffusion and perfusion in neurologic disorders. *Radiology* 1986;161:401–07
- Moseley ME, Cohen Y, Kucharczyk J, et al. Diffusion-weighted MR imaging of anisotropic water diffusion in cat central nervous system. *Radiology* 1990;176:439–45
- Dubois J, Dehaene-Lambertz G, Perrin M, et al. Asynchrony of the early maturation of white matter bundles in healthy infants: quantitative landmarks revealed noninvasively by diffusion tensor imaging. *Hum Brain Mapp* 2008;29:14–27
- Miller SP, Vigneron DB, Henry RG, et al. Serial quantitative diffusion tensor MRI of the premature brain: development in newborns with and without injury. *J Magn Reson Imaging* 2002;16:621–32
- Huppi PS, Maier SE, Peled S, et al. Microstructural development of human newborn cerebral white matter assessed in vivo by diffusion tensor magnetic resonance imaging. *Pediatr Res* 1998;44:584–90

- Neil JJ, Shiran SI, McKinstry RC, et al. Normal brain in human newborns: apparent diffusion coefficient and diffusion anisotropy measured by using diffusion tensor MR imaging. *Radiology* 1998;209:57–66
- Partridge SC, Mukherjee P, Henry RG, et al. Diffusion tensor imaging: serial quantitation of white matter tract maturity in premature newborns. *Neuroimage* 2004;22:1302–14
- Suzuki Y, Matsuzawa H, Kwee IL, et al. Absolute eigenvalue diffusion tensor analysis for human brain maturation. *NMR Biomed* 2003;16:257–60
- Cheong JL, Thompson DK, Wang HX, et al. Abnormal white matter signal on MR imaging is related to abnormal tissue microstructure. *AJNR Am J Neuroradiol* 2009;30:623–28
- Counsell SJ, Shen Y, Boardman JP, et al. Axial and radial diffusivity in preterm infants who have diffuse white matter changes on magnetic resonance imaging at term-equivalent age. *Pediatrics* 2006;117:376–86
- Smith SM, Jenkinson M, Johansen-Berg H, et al. Tract-based spatial statistics: voxelwise analysis of multi-subject diffusion data. *Neuroimage* 2006;31:1487–505
- Anjari M, Srinivasan L, Allsop JM, et al. Diffusion tensor imaging with tract-based spatial statistics reveals local white matter abnormalities in preterm infants. *Neuroimage* 2007;35:1021–27
- Counsell SJ, Edwards AD, Chew AT, et al. Specific relations between neurodevelopmental abilities and white matter microstructure in children born preterm. *Brain* 2008;131:3201–08
- Woodward LJ, Anderson PJ, Austin NC, et al. Neonatal MRI to predict neurodevelopmental outcomes in preterm infants. *N Engl J Med* 2006;355:685–94
- Bayley N. *Bayley Scales of Infant and Toddler Development*. 3rd ed. San Antonio, Texas: Harcourt Assessment; 2006
- Smith SM, Jenkinson M, Woolrich MW, et al. Advances in functional and structural MR image analysis and implementation as FSL. *Neuroimage* 2004;23(suppl 1):S208–19
- Smith SM. Fast robust automated brain extraction. *Hum Brain Mapp* 2002;17:143–55
- Ball G, Counsell SJ, Anjari M, et al. An optimised tract-based spatial statistics protocol for neonates: applications to prematurity and chronic lung disease. *Neuroimage* 2010;53:94–102. Epub 2010 May 25
- Smith SM, Nichols TE. Threshold-free cluster enhancement: addressing problems of smoothing, threshold dependence and localisation in cluster inference. *Neuroimage* 2009;44:83–98
- Sakuma H, Nomura Y, Takeda K, et al. Adult and neonatal human brain: diffusion anisotropy and myelination with diffusion-weighted MR imaging. *Radiology* 1991;180:229–33
- Takagi T, Nakamura M, Yamada M, et al. Visualization of peripheral nerve degeneration and regeneration: monitoring with diffusion tensor tractography. *Neuroimage* 2009;44:884–92
- Drobyshevsky A, Song SK, Gamkrelidze G, et al. Developmental changes in diffusion anisotropy coincide with immature oligodendrocyte progression and maturation of compound action potential. *J Neurosci* 2005;25:5988–97
- Yakovlev PI, Lecours AR. The myelogenetic cycles of regional maturation of the brain. In: Minkowski A, ed. *Regional Development of the Brain in Early Life*. Oxford, UK: Blackwell Scientific Publications; 1967:3–70
- Wimberger DM, Roberts TP, Barkovich AJ, et al. Identification of “premyelination” by diffusion-weighted MRI. *J Comput Assist Tomogr* 1995;19:28–33
- Caldu X, Narberhaus A, Junque C, et al. Corpus callosum size and neuropsychologic impairment in adolescents who were born preterm. *J Child Neurol* 2006;21:406–10
- Peterson BS, Vohr B, Staib LH, et al. Regional brain volume abnormalities and long-term cognitive outcome in preterm infants. *JAMA* 2000;284:1939–47
- Schmithorst VJ, Wilke M, Dardzinski BJ, et al. Cognitive functions correlate with white matter architecture in a normal pediatric population: a diffusion tensor MRI study. *Hum Brain Mapp* 2005;26:139–47
- Rose J, Butler EE, Lamont LE, et al. Neonatal brain structure on MRI and diffusion tensor imaging, sex, and neurodevelopment in very-low-birth-weight preterm children. *Dev Med Child Neurol* 2009;51:526–35
- Kopelman MD. Disorders of memory. *Brain* 2002;125:2152–90
- Klingler J, Gloor P. The connections of the amygdala and of the anterior temporal cortex in the human brain. *J Comp Neurol* 1960;115:333–69
- Aralasmak A, Ulmer JL, Kocak M, et al. Association, commissural, and projection pathways and their functional deficit reported in literature. *J Comput Assist Tomogr* 2006;30:695–715
- Petrides M, Milner B. Deficits on subject-ordered tasks after frontal- and temporal-lobe lesions in man. *Neuropsychologia* 1982;20:249–62
- Kubicki M, Westin CF, Nestor PG, et al. Cingulate fasciculus integrity disruption in schizophrenia: a magnetic resonance diffusion tensor imaging study. *Biol Psychiatry* 2003;54:1171–80
- Park SA, Hahn JH, Kim JI, et al. Memory deficits after bilateral anterior fornix infarction. *Neurology* 2000;54:1379–82
- Aggleton JP, McMackin D, Carpenter K, et al. Differential cognitive effects of colloid cysts in the third ventricle that spare or compromise the fornix. *Brain* 2000;123(pt 4):800–15
- Skranes J, Vangberg TR, Kulseng S, et al. Clinical findings and white matter abnormalities seen on diffusion tensor imaging in adolescents with very low birth weight. *Brain* 2007;130:654–66