

Are your **MRI contrast agents** cost-effective?

Learn more about generic **Gadolinium-Based Contrast Agents**.



**FRESENIUS  
KABI**

caring for life

**AJNR**

**Flat Panel Catheter Angiotomography of the Spinal Venous System: An Enhanced Venous Phase for Spinal Digital Subtraction Angiography**

J. Chen, T. Ethiaty and P. Gailloud

This information is current as of April 18, 2024.

*AJNR Am J Neuroradiol* 2012, 33 (10) 1875-1881

doi: <https://doi.org/10.3174/ajnr.A3111>

<http://www.ajnr.org/content/33/10/1875>

J. Chen  
T. Ethiat  
P. Gailloud

# Flat Panel Catheter Angiotomography of the Spinal Venous System: An Enhanced Venous Phase for Spinal Digital Subtraction Angiography

**BACKGROUND AND PURPOSE:** While spinal DSA remains the reference standard technique for spinovascular imaging, visualizing spinal veins remains challenging due to their small size and motion artifacts. This study evaluates the ability of FPCA to overcome these obstacles.

**MATERIALS AND METHODS:** Sixty-three FPCAs, performed by intersegmental artery injections in 57 patients, were prospectively evaluated. Entrance skin doses were compared with standard spinal DSA runs, including a venous phase and cerebral FPCAs. FPCA contributions were stratified as 1) provided no added information, 2) complemented spinal DSA findings, 3) assisted therapy planning, and 4) contributed principal diagnostic findings.

**RESULTS:** No complications were observed. Diagnoses included vascular malformations (44%), stroke (9%), venous anomalies (10%), other (9%), and unremarkable (28%). Mean entrance skin doses were of 419 mGy for FPCA, 161 mGy for spinal DSA with venous phase, and 309 mGy for cerebral FPCAs. FPCA contributed the principal diagnostic finding in 16 cases (25.4%), assisted therapy planning in 13 cases (20.6%), complemented spinal DSA findings in 12 cases (19.1%), and provided no additional information in 20 cases (31.7%). In 8 of these 20 cases, FPCA documented a spinal venous anatomy that was poorly visualized or not visualized on spinal DSA.

**CONCLUSIONS:** Spinal FPCA is safe, with a moderate increase in radiation dose, compared with spinal DSA with venous phase or cerebral FPCA. It proved particularly valuable for therapy planning and the diagnosis of venous abnormalities. This study suggests that FPCA has an important role to play in the evaluation of the spinal venous system.

**ABBREVIATIONS:** FPCA = flat panel catheter angiotomography; MIP = maximum intensity projection

Spinal DSA is the reference standard technique for the evaluation of the spinal vasculature. Noninvasive spinovascular imaging has improved over the last decade but remains inferior to spinal DSA in terms of spatial and time resolutions. Investigating the spinal venous system continues to be a challenge for invasive and noninvasive methods alike. While high-quality venous images are routinely acquired during cerebral angiograms, venous structures are difficult to assess during spinal DSA, despite their established diagnostic importance.<sup>1</sup> Poor visualization of the spinal venous system mainly results from technical limitations, such as small vessel size, single plane acquisition, and motion artifacts.

Once considered a hazardous technique, spinal DSA is now routinely performed with extremely low complication rates.<sup>2</sup> Modern neuroangiography suites have helped reduce the radiation dose and injected contrast volume while improving imaging quality. The potential role of 3D-DSA, now considered the reference standard for the detection of cerebrovascular conditions such as aneurysms,<sup>3,4</sup> has been established for the spinal vasculature as well.<sup>5</sup> A new technique producing

nonsubtracted tomographic images from datasets obtained during conventional angiography has been recently introduced. Often called C-arm CT or conebeam CT angiography, this technique is better designated as FPCA to emphasize its defining characteristics, that is, tomographic reconstructions of a catheter angiogram obtained with a flat panel detector. FPCA has shown promise in the evaluation of spinal dural arteriovenous fistulas.<sup>6</sup> This report describes our experience with selective spinal FPCA in 57 patients and illustrates its unique ability to image the spinal venous system.

## Materials and Methods

### Patient Population

Sixty-three FPCAs were obtained during 59 spinal angiograms, performed in 57 patients by the senior author between August 2009 and September 2011. FPCA was acquired in 47% of the total number of diagnostic spinal angiograms performed during this time period (125 studies). FPCAs evaluating the cervical spinal cord by injection of subclavian branches, or obtained during therapeutic procedures were not included in this series. The 57 patients included 18 females and 39 males, with ages ranging from 3 months to 88 years. Most were investigated as outpatients under conscious sedation, general anesthesia being used in 8 instances (including 3 children). Principal indications for spinal DSA included vascular malformation, progressive myelopathy of unclear etiology, acute myelopathy of suspected vascular nature, and spinal cord tumors. All patients were prospectively entered in an institutional review board—approved data base. Additional institutional review board approval was obtained to report this series.

Received November 18, 2011; accepted after revision January 30, 2012.

From the Division of Interventional Neuroradiology (J.C., T.E., P.G.), The Johns Hopkins Hospital, Baltimore, Maryland, and Siemens Corporate Research (T.E.), Princeton, New Jersey.

Please address correspondence to Philippe Gailloud, MD, Division of Interventional Neuroradiology, The Johns Hopkins Hospital, 600 N Wolfe St., Baltimore, MD 21287; e-mail: phg@jhmi.edu

<http://dx.doi.org/10.3174/ajnr.A3111>

### **Imaging Technique**

FPCA studies were performed by selective thoracolumbar intersegmental injections in a neuroangiography suite (Artis zee, Siemens, Erlangen, Germany) using a standard 20-second acquisition (Dyna-CT, Siemens). Vessel opacification was obtained with a nonionic iodinated contrast agent (300 mgI/mL) diluted with normal saline (75% saline, 25% contrast). FPCA was used as a complement to spinal DSA to further characterize a lesion detected during angiography or to better evaluate the perimedullary venous system if a venous anomaly was suggested by noninvasive imaging (for example, abnormal enhancement documented by MR imaging). In the latter instance, the branch whose injection would result in the best opacification of the venous compartment harboring the anomaly was selected. In 50 instances (79.3%), the injected vessel was providing a spinal axis contributor, that is, the artery of Adamkiewicz in 40 cases, a lesser branch in 10 cases. Contrast injections were performed either by hand using a 30-mL syringe (contrast volume 7.5 mL) or with an automatic injector (contrast volume 12.5 mL). The rotational datasets were reconstructed using high-resolution matrices (up to 0.1-mm voxel size).

### **Radiation Dose**

The radiation dose associated with spinal FPCA was evaluated by comparing average doses calculated by the equipment with the values reported for 20 cranial FPCAs obtained during routine cerebral angiograms. Comparison was also made with standard angiographic runs performed at the same level to document the spinal venous phase (13- to 18-second sequences at 2 frames per second) in 6 consecutive patients.

### **Clinical Impact**

FPCA impact was assessed by classifying studies under the following categories: 0 = FPCA technically unsuccessful; 1 = no significant contribution to the diagnosis, even though good quality images were obtained; 2 = significant information complementing the data gathered by spinal DSA (ie, confirming the presence of a suspected vascular malformation or clarifying its nature); 3 = FPCA used to plan subsequent endovascular or surgical treatment; and 4 = final diagnosis based principally or solely on FPCA findings. For the studies listed in category 1, the number of cases in which the perimedullary venous system was visualized by FPCA, but poorly or not at all by spinal DSA, was also recorded.

### **Results**

The targeted intersegmental artery and its branches were successfully opacified during rotational angiography in all cases. No immediate or delayed complication, neurologic or other, was noted in this series. The 20-second injection was well tolerated by patients under conscious sedation, with no report of pain or discomfort. Adequate opacification of the perimedullary venous system was obtained in all but 3 patients with progressive myelopathy. In the first case, MR imaging showed diffuse spinal cord hyperintensity, no flow voids, and no evidence of normal or abnormal vessel enhancement after gadolinium injection. While the arterial phase of spinal DSA was unremarkable, perimedullary venous structures were not detected during the venous phase. FPCA showed complete absence of perimedullary vein visualization despite adequate spinal arterial opacification, leading to the diagnosis of spinal venous thrombosis. In the other 2 cases, the absence of visible perimedullary veins on spinal DSA and FPCA was related to

the presence of subsequently diagnosed spinal dural arteriovenous fistulas. Venous opacification with FPCA thus showed sensitivity to the effect of venous hypertension and contrast dilution produced by high-flow vascular malformations, an effect well documented with spinal DSA.<sup>1,7</sup> Motion artifacts reducing image quality were observed in 3 instances, including 2 patients with intermittent and uncontrollable leg spasms, and 1 patient who moved during the rotational acquisition. In 2 of these cases, FPCA reconstructions were below diagnostic quality (category 0).

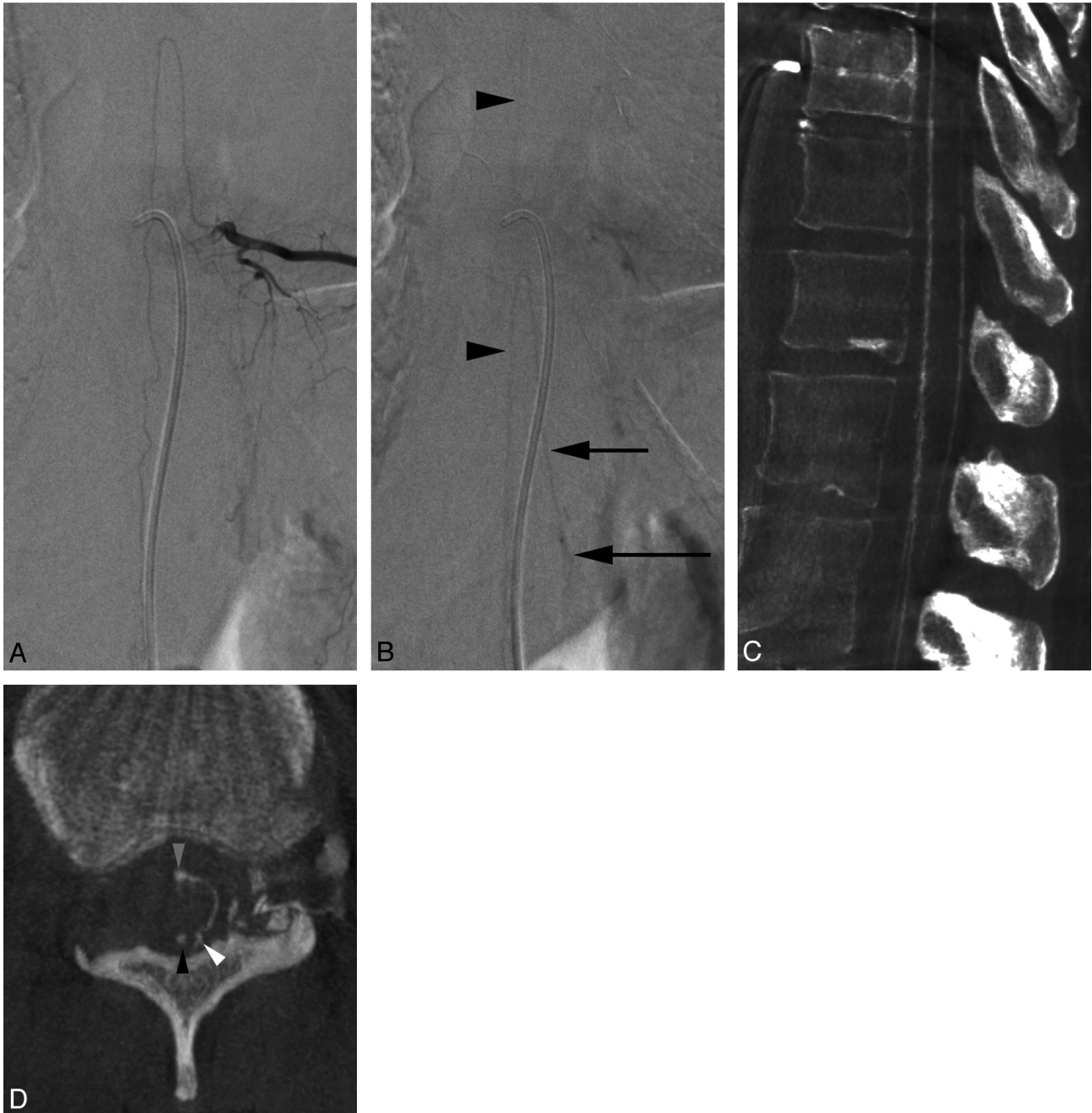
The mean radiation dose measured during spinal FPCA was approximately 35% higher than for cranial FPCA (419 mGy, SD 59, range 198–567 versus 309 mGy, SD 53, range 97–367) and corresponds, on average, to 2.5 times the radiation dose measured for standard angiography runs performed in the same patient at the same level to visualize the venous phase (12- to 18-second runs at 2 frames per second; 419 mGy, SD 59, range 198–567 versus 161 mGy, SD 46, range 107–221). This comparison underestimates the dose ratio for operators by using a lower frame rate during spinal angiography (ie, 1 pulse per second).

FPCA was technically unsuccessful (category 0) in 2 instances where severe motion artifacts hindered perimedullary venous system visualization (3.2%). In 20 instances (31.7%), FPCA provided good quality images of the perimedullary venous system without influencing the final diagnosis (category 1). In 8 of these patients, FPCA documented the perimedullary venous system, while a venous phase was not identified by spinal DSA. In 25 instances (categories 2 and 3; 39.7%), FPCA complemented the information gathered by spinal DSA in a significant manner, by confirming or further characterizing a lesion suspected by spinal DSA (12 cases, 19.1%) or by helping treatment planning (13 cases, 20.6%). Finally, in 16 instances (25.4%), the final angiographic diagnosis was based principally or solely on the information offered by FPCA, including cases of spinal venous anomalies associated with cavernomas and spinal varices.

The final diagnoses in our 59 patients include high-flow vascular malformations (25 cases, 43.9%), spinal venous anomalies (6 cases, 10.5%), stroke/venous thrombosis (5 cases, 8.8%), other (including spinal cord tumors; 5 cases, 8.8%), or unremarkable spinal DSA (16 cases, 28.1%). Three studies have been selected to illustrate the ability of FPCA to image the spinal venous anatomy (case 1), further characterize vascular abnormalities detected by spinal DSA (case 2), or identify venous anomalies suspected by MR imaging but not documented by spinal DSA (case 3).

### **Illustrative Cases**

**Case 1.** A 47-year-old woman presented with a 3-year history of progressive myelopathy with leg weakness and bladder dysfunction. Fig 1A shows a selective injection of left T10, which provides the artery of Adamkiewicz. This lean patient was able to hold her breath during the entire length of the acquisition. Fig 1B illustrates the appearance of the perimedullary venous system under these optimal conditions, while Figs 1C–E show FPCA images obtained by injection of the same intersegmental artery, with the patient breathing normally. The sagittal projection identifies venous structures coursing over the anterior and posterior aspects of the spinal



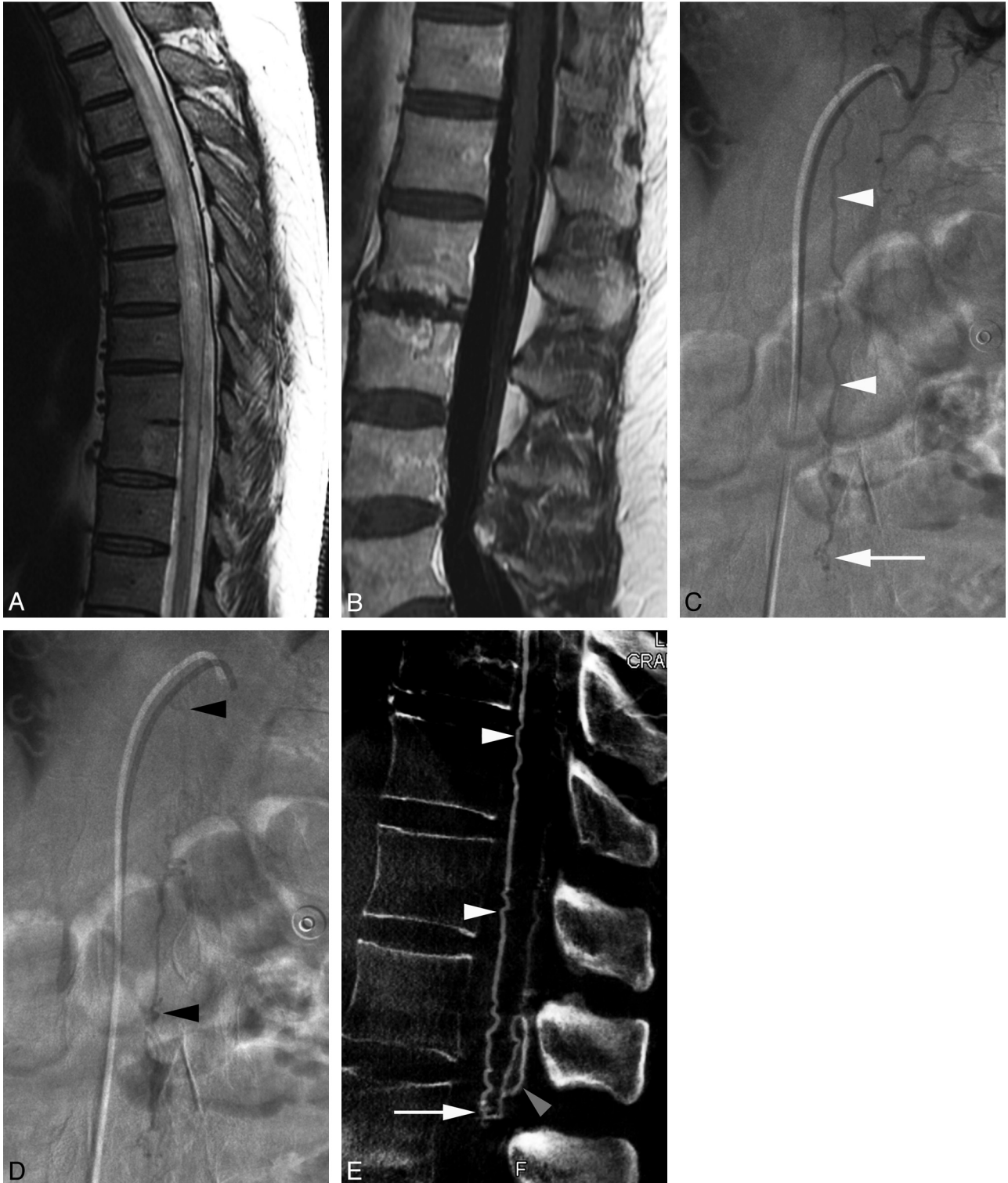
**Fig 1.** 47-year-old woman investigated for progressive myelopathy. *A*, Spinal DSA, left T10 injection, arterial phase, documenting the artery of the lumbosacral enlargement (artery of Adamkiewicz). *B*, Spinal DSA, left T10 injection, venous phase, illustrating the typical appearance of the perimedullary venous system during spinal angiography performed under optimal conditions, that is, with a lean patient able to hold breath long enough to prevent motion artifacts. The anterior spinal venous axis is seen (arrowheads), as well as a medullary vein (short arrow) draining into the internal vertebral venous plexus (long arrow). *C*, FPCA, left T10 injection, sagittal MIP, voxel size = 0.4, section thickness = 1.8. The anterior and posterior perimedullary venous systems are easily differentiated. On FPCA, depending on the level of injection, overlapping may exist between arterial and venous structures related to the length of the rotational acquisition (20 seconds). *D*, FPCA, left T10 injection, axial MIP, voxel size = 0.1, section thickness = 4.0. The axial projection best characterizes this anastomosis, showing its course over the lateral of the spinal cord, connecting the anterior spinal vein (gray arrowhead) to a right posterior-lateral vein (white arrowhead), separate from the posterior spinal vein (black arrowhead). Because of their close topographic relationship and the thickness of the section (4.0 mm), the anterior spinal vein (gray arrowhead) and the anterior spinal artery are particularly difficult to separate in this image. The lack of dynamic information in FPCA can render the distinction between adjoining arteries and veins difficult; correct interpretation is helped by the analysis of the course and connection pattern of the vessels, the use of different reconstruction planes, or the correlation with the spinal DSA information.

cord (Fig 1C). Simultaneous opacification of anterior and posterior perimedullary veins is consistent with the presence of anastomotic connections linking the 2 systems.<sup>8</sup> A transverse perimedullary anastomosis coursing over the left lateral surface of the cord is documented in the axial plane (Fig 1D).

**Case 2.** A 57-year-old man with a 4-year history of progressive leg weakness consulted after the new onset of bowel and

bladder incontinence. MR imaging showed diffuse spinal cord edema (Fig 2A), with mild venous enhancement around the conus medullaris (Fig 2B). Spinal DSA revealed a perimedullary arteriovenous fistula (type 1) of the conus medullaris, fed by the descending ramus of an anterior spinal contributor originating from left T10 (Fig 2, C-D). FPCA of the same artery complemented this information by documenting, in par-





**Fig 2.** 57-year-old man with a perimedullary arteriovenous fistula of the conus medullaris. *A*, MR imaging, sagittal T2-weighted image of the thoracic spine, showing diffuse spinal cord swelling and hyperintensity; *B*, MR imaging, sagittal T1-weighted image after gadolinium administration of the lumbar spine. Note the presence of enhancing venous structures around the conus medullaris and along the filum terminale. *C*, Spinal DSA, left T10 injection, anteroposterior view, early arterial phase, showing a prominent descending ramus of the anterior spinal artery (*white arrowheads*) reaching the level of the conus medullaris, where a small tangle of blood vessels may be seen (*arrow*). *D*, Spinal DSA, left T10 injection, anteroposterior view. In the late arterial phase, while the vascular tangle is still visible, extensive opacification of the perimedullary venous system is noted (*black arrowheads*). *E*, FPCA, left T10 injection, sagittal MIP, voxel size = 0.4, section thickness = 3.0, demonstrating the anterior spinal artery (*white arrowheads*) ending at the tip of the conus medullaris (L1/L2) into a Type I perimedullary arteriovenous fistula (*arrow*). The posterior location of the enlarged draining veins detected by spinal DSA is well documented on this sagittal reconstruction (*gray arrowhead*).

ticular, the exact location of the shunt and abnormal perimedullary veins detected by spinal DSA, later confirmed during surgical treatment (Fig 2E). High-resolution multiplanar re-

constructions offered a detailed analysis of the lesion morphologic and topographic characteristics that was used for subsequent surgical therapy planning.

**Case 3.** A 58-year-old woman presented with constant, slowly progressive thoracic pain at the midscapular level. The suspicion of vascular malformation was raised by the documentation of dilated enhancing venous structures along the posterior aspect of the spinal cord between T8 and T12 (Fig 3A). Spinal DSA was unremarkable. The venous anomalies documented by MR imaging were, however, not observed during the venous phase of the angiogram, raising concerns for an overlooked vascular lesion (Fig 3, B-C). FPCA performed by injection of the intersegmental artery providing the artery of Adamkiewicz (left T11) offered an excellent visualization of the venous system, including a segmental varicosity corresponding to the suspicious structure detected by MR imaging (Fig 3, D-E). Fig 3F documents a narrowing of the radiculomedullary vein as it pierces the dura, which corresponds to the antireflux mechanism described by several authors.<sup>9,10</sup>

## Discussion

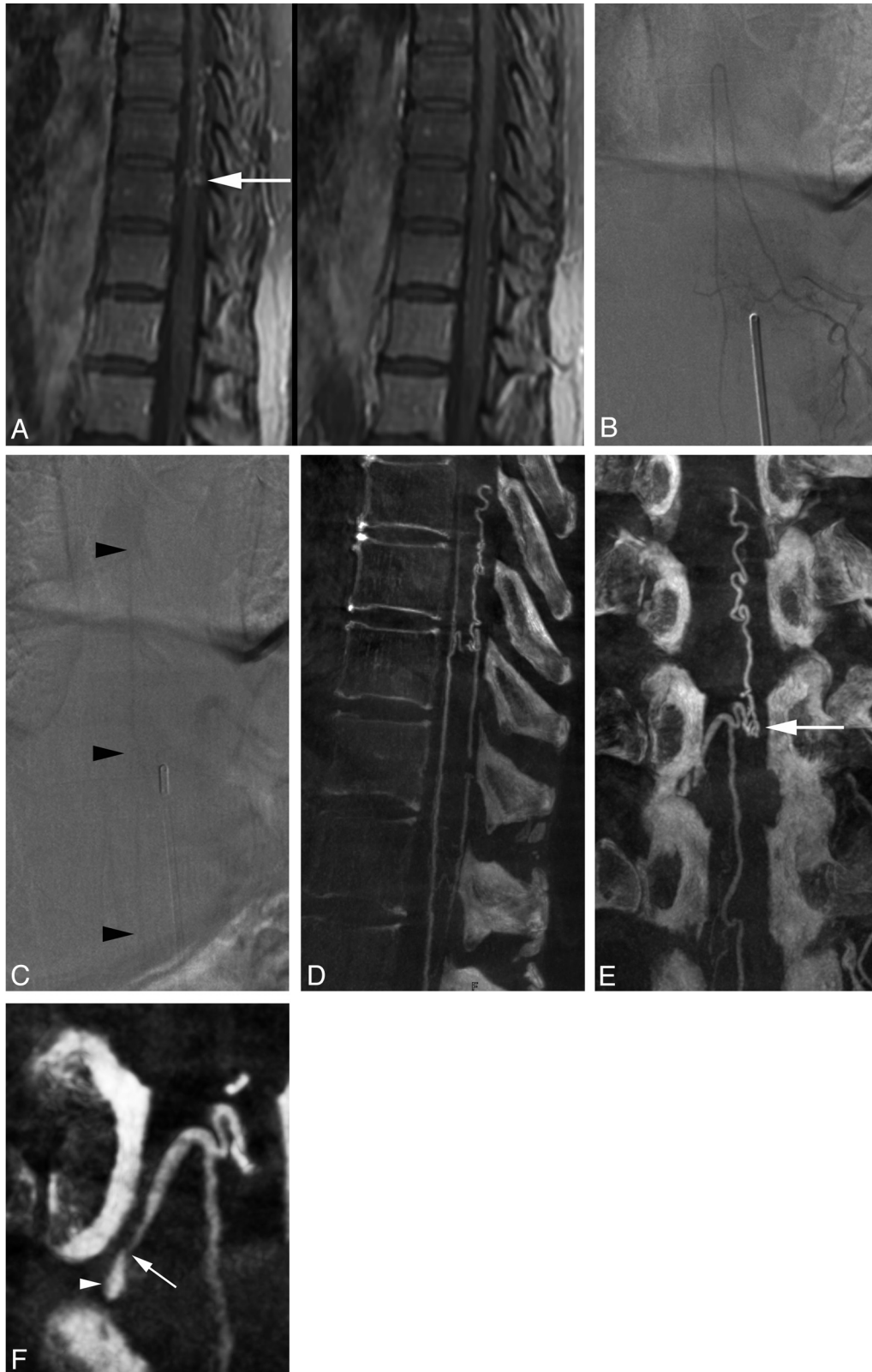The concept of angiotomography, a method combining x-ray tomography with selective arterial injections, was introduced by Liese in 1960 to investigate the aorta and its branches.<sup>11</sup> The role of angiotomography for the evaluation of the cranial arterial system was later emphasized by du Boulay and Jackson,<sup>12</sup> while Fredzell and Greitz reported its use in cervical phlebography.<sup>13</sup> Djindjian and colleagues introduced both nonselective and selective spinal angiography in 1963<sup>14</sup> and 1966,<sup>15</sup> respectively, while selective spinal angiotomography, first proposed by Djindjian, was used by Merland and coworkers to help characterize spinal vascular malformations in 1980.<sup>7</sup> The introduction of FPCA represents the latest innovation made in the field of angiotomography. In 2005, Zellerhoff et al<sup>16</sup> described the utilization of C-arm mounted flat panel detectors to produce low-contrast 3D reconstructions of soft tissue structures. Similar systems were then used to generate both volumetric CT-like datasets and 3D angiographic images.<sup>16,17</sup> This new angiography-based technique was, in large part, rendered possible by the advent of flat panel detector technology, which offers higher dynamic range and digital readout rates than regular image intensifiers, therefore achieving higher contrast and spatial resolutions. C-arm mounted flat panel systems provide a higher isotropic spatial resolution than multisection CT. Applications taking advantage of the unique characteristics of this new imaging technique are now flourishing, both in the neurovascular and peripheral vascular fields.<sup>18,19</sup>

The role of 3D-DSA as a complement to spinal DSA for the analysis of spinovascular anomalies was emphasized by Prestigiacomo and coauthors.<sup>5</sup> FPCA provides high-resolution native images of the arterial and venous systems, but lacks the dynamic information provided by spinal DSA and the capacity of 3D-DSA to offer subtracted images. FPCA therefore complements spinal DSA and 3D DSA in the spinal angiographic armamentarium. FPCA offers datasets with rich morphologic content, thanks to its superior spatial resolution and its relative immunity from patient motion artifacts, but accurate analysis of FPCA images requires concomitant evaluation of standard angiographic sequences documenting the dynamic characteristics of the acquisition, particularly in regard to the timing of the arterial and venous phases.

FPCA includes several features that enhance the accuracy

of spinal DSA. First, FPCA provides high-resolution images of the spinal vasculature, in particular, of the spinal veins, in any desired plane. Multiplanar reconstructions are particularly valuable in the field of spinal angiography, where lateral or even oblique projections are difficult to obtain, generally of poor quality, and generate higher radiation doses. Moreover, while motion and, particularly, breathing artifacts are very detrimental to image quality during spinal DSA, these have, in our experience, little or no influence upon the quality of the reconstructions provided by FPCA, even though the patients are allowed to breath normally throughout the rotational data acquisition. This is particularly true for the venous phase of spinal angiograms, which requires that patients hold their breath for as long as 15–20 seconds, a performance rarely achieved in the angiography suite. Similarly, bowel gas motion, which can result in pronounced angiographic image degradation, even when an antiperistaltic agent (eg, glucagon) is administered, has no significant impact on the image quality with FPCA. However, motion of the patient's body can result in loss of image quality. In our series, it happened in 3 instances, including 2 patients with severe uncontrollable leg spasms and 1 patient who moved her back during the rotational acquisition. In 2 of these cases, the reconstructions were found to be below diagnostic value. Finally, the greatest advantage of FPCA lies in its high-resolution depiction of small and complex vascular structures. While FPCA does sometimes better characterize the morphology of a structure detected by spinal DSA, in many instances, it offers a precise analysis of vessels not visualized on conventional angiographic images. In the first situation, the anatomic information provided by FPCA complements spinal DSA, for example, by helping the treatment planning for vascular malformations, as mentioned by Aadland and colleagues.<sup>6</sup> In the second situation, FPCA can transform a “negative study” into a positive angiographic diagnosis, eliminating the concern of an overlooked lesion and the need for additional angiographic sequences or further imaging studies. Our third case illustration exemplifies this role of FPCA. In this patient, MR imaging had raised the suspicion of a vascular malformation, while spinal DSA was unremarkable. By correlating the abnormalities documented by MR imaging with varicosities located along the dorsal surface of the spinal cord, FPCA was able to reinforce the diagnosis established by spinal DSA, that is, the absence of high-flow vascular malformation. At the same time, it remained unclear whether these abnormal veins lying on the dorsal aspect of the thoracic spinal cord might be at the origin of the midthoracic pain described by our patient. It appears that along with the improvement in spinal venous imaging brought by FPCA comes the need to evaluate the clinical significance of some of the anomalies identified by this new technique. We believe that FPCA has the potential to clarify poorly understood conditions involving the spinal venous system and possibly document venous disorders that are not yet appreciated.

Besides lacking dynamic information, FPCA presents the potential disadvantages of additional contrast volume and radiation dose. The first remains a minor concern, as the contrast agent is typically administered at a 25% dilution, with a maximum injected volume of contrast of 12.5 mL, in our experience. The second concern is more significant, as any dose of ionizing radiation is potentially harmful. Although FPCA



**Fig 3.** 58-year-old woman with a history of severe midscapular pain. *A*, MR imaging, sagittal T1-weighted images after gadolinium administration, showing prominent venous structures along the dorsal surface of the spinal cord between T8 and T12. A tangle of veins at the upper aspect of T10 was considered particularly suspicious for a vascular malformation (*arrow*). *B*, Spinal DSA, left T11 injection, anteroposterior view centered at T10/T11, arterial phase, documenting the artery of the lumbosacral enlargement (artery of Adamkiewicz). *C*, Spinal DSA, left T11 injection, anteroposterior view centered at T10/T11, venous phase. In this venous phase, the anterior spinal axis can be seen (*arrowheads*), without evidence of enlarged or abnormal veins. *D*, FPCA, left T11 injection, sagittal MIP, voxel size = 0.4, section thickness = 3.0, demonstrating the thoracolumbar perimedullary venous system, including the dorsal venous structures documented by MR imaging. *E*, FPCA, left T11 injection, coronal MIP, voxel size = 0.4, section thickness = 2.0. This coronal projection is an enlarged but otherwise unremarkable venous segment ending in a tangle of veins at the upper aspect of T10 (*arrow*), matching the suspicious structure seen by MR imaging (*A*, left). *F*, FPCA, left T10 injection, oblique MIP, voxel size = 0.1, section thickness = 1.0. This high-resolution reconstruction depicts the fine morphology of the right medullary vein exiting the dural sac at T10/T11. Note the narrowing of the vein as it pierces the dura (*arrow*) to join the internal vertebral venous plexus (epidural plexus; *arrowhead*).



doses are approximately 35% higher at the spinal level than at the cranial level, it is important to remember that spinal FPCA is obtained as part of an angiographic study spread over the whole length of the spine and spinal cord, and therefore represents less of a cumulative dose burden than at the cranial level, where all angiographic images are acquired in the same region. The comparison with regular angiographic sequences shows that a spinal FPCA corresponds approximately to 2–3 standard selective angiographic runs (at 2 frames per second) long enough to document the venous phase (or its absence; or approximately 4–5 standard runs performed at 1 frame per second). The dose associated with the latter depends upon the acquisition duration and the number of images acquired. Imaging the venous phase requires longer angiographic sequences and therefore is associated with higher than average radiation doses. In addition, it is not unusual during spinal DSA to have to repeat these longer sequences several times, often at different vertebral levels, to get an appreciation of the normal venous phase. When considering these factors, it appears that the burden of spinal FPCA upon the total dose of radiation might be less significant than anticipated, while its benefit, in terms of providing a meaningful evaluation of the spinal venous system, appears very substantial. The potential impact of the information provided by spinal FPCA therefore becomes an important consideration in regard to its role as a complement to spinal DSA. In our experience, FPCA provided clinically significant information in 65.1% of the cases (categories 2, 3, and 4). In 25.4%, FPCA allowed us to characterize anomalies that were not demonstrated by other imaging techniques, including spinal DSA. In these patients, it can be said that the findings provided by FPCA transformed negative spinal angiograms into positive studies, that is, studies offering a final angiographic diagnosis. In about half of the cases in which FPCA was categorized as not clinically significant (category 1), FPCA was able to document perimedullary venous structures not visualized by spinal DSA. Although venous imaging did not lead to the detection of a specific anomaly in these patients, it helped in ruling out pathologies of the venous system that would have otherwise been included in the differential diagnosis, such as venous thrombosis.

## Conclusions

During spinal DSA, angiographers are often reduced to trying to distinguish the opacification of some venous structures at the end of the angiographic sequence, and make diagnostic inferences based upon the timing of this opacification or its absence. While spinal FPCA does not offer such dynamic information, its rich and precise morphologic content allows characterization of venous anomalies that cannot be diag-

nosed by other means, such as spinal varices or other spinal venous anatomic anomalies. In this regard, FPCA brings to spinal angiography an equivalent to the venous phase routinely obtained during cerebral angiography. The clinical impact of the information offered by FPCA, some of which is not obtainable through any other current imaging technique, remains to be fully appreciated.

Disclosures: Tina Ehtiati—UNRELATED: Employment: Siemens Corporate Research, Comments: Currently employed as research scientist by Siemens Corporate Research. Philippe Gailloud—RELATED: Grant: Siemens Medical; \* Consulting Fee or Honorarium: Codman Neurovascular; UNRELATED: Consultancy: Codman Neurovascular; Stock/Stock Options: Artventive Medical, Comments: Co-owner, no money received.

## References

1. Launay M, Chiras J, Bories J. **Angiography of the spinal cord: venous phase. Normal features. Pathological application.** *J Neuroradiol* 1979;6:287–315
2. Chen J, Gailloud P. **Safety of spinal angiography: complication rate analysis in 302 diagnostic angiograms.** *Neurology* 2011;77:1235–40
3. van Rooij WJ, Sprengers ME, de Gast AN, et al. **3D rotational angiography: the new gold standard in the detection of additional intracranial aneurysms.** *AJNR Am J Neuroradiol* 2008;29:976–79
4. van Rooij WJ, Peluso JP, Sluzewski M, et al. **Additional value of 3D rotational angiography in angiographically negative aneurysmal subarachnoid hemorrhage: how negative is negative?** *AJNR Am J Neuroradiol* 2008;29:962–66
5. Prestigiacomo CJ, Niimi Y, Setton A, et al. **Three-dimensional rotational spinal angiography in the evaluation and treatment of vascular malformations.** *AJNR Am J Neuroradiol* 2003;24:1429–35
6. Aadland TD, Thielen KR, Kaufmann TJ, et al. **3D C-arm conebeam CT angiography as an adjunct in the precise anatomic characterization of spinal dural arteriovenous fistulas.** *AJNR Am J Neuroradiol* 2010;31:476–80
7. Merland JJ, Riche MC, Chiras J. **Intraspinal extramedullary arteriovenous fistulae draining into the medullary veins.** *J Neuroradiol* 1980;7:271–320
8. Kadyi H. *Über die Blutgefäße des Menschlichen Rückenmarkes.* Lemberg, Poland: Gubryonowisz & Schmidt; 1889
9. Tadié M, Hemet J, Freger P, et al. **Morphological and functional anatomy of spinal cord veins.** *J Neuroradiol* 1985;12:3–20
10. van der Kuip M, Hoogland PV, Groen RJ. **Human radicular veins: regulation of venous reflux in the absence of valves.** *Anat Rec* 1999;254:173–80
11. Liese GJ. **Angiotomography: a preliminary report.** *Radiology* 1960;75:272–75
12. du Boulay GH, Jackson DC. **Cranial angio-tomography.** *Clin Radiol* 1965;16:148–53
13. Fredzell G, Greitz T. **Apparatus for serial angiotomography.** *Brit J Radiol* 1966;39:811–16
14. Djindjian R, Faure C. **[Neuro-radiological investigations (arteriography and phlebography) in vascular malformations of the spinal cord].** [In French] *Rontgeneur Radiodiagn Clin Eur* 1963;158:171–95
15. Djindjian R, Houdart R, Hurth M. **Acquisitions récentes en angiographie médullaire.** *Revue Neurologique* 1966;115:1068–69
16. Zellerhoff M, Scholz B, Ruehrnschof E-P, et al. **Low contrast 3D reconstruction from C-arm data.** In: Flynn MJ, ed. *SPIE Medical Imaging 2005: Physics of Medical Imaging*, 2005:646–55
17. Akpek S, Brunner T, Benndorf G, et al. **Three-dimensional imaging and cone beam volume CT in C-arm angiography with flat panel detector.** *Diagn Interv Radiol* 2005;11:10–13
18. Heran NS, Song JK, Namba K, et al. **The utility of DynaCT in neuroendovascular procedures.** *AJNR Am J Neuroradiol* 2006;27:330–32
19. Nordon IM, Hincliffe RJ, Malkawi AH, et al. **Validation of DynaCT in the morphological assessment of abdominal aortic aneurysm for endovascular repair.** *J Endovasc Ther* 2010;17:183–89