

Are your **MRI contrast agents** cost-effective?

Learn more about generic **Gadolinium-Based Contrast Agents**.



AJNR

Sildenafil-Induced Cervical Spinal Cord Infarction

J.E. Walden and M. Castillo

AJNR Am J Neuroradiol 2012, 33 (3) E32-E33

doi: <https://doi.org/10.3174/ajnr.A2628>

<http://www.ajnr.org/content/33/3/E32>

This information is current as of April 20, 2024.

J.E. Walden
M. Castillo

SUMMARY: We present a patient with an acute cervical spinal cord infarction resulting from the use of sildenafil (Viagra) in combination with his hypertension medication. Symptoms were acute and rapidly progressive, and MR imaging with DWI was crucial in confirming the diagnosis.

ABBREVIATIONS: DWI = diffusion-weighted imaging; STIR = short tau inversion recovery

Cervical spinal cord infarction is rare due to the rich anastomotic networks between the vertebral and the posterior inferior cerebellar arteries in the upper cervical cord and the thyrocervical and costocervical branches of the subclavian arteries in the lower cervical cord.¹ Spinal cord infarction is caused by various etiologies, including atherosclerosis, vertebral artery occlusion or dissection, trauma, fibrocartilaginous embolism, cervical cord herniation, and surgery.² Aortic dissection and aortic aneurysm repair, arteriovenous malformation, cryptogenic transient ischemic attack, and cardiac arrest are also relatively frequent causes of cord infarction as well.³ We report a patient with a cervical spinal cord infarction after the concomitant administration of sildenafil citrate (Viagra) and hydrochlorothiazide.

Case Report

A 59-year-old man with a medical history significant for hypertension and hyperlipidemia presented to a local hospital due to weakness in his arms and an inability to move his legs. Three hours earlier, the patient had taken 50 mg of sildenafil along with hydrochlorothiazide (a component of his antihypertensive regimen) at the same time. Approximately 10 minutes later, while in the shower, the patient noticed right-shoulder weakness that rapidly spread to his left body. Soon after, he could no longer hold the soap in his hand. During the following hour, he could not move his legs, he began to feel dizzy, and his vision became blurry. The patient's wife called the paramedics when his symptoms did not improve. On arrival at a local hospital, he was found to have low systolic blood pressure of 80 mm Hg. A cervical/thoracic spine MR imaging performed approximately 7 hours after the onset of symptoms demonstrated high T2 signal intensity in the anterior spinal cord from C4 to C6.

The patient was transferred to our hospital. Repeat MR imaging of the cervical and thoracic spine with DWI, which was performed approximately 33 hours after symptom onset, again showed abnormal increased T2 and STIR signal intensity in the anterior spinal cord beginning at C4 and extending to T1. There was corresponding restricted diffusion in this region, and the findings were thought to be consistent with acute cord infarction (Fig 1). Additional studies included a CT angiography that showed no aortic dissection and normal cardiac telemetry. It was concluded that the spinal cord infarction was induced by hypotension due to coadministration of sildenafil and hydrochlorothiazide. Although the patient had taken sildenafil previ-

ously, he had not ever taken it with his antihypertensive medication. Two months after presentation and physical therapy, the patient was paraplegic and had recovered sensation and some strength in his upper extremities. Three months after presentation, the patient still had not regained lower extremity function, and required a motorized wheelchair.

Discussion

Infarction of the cervical spinal cord is exceptionally rare due to its rich anastomotic arterial network.⁴ In the upper cervical spine, blood cord supply is from the vertebral arteries and the posterior inferior cerebellar arteries. Below the upper cervical levels, the anterior and posterior spinal arteries become narrow in caliber and form an anastomotic network with radicular arteries. These radicular arteries arise from the subclavian artery via the ascending cervical branch of the thyrocervical trunk or via the deep cervical branch of the costocervical trunk.¹ This anastomotic network contributes to the vascularization of the lower cervical and upper thoracic cords.¹ The blood supply of the anterior spinal artery is at its most marginal in the upper thoracic region, T2-T4; thus, this watershed zone is vulnerable to hypotension.^{1,6} Additionally, the pattern of cervical radicular arteries suggests a minor watershed zone at C4.¹ The pattern of our patient's spinal cord infarct corresponded to these watershed zones, with his cord infarct spanning C4-T1.

After other etiologies were excluded as the source of our patient's cord infarct, we concluded that the cause was the combined simultaneous use of sildenafil citrate and hydrochlorothiazide. This drug combination likely led to systemic hypotension, resulting in cord infarction in the watershed zones of the cervical and upper thoracic cord. Reported cardiovascular side effects of sildenafil citrate are usually minor and associated with vasodilation, leading to small decreases in systolic and diastolic blood pressures.⁷ Sildenafil typically produces a transient 8- to 10-mm Hg reduction in systolic blood pressure and a 5- to 6-mm Hg reduction in diastolic blood pressure. This transient reduction in blood pressure generally returns to baseline 4 hours later. Sildenafil may be hazardous to patients on multidrug antihypertensive drug regimens. Although the significant risk of potentially life-threatening hypotension with coadministration of nitrates and sildenafil is well-known, to our knowledge, no formal drug-drug interaction studies have been conducted with sildenafil and hydrochlorothiazide. The effects of sildenafil may be augmented by hypotension caused by nitrates, drugs that inhibit its metabolism, and comorbidities that increase its levels such as kidney/liver diseases.⁸ Transient ischemic attacks, transient global amnesia, and ischemic optic neuritis have been reported to

Received December 1, 2010; accepted after revision January 15, 2011.

From the Department of Radiology, Division of Neuroradiology, University of North Carolina School of Medicine, Chapel Hill, North Carolina.

Please address correspondence to Janica E. Walden, MD, 7710 Morrell Ln, Durham, NC 27713; e-mail: janicawalden@hotmail.com

<http://dx.doi.org/10.3174/ajnr.A2628>

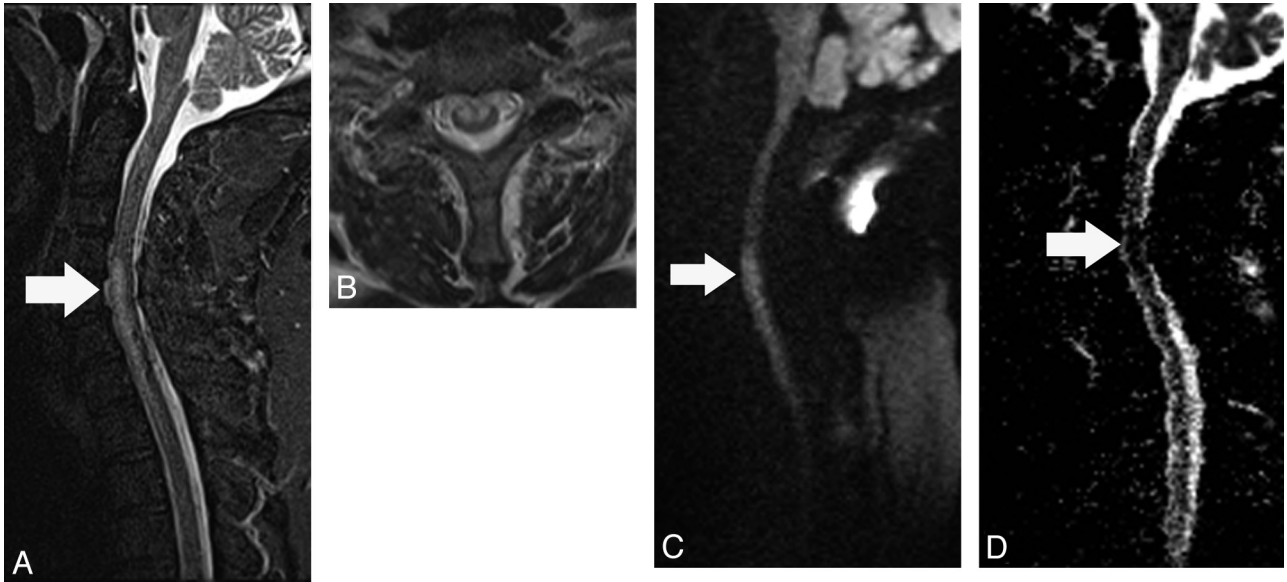


Fig 1. A, Midsagittal T2 STIR image shows high signal intensity (arrow) in the midcervical spinal cord predominantly in its anterior aspect. B, Axial T2-weighted image demonstrates that the high signal intensity abnormality predominantly involves the anterior gray matter horns. C, Midsagittal DWI shows high signal intensity (arrow) in the cord corresponding to the abnormality shown in A. D, Corresponding apparent diffusion coefficient map shows low signal intensity (restricted diffusion, arrow) in the same location.

occur after sildenafil use.⁹⁻¹² The addition of other drugs, such as hypoglycemic agents, to sildenafil may result in diffuse cerebral anoxia.¹³ Intracerebral and subarachnoid hemorrhages and seizures have been reported with sildenafil.⁸

In conclusion, the possibility that rarely sildenafil, particularly in combination with other drugs, may cause significant neurologic abnormalities, including spinal cord infarction, must be kept in mind.

References

- Howard RS, Thorpe J, Barker R, et al. Respiratory insufficiency due to high anterior cervical cord infarction. *J Neurol Neurosurg Psychiatry* 1998;64:358–61
- Ii Y, Maki T, Furuta T, et al. Cervical spinal cord infarction in a patient with cervical spondylosis triggered by straining during bowel movement. *J Clin Neurosci* 2009;16:106–07. Epub 2008 Nov 14
- Millichap JJ, Sy BT, Leacock RO. Spinal cord infarction with multiple etiologic factors. *J Gen Intern Med* 2007;22:151–54
- Kuker W, Weller M, Klose U, et al. Diffusion-weighted MRI of spinal cord infarction: high-resolution imaging and time course of diffusion abnormality. *J Neurol* 2004;251:818–24
- Lyders EM, Morris PP. A case of spinal cord infarction following lumbar transforaminal epidural steroid injection: MR imaging and angiographic findings. *AJNR Am J Neuroradiol* 2009;30:1691–93
- Weidauer S, Nichtweiss M, Lanfermann H. Spinal cord infarction: MR imaging and clinical features in 16 cases. *Neuroradiology* 2002;44:851–57
- Cheitlin MD, Hutter AM Jr, Brindis RG, et al. Use of sildenafil (Viagra) in patients with cardiovascular disease: Technology and Practice Executive Committee. *Circulation* 1999;99:168–77
- Farooq MU, Naravetla B, Moore PW, et al. Role of sildenafil in neurological disorders. *Clin Neuropharmacol* 2008;31:353–62
- Savitz SA, Caplan LR. Transient global amnesia after sildenafil (Viagra) use. *Neurology* 2002;59:778
- Egan RA, Pomeranz H. Transient ischemic attack and stroke associated with sildenafil (Viagra) use. *Neurology* 2002;59:293–94
- Egan R, Pomeranz H. Sildenafil (Viagra) associated anterior ischemic optic neuropathy. *Arch Ophthalmol* 2000;118:291–92
- Morgan JC, Alhatou M, Oberlies J, et al. Transient ischemic attack and stroke associated with sildenafil (Viagra) use. *Neurology* 2001;57:1730–31
- Lim CC, Gan R, Chan CL, et al. Severe hypoglycemia associated with an illegal sexual enhancement product adulterated with glibenclamide: MR imaging findings. *Radiology* 2009;250:193–201. Epub 2008 Nov 18