

Are your MRI contrast agents cost-effective?

Learn more about generic Gadolinium-Based Contrast Agents.



**FRESENIUS
KABI**

caring for life

AJNR

Comments on an Article by Ginat and Schatz

Y.J. Park and T.H. Park

AJNR Am J Neuroradiol 2012, 33 (9) E122-E123

doi: <https://doi.org/10.3174/ajnr.A3331>

<http://www.ajnr.org/content/33/9/E122>

This information is current as
of April 10, 2024.

Comments on an Article by Ginat and Schatz

We read with great interest the article by Ginat and Schatz entitled “Imaging Features of Midface Injectable Fillers and Associated Complications.”¹ The authors reviewed several midfacial foreign-body granulomas caused by injection with various medical fillers. They addressed an important area of investigation.

Soft-tissue filler injections have become very popular. Foreign-body granuloma is one of the delayed complications of filler injection that is challenging to treat and consequently results in an embarrassing appearance.² Considering the popularity of noninvasive filling procedures, we totally agree with the Ginat and Schatz that radiologists should be familiar with the imaging features of commonly used medical injectables and avoid confounding these with true pathology.¹

Above all, accurate diagnosis based on clinical suspicion is most important for definite treatment.³ In addition, due to cost-effectiveness, surgeons do not routinely perform imaging once a clinical diagnosis is obtained. Although an imaging study can help many clinicians to determine the injected materials, results of imaging do not affect the treatment approach whatever the materials are. We do not even perform pathologic studies in every case to identify the injected materials because they reveal only mild-to-moderate inflammatory reactions without providing definite information regarding the materials, while incurring additional cost to the patients.⁴

We would like to make several points: As a referral center for this entity in our country, we have treated >200 patients during 10 years (Fig 1). Although Ginat and Schatz showed several CT, MR imaging, and PET-CT examinations with patients injected with various fillers, we think radiologic findings can vary according to the patient's specific status—that is, radiologic findings according to various injected fillers that were presented by Ginat and Schatz cannot be applied in all cases. Thus, surgeons do not routinely perform radiologic examinations in all cases to determine the injected materials.

Ginat and Schatz suggested scarring as one of the late complications after filler injections. Although scarring can be a complication of all surgical procedures, none of the authors of medical literature reported that scar formation can be one of the complications of filler injections. Rather, as we hypothesized in our previous study, filler injection causes soft-tissue expansion and “creeping effect,” leading to less scar formation.²

Moreover, Ginat and Schatz argued that imaging can be helpful for delineating the extent of the excess material. However, plastic surgeons do not perform imaging studies to delineate the extent of overcorrection. Rather, some surgeons intentionally overcorrect the deformity to get higher patient satisfaction. In addition, acute complications such as initial signs of tissue necrosis, which are caused by excessive filler material injection, should be immediately reversed by using hyaluronidase injection or needle aspiration without hesitation. Surely, follow-up imaging can be of help to evaluate the success of the intervention.

In addition, Ginat and Schatz argued that chronic inflammation and lymphatic obstruction can lead to scar formation, referencing 2 previous articles.^{5,6} To our knowledge, previous studies by Rapaport et al⁵ and Mastruserio et al⁶ do not mention scar formation as a complication of the filling procedure at all. We also think that scar formation should be changed to “granuloma formation.”

Attempts to rejuvenate the aging hands have recently gained popularity; with development of dermal fillers, patients have various options.⁷ Recently, calcium hydroxyapatite (CaHA) fillers have been considered suitable for resurfacing the aging hand.^{8–13} In 2010, Bidic

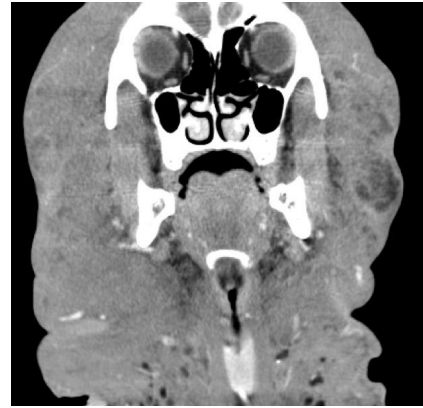

Fig 1. Diffuse subcutaneous soft tissue enlargement with a honeycomb appearance and increased vascularity in the entire head and neck, which were compatible with lymphedema due to foreign-body injection.

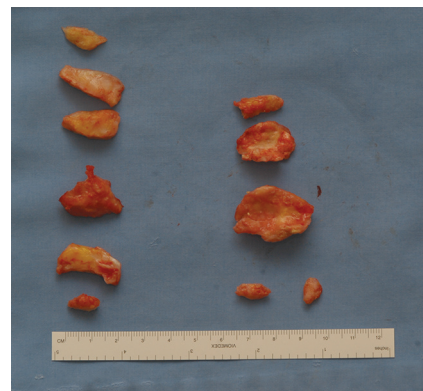


Fig 2. Gross specimen of a CaHA filler-related foreign body granuloma.

et al¹⁴ examined the anatomic superstructure of the dorsal hand soft tissues, which is relevant to hand rejuvenation, by using duplex sonography. According to our long-term follow-up, CaHA fillers occasionally result in hard palpable bonelike granulomas (Fig 2). According to previous studies, CaHA filler-related foreign-body granulomas cause increased FDG uptake in PET-CT imaging studies.^{15–17} The mechanism of increased FDG uptake is likely associated with glycolysis in cellular elements, which are recruited at the site of injection.¹⁵ The attenuation of CaHA filler-related foreign-body granulomas is less than that of either cortical or medullary bone.¹⁶ We believe that radiologic studies of complications of hand rejuvenation can also be of interest to many clinicians.

Overall, the present study by Ginat and Schatz focused on foreign-body granuloma and its radiologic findings. Radiologic study cannot detect most early and late complications except some extensive skin necrosis and foreign-body granulomas. However, to the best of our knowledge, the article by Ginat and Schatz is the first attempt to introduce the imaging features of injected filler materials. We believe this issue has merit for many plastic and dermatologic surgeons as well as radiologists, and further study with more patients should be performed to validate the present study.

References

1. Ginat DT, Schatz CJ. **Imaging features of midface injectable fillers and associated complications.** *AJNR Am J Neuroradiol* 2012 Jul 26. [Epub ahead of print]
2. Park TH, Seo SW, Kim JK, et al. **The efficacy of perilesional surgical approach for foreign body granuloma.** *Plast Reconstr Surg* 2011;127:121e–23e

3. Park TH, Seo SW, Kim JK, et al. **Clinical experience with polymethylmethacrylate microsphere filler complications.** *Aesthetic Plast Surg* 2012;36:421–26
4. Park TH, Seo SW, Kim JK, et al. **Clinical outcome in a series of 173 cases of foreign body granuloma: improved outcomes with a novel surgical technique.** *J Plast Reconstr Aesthet Surg* 2012;65:29–34
5. Rapaport MJ, Vinnik C, Zarem H. **Injectable silicone: cause of facial nodules, cellulitis, ulceration, and migration.** *Aesthetic Plast Surg* 1996;20:267–76
6. Mastruserio DN, Pesqueira MJ, Cobb MW. **Severe granulomatous reaction and facial ulceration occurring after subcutaneous silicone injection.** *J Am Acad Dermatol* 1996;34:849–52
7. Park TH, Yeo KK, Seo SW, et al. **Clinical experience with complications of hand rejuvenation.** *J Plast Reconstr Aesthet Surg* 2012 Jul 2. [Epub ahead of print]
8. Busso M, Applebaum D. **Hand augmentation with Radiesse (calcium hydroxylapatite).** *Dermatol Ther* 2007;20:385–87
9. Bank DE. **A novel approach to treatment of the aging hand with Radiesse.** *J Drugs Dermatol* 2009;8:1122–26
10. Edelson KL. **Hand recontouring with calcium hydroxylapatite (Radiesse).** *J Cosmet Dermatol* 2009;8:44–51
11. Marmur ES, Al Quran H, De Sa Earp AP, et al. **A five-patient satisfaction pilot study of calcium hydroxylapatite injection for treatment of aging hands.** *Dermatol Surg* 2009;35:1978–84
12. Gargasz SS, Carbone MC. **Hand rejuvenation using Radiesse.** *Plast Reconstr Surg* 2010;125:259e–60e
13. Sadick NS. **A 52-week study of safety and efficacy of calcium hydroxylapatite for rejuvenation of the aging hand.** *J Drugs Dermatol* 2011;10:47–51
14. Bidic SM, Hatef DA, Rohrich RJ. **Dorsal hand anatomy relevant to volumetric rejuvenation.** *Plast Reconstr Surg* 2010;126:163–68
15. Feeney JN, Fox JJ, Akhurst T. **Radiological impact of the use of calcium hydroxylapatite dermal fillers.** *Clin Radiol* 2009;64:897–902
16. Vazquez J, Rosenthal DI. **Bilateral, symmetrical soft tissue calcifications in the face.** *Skeletal Radiol* 2010;39:387–89
17. Carruthers A, Liebeskind M, Carruthers J, et al. **Radiographic and computed tomographic studies of calcium hydroxylapatite for treatment of HIV-associated facial lipoatrophy and correction of nasolabial folds.** *Dermatol Surg* 2008;34(suppl 1):S78–84

Y. J. Park

Department of Radiology

Kangnam Severance Hospital

Yonsei University School of Medicine

Seoul, Korea

T.H. Park

Department of Plastic and Reconstructive Surgery

Kangbuk Samsung Hospital

Sungkyunkwan University School of Medicine

Seoul, Korea

<http://dx.doi.org/10.3174/ajnr.A3331>