

Are your **MRI contrast agents** cost-effective?

Learn more about generic **Gadolinium-Based Contrast Agents**.



**FRESENIUS
KABI**
caring for life

AJNR

Ventriculitis in the neonate: recognition by sonography.

J D Reeder and R C Sanders

AJNR Am J Neuroradiol 1983, 4 (1) 37-41

<http://www.ajnr.org/content/4/1/37>

This information is current as of April 19, 2024.

Ventriculitis in the Neonate: Recognition by Sonography

John D. Reeder¹
Roger C. Sanders¹

In the neonate, ventriculitis and inflammatory infiltration of the choroid plexus usually accompany meningitis. Intracranial sonograms were reviewed from six infants referred for evaluation because of clinically suspected or confirmed ventriculitis. Findings included ventricular dilatation with irregularity of the ventricular margins and increased periventricular echogenicity. The choroid plexus margins also appeared poorly defined with loss of the normally smooth contour. Echogenic material was seen within the lateral ventricles, and intraventricular septa formation resulted in ventricular compartmentalization. Parenchymal changes included periventricular cavitation and a diffuse increase in cortical echogenicity. The ventricular pathology was more apparent on sonograms than on computed tomographic scans obtained at comparable times. In particular, sonography better demonstrated the ventricular compartmentalization from intraventricular septum formation. Identification of such partial ventricular isolation is especially important when treatment involves intraventricular shunt placement or the administration of intraventricular antibiotics. This experience suggests sonography should be the initial imaging method for evaluating ventriculitis and its complications in the newborn.

Despite a decline in mortality, neonatal meningitis remains a significant cause of neurologic impairment in childhood. Meningitis, when it occurs during early infancy, is fatal in 20%–30% of cases, and 30%–50% of the survivors develop neurologic sequelae [1]. The mortality and complications of this disease result, in part, from the ventriculitis that so often accompanies meningeal infection. In 75% of neonates with meningitis, ventriculitis is present at the time of diagnosis. In autopsy and neonatal primate studies, 100% have ventricular involvement [1, 2].

The ventricles and the choroid plexus may serve as a reservoir of infection, rendering intravenous antibiotics in standard dosages ineffective in treatment. The only clinical indication of ventriculitis may be a lack of a satisfactory response to conventional therapy, manifested by persistent fever, refractory seizures, or deteriorating mental status. The diagnosis of ventricular or choroid plexus involvement has important therapeutic and prognostic implications. Although the treatment of ventriculitis remains controversial, ventricular drainage and the instillation of intraventricular antibiotics has been advocated [3, 4].

In the past, when ventriculitis was suspected because of clinical deterioration, ventricular tap represented the only diagnostic method available. More recent reports have emphasized the use of computed tomography (CT) as a noninvasive means of identifying ependymal involvement or hydrocephalus. An abundance of literature has appeared demonstrating the excellent imaging capabilities of sonography in the diagnosis and follow-up of intracranial hemorrhage and its complications in the neonate. Few reports, however, have investigated the sonographic correlates of the pathologic changes evident in neonatal meningitis. In this report, we describe the sonographic findings in six infants and discuss the role of sonography in clinical management.

Received May 24, 1982; accepted after revision August 3, 1982.

¹ Department of Radiology and Radiological Sciences, Johns Hopkins Medical Institutions, Johns Hopkins Hospital, Baltimore, MD 21205. Address reprint requests to J. D. Reeder.

AJNR 4:37–41, January/February 1983
0195–6108/83/0401–0037 \$00.00
© American Roentgen Ray Society

Materials and Methods

Fourteen sonographic examinations were performed on six infants admitted to the Johns Hopkins Hospital with the diagnosis of meningitis. All scans were obtained with a real-time sector scanner equipped with a 5 MHz transducer (Advanced Technology Labs, Bellevue, WA). Ventricular involvement was confirmed by CT alone in two cases and by both CT and ventricular tap in four cases. CT was performed with and without intravenous contrast administration using a Pfizer/AS&E model 500 scanner.

Hospital records were reviewed to evaluate clinical presentation, hospital course, and neurologic outcome. Case 1 was seen at 12 days of age with fever, lethargy, and diarrhea. Group B *Streptococcus* grew from cultures of both blood and cerebrospinal fluid (CSF). After a 14 day course of intravenous antibiotics, the infant was afebrile and neurologically intact. However, 1 day after discharge, a respiratory arrest occurred. Cultures of the CSF again grew group B *Streptococcus*. Subsequently, the infant developed panhypopituitarism, seizures, and hypertonicity. Case 2 underwent closure of a L5-S1 meningomyelocele at day 1 of life. At 2½ months a rapidly increasing head circumference necessitated shunt replacement. At surgery, grossly purulent CSF (*Enterobacter cloacae*) was encountered. After 5 weeks of hospitalization, during which both intravenous and intraventricular antibiotics were administered, the infant was discharged with left hemiparesis, a seizure disorder, and developmental delay. Because subsequent medical therapy failed to arrest hydrocephalus, a ventriculoperitoneal shunt was placed at 6 months of life. Case 3 was seen at 5 weeks of life with fever and irritability. Group B *Streptococcus* grew from cultures of blood, CSF, and urine. After a 3 week hospitalization, the infant was discharged with right hemiparesis, seizures, and developmental delay. Case 4 was seen at 3½ months of life with fever and vomiting. *Pseudomonas aeruginosa* grew from both blood and CSF. Despite both intravenous and intraventricular antibiotics, eradication of the organism from the CSF proved extremely difficult. Hydrocephalus necessitated placement of a ventriculoperitoneal shunt. At discharge, after 6 weeks of hospitalization, the infant suffered from panhypopituitarism, seizures, and cranial nerve palsies. Case 5 was seen at 3 weeks of age with irritability and poor feeding. CSF specimens grew *Vibrio cholerae*; the infant's milk was thought to have been contaminated by infected crabs stored near an open container of formula. Despite intravenous antibiotics, the infant developed seizures and neurologic deterioration. Intraventricular antibiotic therapy resulted in gradual improvement, but, at 6 months of age, severe neurologic impairment remained evident. Case 6 experienced asphyxia at birth. At 12 days of life, inappropriate antidiuretic hormone secretion was noted and cultures from both blood and CSF grew *Klebsiella pneumoniae*. The infant's 3½ month hospitalization was complicated by resistance of the organism to antibiotics and by frequent seizures. At 6 months of age, the infant remained neurologically at the level of a newborn.

Results

In all six cases, sonography revealed marked irregularity of the ventricular walls and choroid plexus glomus and increased parenchymal echogenicity (table 1). In two cases, increased periventricular echogenicity was also revealed (figs. 1 and 2), and, in two cases, multiple periventricular cavities developed (fig. 3B).

Lateral ventricular dilatation occurred in all six infants. The third ventricle was enlarged in five patients and the fourth ventricle was enlarged in one. Low-level echogenic

TABLE 1: Sonographic Findings in Neonatal Ventriculitis

Organism: Case No.	Intraventricular		Periventricular	
	Exudate and/or Hemorrhage	Septation	Increased Echo- genicity	Cavitation
Group B <i>Streptococcus</i> :				
1	+	-	-	-
3	+	+	-	-
<i>Enterobacter cloacae</i> :				
2	+	+	-	+
<i>Pseudomonas aeruginosa</i> :				
4	+	-	+	-
<i>Vibrio cholerae</i> :				
5	+	+	-	+
<i>Klebsiella pneumoniae</i> :				
6	-	-	+	-

Note.—+ = finding present; - = finding absent. Ventricular dilatation, irregularity of ventricular walls and choroid plexus, and increased cortical echogenicity were present in all cases.

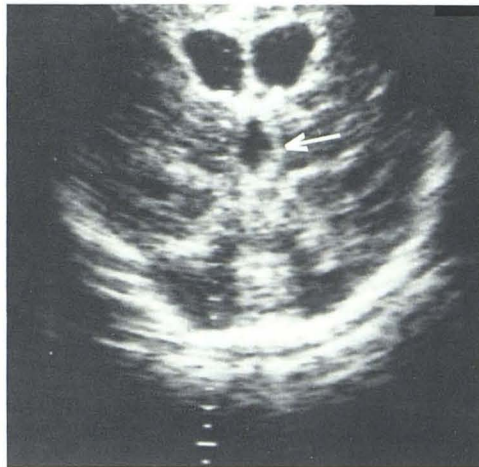
material was discovered within the ventricles of five infants (fig. 4). In three cases, intraventricular membranes also developed (figs. 3A and 4B). These septa appeared later in the course of the illness, being noted at least 3 weeks after the diagnosis of meningitis had been established. On follow-up clinical evaluation, all six infants evidenced neurologic and developmental impairment.

Discussion

The pathologic ventricular and parenchymal changes evident in neonatal meningitis vary with the duration of illness [5-7]. During the first 2 weeks of illness, focal segments of ependyma become denuded and hemorrhage into the ventricle may occur. An intraventricular exudate develops that encases and infiltrates the choroid plexus. Inflammatory cells also infiltrate the subependymal regions and subependymal edema ensues. Thrombophlebitis and arteritis occur and may result in patchy cortical infarctions. After 2 weeks, the ventricular exudate becomes organized and fibrous replacement occurs within the choroid plexus stroma. Glial tufts extend into the ventricular cavity through segments of disrupted ependyma. Hydrocephalus, often proportional in degree to the duration of illness, is frequently encountered [5]. Ventriculomegaly may result from obstruction of the foramina of Monro, the aqueduct of Sylvius, or the foramina of the fourth ventricle due to the accumulation of purulent exudate (acute) or from adjacent glial proliferation (chronic). Communicating hydrocephalus may develop with insufficient absorption from the subarachnoid space secondary to postinflammatory changes.

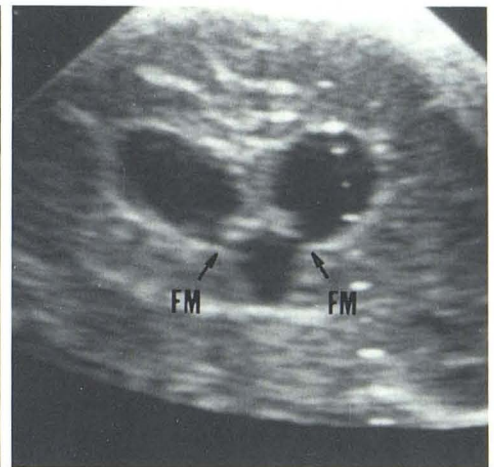
Sonographic correlates to these pathologic changes have been previously reported and include ventriculomegaly, intraventricular low-level echogenic material, and intraventricular membranes [8]. Widespread parenchymal cavitation has also been documented sonographically as a sequela to neonatal meningitis [9]. Our observations confirm these changes as consistent findings in ventriculitis. The cavitation that we observed may have been due to the development of multiple cerebral abscesses; however, considering the

Fig. 1.—Case 4. Coronal sonogram. Dilated third ventricle (*arrow*) and lateral ventricles (frontal horns). Increased periventricular echogenicity.



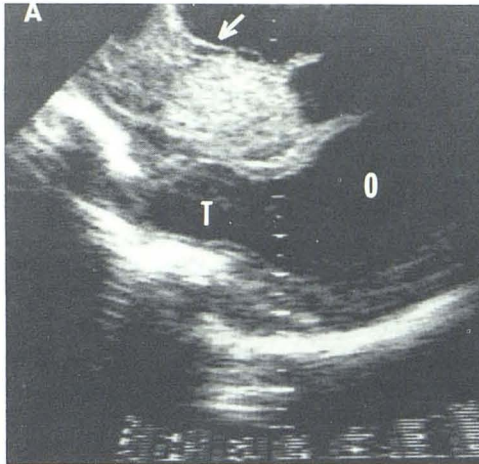
1

Fig. 2.—Case 6. Coronal sonogram through dilated lateral ventricular frontal horns, third ventricle, and foramina of Monro (FM). Increased periventricular echogenicity.

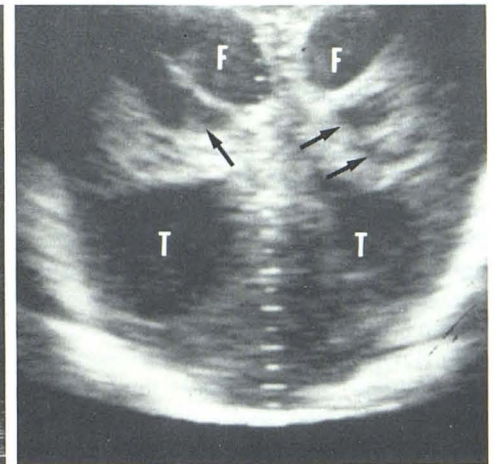


2

Fig. 3.—Case 5. A, Parasagittal sonogram through markedly dilated lateral ventricle. Thin intraventricular septation in frontal horn (*arrow*) and thicker posterior septations near choroid plexus glomus. Occipital horn (O). Temporal horn (T). A = anterior. B, Coronal sonogram. Markedly dilated frontal (F) and temporal (T) horns of lateral ventricles. Periventricular cavities (*arrows*) and diffuse increase in parenchymal echogenicity.

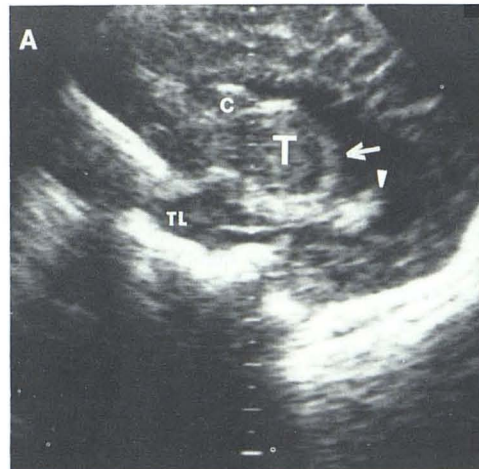


A

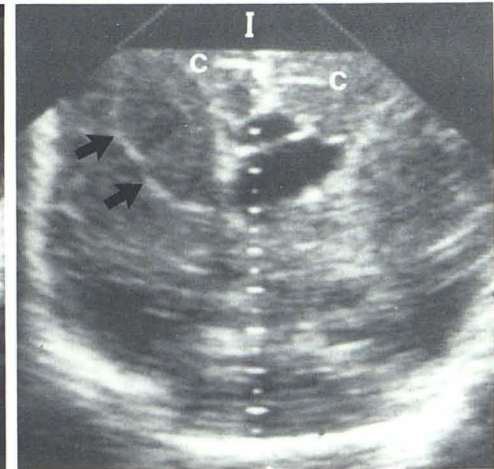


B

Fig. 4.—Case 2. A, Parasagittal scan through caudate nucleus (C), thalamus (T), temporal lobe (TL), and dilated lateral ventricle. Irregular margins of both glomus of choroid plexis (*arrow*) and walls of lateral ventricle. Echogenic material (*arrowhead*) in dilated occipital horn may be exudate or blood. A = anterior. B, Coronal scan through dilated frontal and temporal horns of lateral ventricles about 3 months after A. Moderately echogenic material, probably due to organizing exudate, almost fills right frontal horn (*arrows*). Ventricular compartmentalization of left frontal horn. Shift of midline to right relative to interhemispheric fissure (I) and cingulate sulci (C). Echogenicity of brain parenchyma diffusely increased.



A



B

marked vascular pathology encountered in neonatal meningitis, the cavities may also represent focal infarctions and resultant porencephaly.

Intraventricular septum formation may have particularly important therapeutic implications in that ventricular compartmentalization may develop. In patients who undergo surgical treatment of hydrocephalus, sequestration of ventricular components represents a cause of shunt failure [10, 11]. Compartmentalization may also complicate medical management of ventriculitis; if antibiotics are instilled directly into a sequestered part of the ventricular system, other foci of bacterial ependymitis may escape antibiotic exposure.

In addition to the previously described sonographic findings in meningitis, striking periventricular echogenicity and irregularity of the ventricular walls were discovered in our series. Increased subependymal echogenicity often becomes evident in neonatal intracranial hemorrhage and is thought to correspond either to inflammatory changes or possibly to dissecting subependymal hemorrhage [12]. In neonatal meningitis, increased ependymal echogenicity may also be due to periventricular calcification. Irregularity of the ventricular surface may correspond to the neuropathologic changes of ependymal interruption and interposed glial proliferation.

Choroid plexus irregularity also represented a consistent finding in our series. It is postulated that meningeal infection in the neonate may result from hematogenous spread to the choroid plexus. Since there is hemoconcentration and a high glycogen content in the choroid plexus, this structure represents an excellent culture medium for bacterial proliferation [13]. Because of poor antibiotic penetration, choroid plexitis may persist despite conventional intravenous therapy and the choroid plexus may act as a reservoir for recurrent infection. In our cases, choroidal irregularity remained evident even in the posttreatment phase of the disease, compatible with exudative organization and fibrous replacement within the choroid plexus stroma.

To our knowledge, the increased parenchymal echogenicity we observed has not been mentioned in prior reports. The echogenic foci may represent inflammatory cellular infiltrates during the acute illness. The persistent patchy cortical echogenicity evident in one of our patients 5 months after diagnosis may reflect collagen deposition similar to that observed in brain abscess healing [14]. These parenchymal findings, particularly the chronic foci of increased cortical echogenicity, await pathologic investigation.

All six of the infants studied sonographically also received CT assessment. The intraventricular pathology, notably septum formation, appeared considerably more distinct on sonograms than on CT scans at comparable times. Other authors have also found sonography superior to CT in demonstrating ventricular involvement in meningitis [8]. Furthermore, sonographic evaluation eliminates the risks attendant on contrast media administration, and bedside examination avoids transportation of a critically ill neonate. Because of the superior ventricular imaging capability and the practical limitations of CT in the neonate, we believe that sonography

is the preferred noninvasive diagnostic method in suspected neonatal ventriculitis.

Demonstration of ventriculitis and choroid plexitis maintains considerable importance in determining treatment. Although the administration of intraventricular antibiotics remains controversial, results do suggest that the risk is justifiable when ventricular involvement can be documented [3, 4]. Three of the six patients in our group received intraventricular aminoglycoside therapy. Ventricular drainage even without antibiotic instillation may be of value in clearing the ventricular exudate [13]. If, as some collaborative research suggests, intraventricular drug therapy is not beneficial, the recognition of ventricular involvement would at least demand longer courses of intravenous antibiotic therapy [1]. In addition to its therapeutic implication, the presence of ventriculitis would require more frequent and prolonged follow-up because of the possible development of surgically correctable hydrocephalus.

Ventriculitis represents a frequent complication of meningitis in infants, and it contributes significantly to the mortality and morbidity of the disease. Lumbar puncture is unreliable in demonstrating a ventricular reservoir of infection as ventricular cultures may remain positive despite sterile lumbar CSF samples. If the patient's clinical response to conventional antibiotic therapy appears inadequate, further evaluation is required. Sonography might well replace the ventricular tap as the initial diagnostic procedure. If, on the initial evaluation, ventricular involvement is evident, ventricular puncture may be indicated for identification of the responsible organism or for purposes of intraventricular therapy. If the ventricles initially appear normal, invasive diagnostic evaluation probably is not required. Because hydrocephalus represents such a frequent complication in neonatal meningitis, infants should receive serial sonographic examinations to permit, if necessary, prompt medical or surgical intervention.

REFERENCES

1. Avery GB. *Neonatology, pathophysiology and management of the newborn*. Philadelphia: Lippincott, 1981:735-736.
2. Daum RS, Scheifele DW, Syriopoulou VP, Averill D, Smith AL. Ventricular involvement in experimental hemophilus influenzae meningitis. *J Pediatr* 1978;93:927-930.
3. Salmon JH. Ventriculitis complicating meningitis. *Am J Dis Child* 1972;124:35-40.
4. Kaiser AB, McGee ZA. Aminoglycoside therapy of gram-negative bacillary meningitis. *N Engl J Med* 1975;293:1215-1220.
5. Berman PH, Bankes BQ. Neonatal meningitis: a clinical and pathological study of 29 cases. *Pediatrics* 1966;38:6-24.
6. Adams RD, Kubik CS, Bonner FJ. The clinical and pathological aspects of influenzal meningitis. *Arch Pediatr* 1948;65:354-376, 408-441.
7. Stoving J, Snyder RD. Computed tomography in childhood bacterial meningitis. *J Pediatr* 1980;96:820-823.
8. Hill A, Shackelford GD, Volpe JJ. Ventriculitis with neonatal bacterial meningitis: identification by real-time ultrasound. *J Pediatr* 1981;99:133-136.
9. Stannard MW, Suttersfield S. Cranial ultrasound in the management of infant meningitis. In: *Book of abstracts AIUM*. San

- Francisco: American Institute of Ultrasound in Medicine, 1981:202
10. Kalsbeck JE, DeSousa AL, Kleiman MB, Goodman JM, Franken EA. Compartmentalization of the cerebral ventricles as a sequela of neonatal meningitis. *J Neurosurg* 1980;52:547-552
 11. Savolaine ER, Gerber AM. Computed tomography studies of congenital and acquired cerebral intraventricular membranes. *J Neurosurg* 1981;54:388-391
 12. Fleischer AC, Hutchison AA, Allen JH, Stahlman MT, Meacham WF, James AE. The role of sonography and the radiologist-ultrasonologist in the detection and follow-up of intracranial hemorrhage in the preterm neonate. *Radiology* 1981;139:733-736
 13. Giles FH, James JL, Berenberg W. Neonatal meningitis. *Arch Neurol* 1977;34:560-562
 14. Enzmann DR, Britt RH, Lyons B, Carroll B, Wilson DA, Buxton J. High-resolution ultrasound evaluation of experimental brain abscess evolution: comparison with computed tomography and neuropathology. *Radiology* 1981;142:95-102