

Are your **MRI contrast agents** cost-effective?

Learn more about generic **Gadolinium-Based Contrast Agents**.



FRESENIUS
KABI

caring for life

AJNR

**Delayed effects in the treatment of
carotid-cavernous fistulas.**

F Y Tsai, G B Hieshima, C M Mehringer, V Grinnell and H W
Pribram

AJNR Am J Neuroradiol 1983, 4 (3) 357-361

<http://www.ajnr.org/content/4/3/357>

This information is current as
of April 17, 2024.

Delayed Effects in the Treatment of Carotid-Cavernous Fistulas

Fong Y. Tsai,¹ Grant B. Hieshima,² C. Mark Mehringer,² Verity Grinnell,² and Henry W. Pribram³

Carotid-cavernous fistulas may be classified into: (1) internal carotid, (2) external carotid, or (3) a combination of both. They may result from traumatic or spontaneous rupture of the carotid artery into the cavernous sinus. Intravascular embolization has become the treatment of choice for the management of carotid cavernous fistulas. The authors report the delayed effects after the treatment of carotid-cavernous fistulas with experience of 74 cases over the past 6 years. The delayed effects may be summarized as follows: (1) progressive spontaneous occlusion of the fistula after partial balloon embolization, (2) false aneurysms may decrease in size and be spontaneously sealed off, (3) transient and persistent third or sixth cranial nerve palsy may be seen in about 16% of 74 cases, (4) posttraumatic fibrosis with narrowing of the carotid artery may be apparent after total occlusion of the fistula, (5) a prematurely deflated balloon may be dislodged into the carotid artery or its branch, and (6) spontaneous obliteration of common channels from internal carotid artery may occur after total occlusion of external carotid channels in those cases with a combination of internal carotid- and external carotid-cavernous fistulas. Certainly the delayed effect will alter our future planning in the treatment of carotid cavernous fistulas.

Carotid-cavernous fistulas may occur as a result of a spontaneous rupture or traumatic laceration of the carotid artery into the cavernous sinus. Carotid-cavernous fistulas may be classified into three different types according to the site of the fistula: external carotid, internal carotid, or a combination of both [1-5].

Many therapeutic procedures have been developed including direct surgical or intravascular occlusive therapy [2-34]. The techniques of intravascular embolization have rapidly improved and it has become the treatment of choice for carotid-cavernous fistulas. The detachable balloon is for internal carotid fistula and particulate materials are for external carotid-cavernous fistula [3, 6-11, 13, 14, 17-21, 28-34]. Numerous reports have documented the successful embolization of carotid-cavernous fistulas, however, the long-term effects of the treated carotid-cavernous fistula have received very little attention [11].

Over the past 6 years we have learned several important delayed effects in relation to the treated carotid-cavernous fistula from experience with 74 cases. The delayed effects certainly affect our decision in the treatment of carotid-cavernous fistulas. We believe that the detail of these effects should be fully discussed in order to improve the results of the treatment.

Materials and Methods

In the past 6 years 93 cases of carotid-cavernous fistula have been treated in our hospitals. Those cases treated with a fixed balloon-tip catheter are excluded from this series. The 74 remaining cases are reviewed. (Most cases were from Harbor-UCLA Medical Center.) The 74 cases are subdivided as in table 1.

The materials that may be used for occlusive therapy include a variety of particulates, balloon-tip catheters, and liquid agents. However, we prefer to use the Silastic spheres and polyvinyl alcohol foam (Ivalon) particles for external carotid cavernous fistulas, and detachable balloons for internal carotid cavernous fistulas [3, 6-11, 13, 14, 17-21, 28-34].

Results and Discussion

The management of carotid-cavernous fistulas is often complicated. Many different methods have been reported in the treatment of the carotid cavernous fistulas [3, 6-11, 13, 14, 17-21, 28-34]. The spectrum of this report is not intended to cover the detail of each available procedure. Yet we are reporting the delayed effects from our experience with detachable balloons in the treatment of internal carotid-cavernous fistula and particulate material in the occlusion of external carotid-cavernous fistulas. The balloons in our series are inflated with slightly hypertonic metrizamide (earlier cases with other iodine contrast materials) and the miter valve of the balloon is autosealed after the balloon is detached from the delivery catheter. This mechanism allows the detached balloons to remain inflated over a long period of time [13, 14, 21]. The fistulas are usually totally obliterated with detached balloon(s) within the cavernous sinus and fistula. It may take one or more balloons to obliterate the fistula. Forty-three cases with internal carotid-cavernous fistula were completely obliterated with balloon(s) at the time of treatment. However, the cavernous sinus and fistula may not be completely occluded by the balloon(s). One may not be able to introduce a final balloon through the fistula because it is progressively partially occluded by multiple balloons, which decrease the shunt. On many occasions, the fistulas were partially obliterated, especially in those patients with large cavernous sinuses and fistulas. We have had 20 patients with partial occlusion of internal carotid-cavernous fistula. From our experience the partial balloon embolization will often result in total obliteration of fistula a few weeks or months later without further treatment (figs. 1-3). Only those patients with large fistulas and cavernous sinuses may require additional embolization to achieve complete occlusion of the fistula.

¹ Department of Radiological Sciences, University of California, Irvine Medical Center, 101 City Dr. S., Orange, CA 92668. Address reprint requests to F. Y. Tsai.

² Department of Radiology, Harbor UCLA Medical Center, Los Angeles, CA 90024.

³ Department of Radiology, Veterans Administration Hospital, Long Beach, CA 90822.

Only one recurrence of an internal carotid-cavernous fistula has been noted after total obliteration of the fistula. Therefore, we believe that total occlusion of the fistula may be postponed if there is difficulty with introducing additional balloons into a fistula. This may avoid the possible risks of prolonged catheter and balloon manipulation in the internal carotid artery or an improperly placed balloon.

The slightly hypertonic metrizamide and the autosealed miter valve may keep the balloon inflated over months or years to allow the fistula to be permanently thrombosed [13, 14, 21]. The deflated balloon is retained in the cavernous sinus after total occlusion of the fistula. Occasionally the balloon may spontaneously deflate prematurely and a false aneurysm may be formed at the site of the

fistula (fig. 3) [11]. A false aneurysm may also be formed in those patients with partial embolization with delayed occlusion of the fistula (fig. 1). We have seen 14 cases of false aneurysms; nine were due to premature deflation of balloon and five were secondary to partial embolization. We have not observed enlarging false aneurysms in our series. Those small or large false aneurysms usually diminish over a period of time without any further treatment. It may be sealed off spontaneously (fig. 1). Debrun et al. [11] reported 44% of 54 cases with false aneurysm. They recommended that additional balloons be placed to occlude the carotid artery and neck of the false aneurysms to relieve pain. We have not observed this problem in our series.

The deflated balloon is retained in the cavernous sinus if the fistula is totally occluded. However, we have seen two unfortunate patients with migration of deflated balloon to the internal carotid artery system. The migration of the deflated balloon is through the opening of a previously thrombosed fistula or false aneurysm (fig. 3). One of these two patients had a delayed stroke from migration of a partially inflated balloon. This is the only patient in our series with this delayed complication. The early deflation of the detached balloon may be due to the material defect or malfunction of the miter valve. Small defects may be difficult to recognize at the time of the procedure.

In addition to the internal carotid artery, the third, fourth, and sixth cranial nerves are coursing through the cavernous sinus. Cranial nerve injury may occur as a transient symptom and rarely

TABLE 1: Types of Carotid-Cavernous Fistulas in Patients Reviewed

Type of Carotid-Cavernous Fistula	No. Patients	
	Traumatic	Nontraumatic
Internal	58	5
External	5	3
Combination	2*	1

* Bilateral carotid-cavernous fistula.

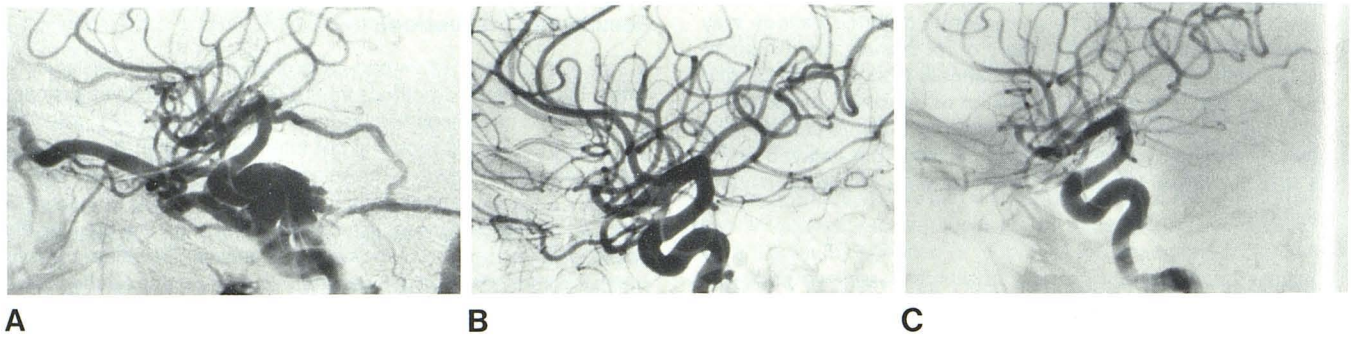


Fig. 1.—False aneurysm formation. A, Internal carotid-cavernous fistula seen with early opacification of cavernous sinus, petrosal sinus, superior ophthalmic vein, and sigmoid sinus. B, Several weeks later. Fistula almost completely obliterated with detachable balloon. Small false aneurysm at site of previous residual fistula. C, 1 month later. False aneurysm sealed off.

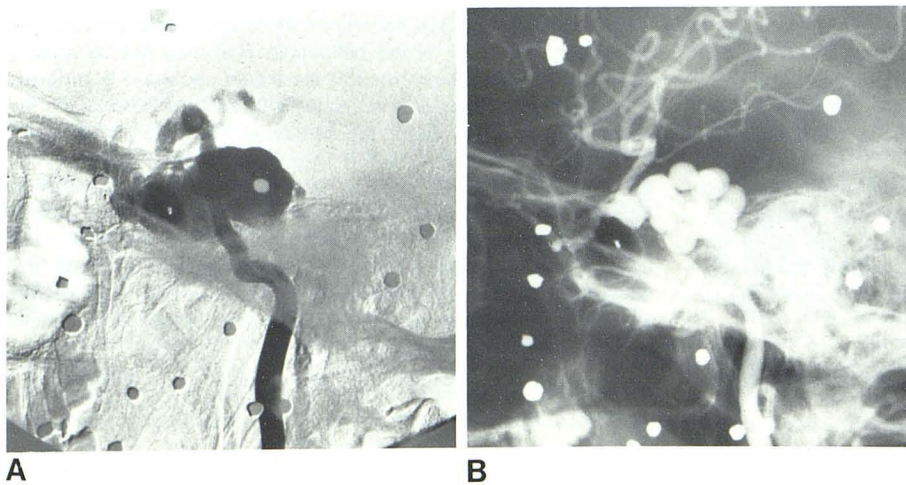


Fig. 2.—Total occlusion of fistula after partial embolization and traumatic fibrosis of carotid artery in patients with shotgun wounds 1 year before. A, Internal carotid-cavernous fistula seen with early opacification of cavernous sinus and superior ophthalmic vein. Intracranial vessels not well seen. Cavernous sinus is very big, probably due to long duration of untreated fistula. Fistula was partly treated with multiple balloons in posterior compartment. B, 2 months later without further treatment. Partial occlusion of fistula is totally obliterated. Long segmental narrowing of carotid artery from carotid canal to supraclinoid part.

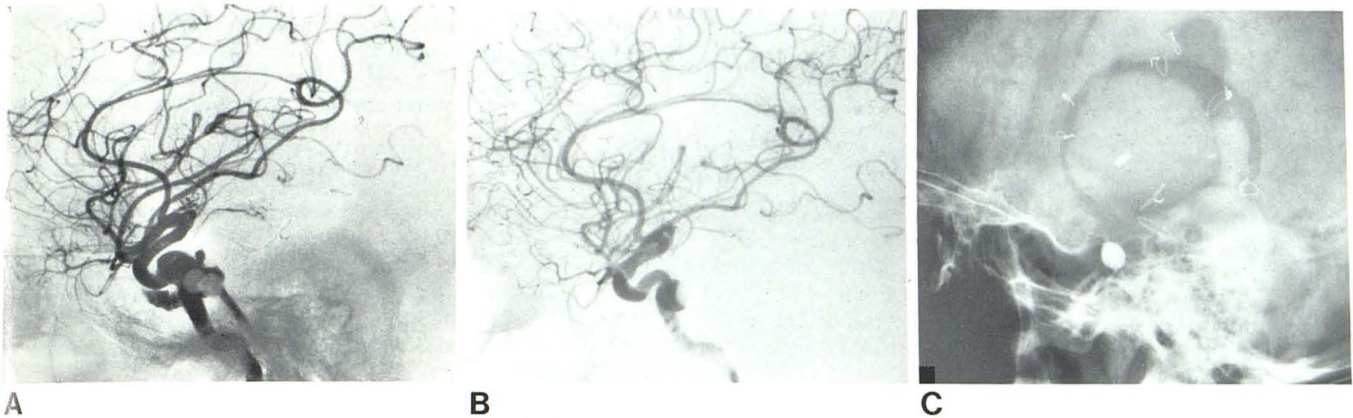


Fig. 3.—False aneurysm formation due to early deflation of balloon. **A**, After placement of second balloon. Only small residual fistula with minimal venous opacification. **B**, 4 months later. False aneurysm formed with partly deflated balloon. Another deflated balloon migrated to middle cerebral artery and occluded sylvian branch. **C**, Deflated migrated balloon is seen in sylvian branch.

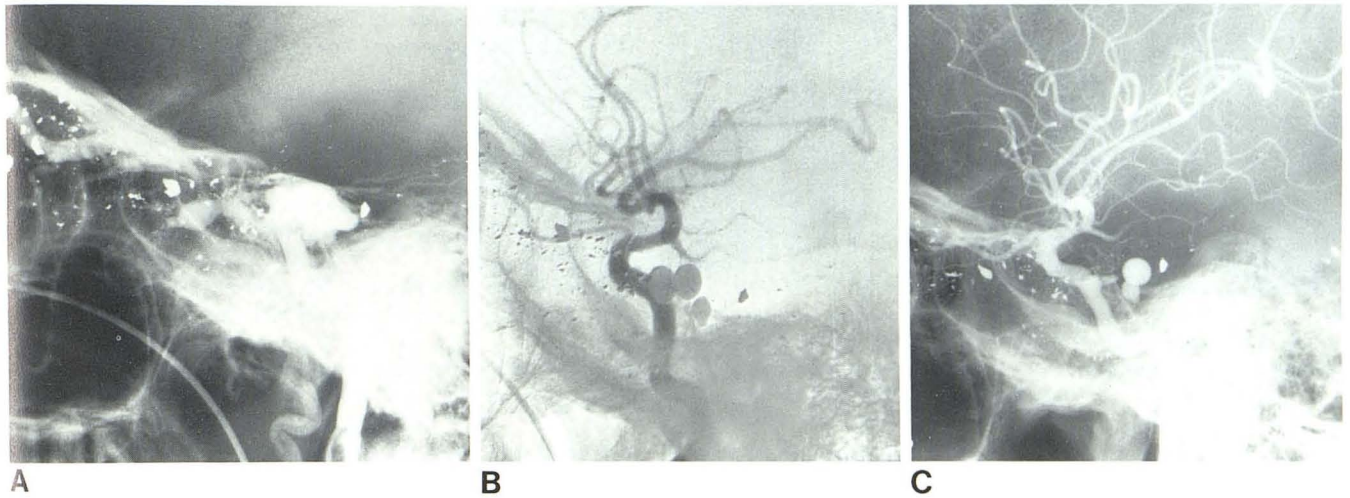


Fig. 4.—Delayed posttraumatic fibrosis after gunshot wound 2 months before. **A**, Internal carotid-cavernous fistula manifested by early opacification of cavernous sinus and superior ophthalmic vein. **B**, After placement of three detached balloons in cavernous sinus. Fistula is totally occluded. No evidence of carotid artery. **C**, 3 months later. Significant narrowing of supraclinoid and cavernous parts of internal carotid artery. Anterior cerebral artery is not opacified.

with persistent dysfunction. According to Debrun et al. [11] 20% of 54 cases had transient third and a larger proportion had sixth nerve palsies. We have seen 12 patients with transient third or sixth cranial nerve palsy. Five of 12 patients had cranial nerve palsies before the balloon embolization, and seven of these developed cranial nerve palsies after balloon embolization. Eight of these patients recovered within a few days to weeks. However, we have four patients who had persistent cranial nerve palsies for 3 months to 2 years. Two patients have a partial cranial nerve palsy, but one had a complete sixth cranial nerve palsy. One patient has had corrective eye surgery and is now asymptomatic.

The occurrence of carotid-cavernous fistula may or may not be associated with extensive injury to the wall of the carotid artery. Due to the existence of the fistula, traumatic fibrosis of the carotid artery may not be appreciated because the high-flow shunt prevents the injured carotid artery from narrowing. But the narrowing of the internal carotid artery may begin after occlusion of the fistula. We

have seen significant narrowing only in the five patients who suffered gunshot wounds. In figure 4, the carotid artery was normal after complete embolization of the fistula from the shotgun injuries. However, the cavernous and supraclinoid parts of the internal carotid artery became narrowed a month later. In figure 2, no significant narrowing of the proximal carotid artery was seen before embolization despite the narrowing of the segment of the carotid artery distal to the fistula. The whole segment of the internal carotid artery from the carotid canal to the supraclinoid portion was very narrowed. The carotid arterial flow was also compromised.

Complex injuries include a combination of external and internal carotid fistulas on the same side or bilaterally in the same patient. For bilateral internal carotid fistulas we usually treat the most symptomatic lesion first. In combined internal and external carotid-cavernous fistulas we will treat the external contributions before using internal carotid approaches. The fistula may close without subsequent internal carotid procedures (fig. 5). We have seen only

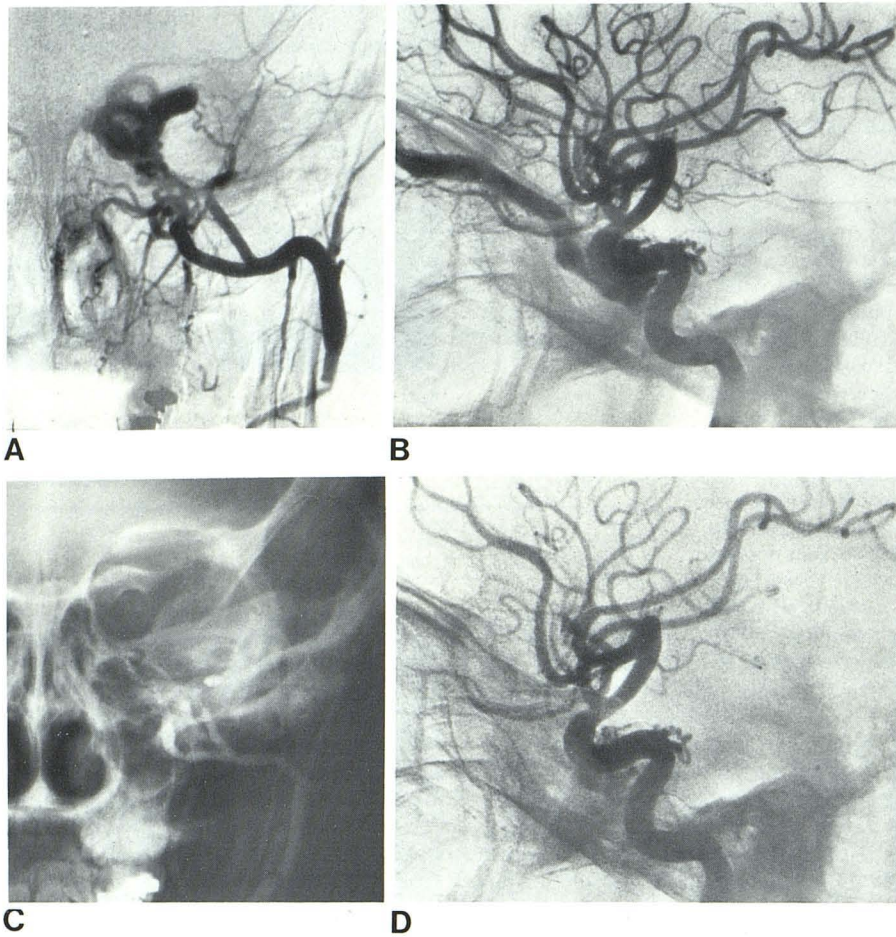


Fig. 5.—Spontaneous obliteration of common channels from internal carotid artery after total occlusion of external carotid-cavernous fistulas. **A** and **B**, Combination of external and internal carotid-cavernous fistulas seen with early opacification of cavernous sinus and big superior ophthalmic vein. Fistulas supplied from internal maxillary (**A**) and internal carotid (**B**) arteries. **C**, After second embolization with polyvinyl alcohol (Ivalon sponge) powder, fistula from external carotid artery was totally occluded. Few Silastic beads in region of cavernous sinus from first embolization. **D**, No fistula in internal carotid artery. There are a few small remaining channels adjacent to cavernous part of internal carotid artery.

one patient with spontaneous external carotid cavernous fistula with recurrence after initial Silastic sphere embolization. This may be due to reopening of the small channels, which were not appreciated on the initial angiogram and not obliterated with 1 mm Silastic spheres. Repeat embolization with smaller particulate polyvinyl alcohol (Ivalon sponge) powder did successfully occlude the fistula.

In summary, we have reported several delayed effects after the treatment of carotid-cavernous fistulas. Partial embolization of an internal carotid-cavernous fistula will often progress to total occlusion of the fistula.

Early deflation of the detached balloon may result in the formation of a false aneurysm or migration of a balloon. The false aneurysms in our series have been stable or decreasing in size. Transient cranial nerve palsy may be seen before or after embolization, but a small percentage of the patients may have persistent dysfunction of third and sixth cranial nerves.

Posttraumatic fibrosis may be more evident after total occlusion of the fistula. Spontaneous external carotid-cavernous fistulas may recur and require repeated embolization.

REFERENCES

1. Ambler MB, Moon AC, Sturmer WQ. Bilateral carotid cavernous fistulae of mixed types with unusual radiological and neuropathological findings. *J Neurosurg* 1978;48:117-124
2. Donnell MS, Larson SJ, Correa-Paz P, Worman LW. Traumatic bilateral carotid cavernous sinus fistulas with progressive unilateral enlargement. *Surg Neurol* 1978;10:115-118
3. Hardy RW, Costin JA, Weinstein M, Berlin AJ, Gutman FA. External carotid cavernous fistula treated by transfemoral embolization. *Surg Neurol* 1978;9:255-256
4. Mehringer CM, Hieshima GB, Grinnell VS, Tsai FY, Pribram HFW. Improved localization of carotid cavernous fistula during angiography. *AJNR* 1982;3:82-84
5. Newton TH, Hoyt WF. Dural arteriovenous shunts in the region of the cavernous sinus. *Neuroradiology* 1970;1:71-81
6. Bakuleyan K, Nelson LR, Peck FC Jr. Occlusion of carotid cavernous fistula with a balloon catheter. *Surg Neurol* 1975;3:283-287
7. Black P, Uematsu S, Perovic M, Walker AE. Carotid cavernous fistula: a controlled embolus technique for occlusion of fistula with preservation of carotid blood flow: technical note. *J Neurosurg* 1973;38:113-118
8. Debrun G, Lacour P, Caron JP, et al. Experimental approach to the treatment of carotid cavernous fistula with an inflatable and isolated balloon. *Neuroradiology* 1975;9:9-12
9. Debrun G, Lacour P, Caron JP, et al. Inflatable and released balloon technique: experimentation in dog—application in man. *Neuroradiology* 1975;9:267-271
10. Debrun G, Lacour P, Caron JP, Hurth M, et al. Detachable

- balloon and calibrated-leak balloon techniques in the treatment of cerebral vascular lesions. *J Neurosurg* **1978**;49:635-649
11. Debrun G, Lacour P, Vinuela F, Fox A, Drake CG, Caron JP. Treatment of 54 traumatic carotid cavernous fistulas. *J Neurosurg* **1981**;55:678-692
 12. Guegan Y, Javalet A, Eon JY, Vallee B, Pecker J. Extra-intracranial anastomosis preliminary to treatment of carotid artery cavernous sinus fistula. *Surg Neurol* **1978**;10:85-88
 13. Hieshima GB, Mehringer CM, Grinnell VS, Hasso AN, Siegel NH, Pribram HF. Emergency occlusive techniques. *Surg Neurol* **1978**;9:293-302
 14. Hieshima GB, Grinnell VS, Mehringer CM. A detachable balloon for therapeutic transcatheter occlusions. *Radiology* **1981**;138:227-228
 15. Hoffman JC, Cox GW, Fleischner AS. Interventional neuroradiology: a joint effort of the neuroradiologist and neurosurgeon in the treatment of vascular lesions of the head and neck. *Surg Neurol* **1978**;10:247-253
 16. Hosobuchi Y. Electrothrombosis of carotid cavernous fistula. *J Neurosurg* **1975**;42:76-85
 17. Ishimori S, Hattori M, Shibata Y, Shizawa H, Fujinaga R. Treatment of carotid cavernous fistula by Gelfoam embolization. *J Neurosurg* **1967**;27:315-319
 18. Kerber CW, Bank WO, Cromwell LD. Cyanoacrylate occlusion of carotid cavernous fistula with preservation of carotid artery flow. *Neurosurg* **1979**;4:210-215.
 19. Laws ER, Onofrio BM, Pearson BW, McDonald TJ, Dinemberger RA. Successful management of bilateral carotid cavernous fistulae with a transfemoral approach. *Neurosurg* **1979**;4:162-167
 20. Markham JW. Carotid cavernous sinus fistula treated by intravascular occlusion with a balloon catheter. *J Neurosurg* **1974**;40:535-538
 21. Mehringer CM, Hieshima GB, Grinnell VS, et al. Therapeutic embolization for vascular trauma of the head and neck. *AJNR* **1983**;4:137-142
 22. Morley TP. The treatment of carotid cavernous fistula introduction. In: Morley TP, ed. *Current controversies in neurosurgery*. Philadelphia: Saunders, **1976**:219-222
 23. Morley TP. The treatment of carotid cavernous fistula: introduction and appraisal of various forms of management in 41 cases of carotid cavernous fistula. In: Morley TP, ed. *Current controversies in neurosurgery*. Philadelphia: Saunders, **1976**:219-236
 24. Mullan S. Treatment of carotid cavernous fistulas by cavernous sinus occlusion. *J Neurosurg* **1979**;50:131-144
 25. Parkinson D. Carotid cavernous fistula: direct approach with repair of fistula and preservation of the artery. In: Morley TP, ed. *Current controversies in neurosurgery*. Philadelphia: Saunders, **1976**:237-249
 26. Parkinson D. Carotid cavernous fistula: direct repair with preservation of the carotid artery. Technical Note. *J Neurosurg* **1973**;38:99-106
 27. Parkinson D. A surgical approach to the cavernous portion of the carotid artery: anatomical studies and case report. *J Neurosurg* **1965**;23:474-483
 28. Picard L, Lepoivre J, Montant J, et al. Endarterial occlusion of carotid cavernous sinus fistulas using a balloon tip catheter. *Neuroradiology* **1974**;8:540
 29. Prolo DJ, Burres KP, Hanbery JW. Balloon occlusion of carotid cavernous fistula: introduction of a new catheter. *Surg Neurol* **1977**;7:209-214
 30. Prolo DJ, Hanbery JW. Treatment of carotid cavernous fistula with catheter and balloon. In: Morley TP, ed. *Current controversies in neurosurgery*. Philadelphia: Saunders, **1976**:250-254
 31. Samson D, Dittmore M, Berger CW. Intravascular use of isobutyl 2-cyanoacrylate. Part 2. Treatment of carotid cavernous fistulas.
 32. Sedzimir CB, Occleshaw JV. Treatment of carotid cavernous fistula by muscle embolization. *J Neurosurg* **1967**;27:309-314
 33. Serbinenko FA. Balloon catheterization and occlusion of major cerebral vessels. *J Neurosurg* **1974**;41:125-145
 34. Serbinenko FA. Balloon occlusion of cavernous portion of the carotid artery as a method of treating carotid cavernous fistulae. *Zh Vopr Neurokhr* **1971**;6:3-9