AJNR

Cerebrovascular occlusion by catheterization and embolization: clinical experience.

M Negoro, N Kageyama and T Ishiguchi

AJNR Am J Neuroradiol 1983, 4 (3) 362-365
http://www.ajnr.org/content/4/3/362

Cerebrovascular Occlusion by Catheterization and Embolization: Clinical Experience

Makoto Negoro,[1] Naoki Kageyama,[2] and Tsuneo Ishiguchi[1]

Intravascular occlusion by various catheterization techniques was used to treat 27 cases of carotid-cavernous fistula, giant intracavernous aneurysm, and cerebral or dural arteriovenous malformation. Several case reports are presented. The detachable balloon technique proved valuable in the treatment of traumatic carotid-cavernous fistula and giant aneurysm. Calibrated-leak balloon catheterization with fluid embolization was used to treat cerebral arteriovenous malformation. Selection of embolic material is discussed.

The recent evolution of intravascular catheterization techniques has brought significant changes in the treatment of various intracranial and extracranial disorders, especially cerebrovascular disease. In 1974, Serbinenko [1] published the first report about the detachable balloon technique. In the years that followed, the French school reported their extensive research on therapeutic embolization. Various types of balloon catheters have been developed by several investigators in North America [2]. Thanks to these new devices and techniques, it is now possible to perform catheterization far more distally than before.

Subjects and Methods

Since 1981 we have used intravascular occlusion by catheterization to treat 19 patients with carotid-cavernous fistula, four cases of giant intracavernous aneurysm, and four cases of cerebral or dural arteriovenous malformation (AVM). Various types of catheters and emboli were used. Conventional angiographic catheters were used for the external carotid artery manipulations in treating dural carotid-cavernous fistula and AVM. Detachable balloon catheters were chosen for the treatment of traumatic carotid-cavernous fistula, using techniques almost identical to those described by Debrun et al. [3]: The balloon is introduced by transcarotid catheterization, inflated with metrizamide (concentration, 240 mg I/ml), and de-

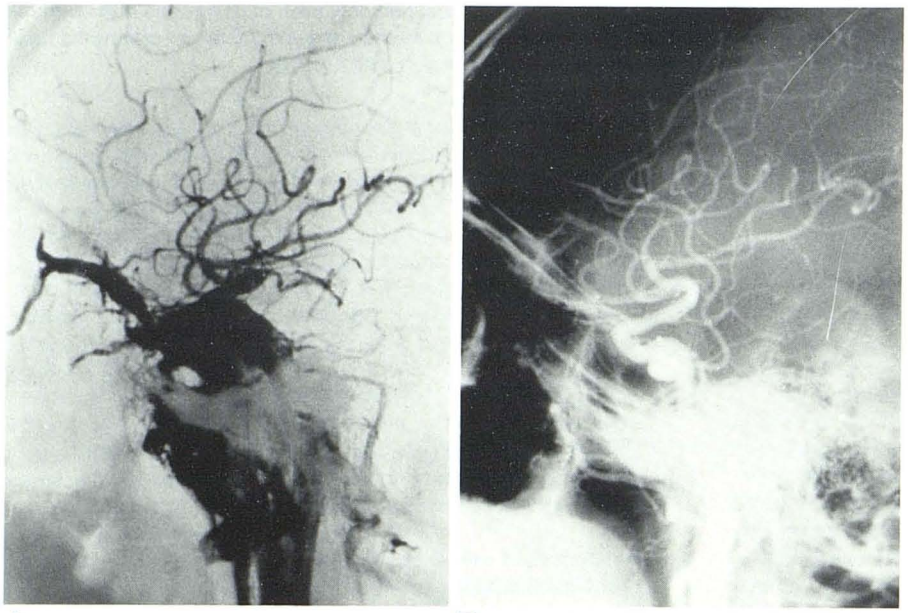

A B

Fig. 1.—Traumatic carotid-cavernous fistula. **A**, Left internal carotid angiogram before treatment. Drainage to superior and inferior ophthalmic veins and pterygoid plexus. **B**, After fistula occlusion. Balloon is detached and venous drainage is absent.

[1] Department of Neurosurgery, Nagoya University School of Medicine, 65 Tsuruma-cho, Showa-ku, Nagoya 466, Japan. Address reprint requests to M. Negoro.
[2] Department of Radiology, Nagoya University School of Medicine, Nagoya 466, Japan.

AJNR **4:362–365, May/June 1983** 0195–6108/83/0403–0362 $00.00

TABLE 1: **Traumatic Carotid-Cavernous Fistula: Summary of Cases**

Case No. (age, gender)	Site of Fistula	Clinical Features on Admission					Duration of Symptoms (months)	Treatment		Time Elapsed after Treatment (months)	Clinical Features after Treatment				
		Bruit	Proptosis	Chemosis	3rd Nerve Involvement	6th Nerve Involvement		CCF Occluded	ICA Preserved		Bruit	Proptosis	Chemosis	3rd Nerve Involvement	6th Nerve Involvement
1 (18, M)	L	+++	+++	+++	+	+	4	T	–	20	I	I	I	I	I
2 (62, F)*	L	+	+	–	–	+	6	P	+	5	U	I	–	–	I(R)
								T	+	16	I	I	I	I	I(L)
3 (50, F)	R	+	+	–	–	+	5	T	+	16	I	I	–	–	I
4 (52, F)	L	+	+	–	+	+	4	P	+	13	I	I	–	U	I
5 (49, M)	L	+	+	–	+	+	14	F	+	13	U	–	–	U	U
6 (27, M)	L	+	+	–	+	+	1	T	+	9	I	I	–	–	I
7 (60, F)	L	+	++	++	+	+	1	T	+	9	I	I	I	I	I
8 (58, F)	L	++	+	+	+	+	4	T	–	2	I	I	I	I	I
9 (64, F)	L	++	–	–	+	+	3	P	+	1	I	U	–	U	U

Note.—L = left hemisphere; R = right hemisphere; + = present (++, +++ = increasing degrees of severity); – = absent; CCF = carotid-cavernous fistula; T = total occlusion; P = partial occlusion; F = failure; ICA = internal carotid artery; I = improved; U = unchanged.

* This patient was treated twice.

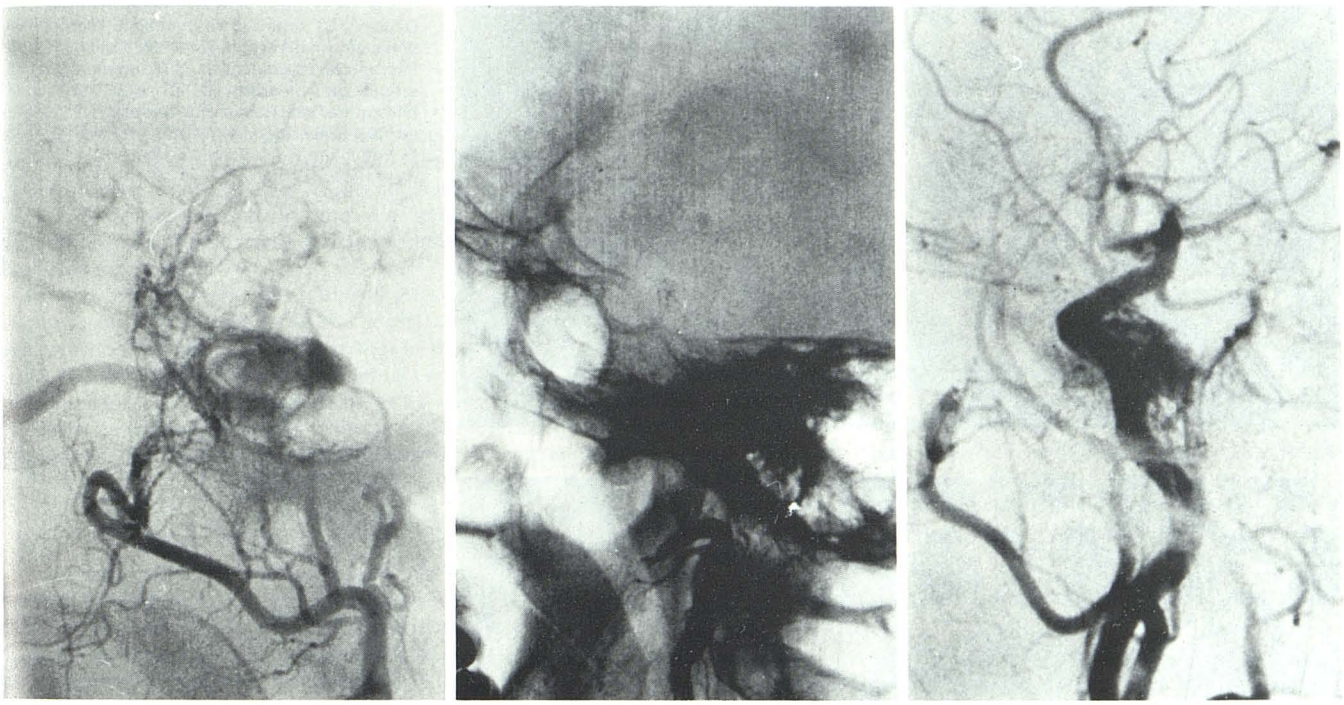

A B C

Fig. 2.—Dural carotid-cavernous fistula. **A**, Left external carotid angiogram before treatment. Drainage to superior ophthalmic and superficial cortical veins. **B**, After transfemoral catheterization and embolization. Occlusion of fistula. **C**, Cerebral angiogram 2 months later. Recurrence of fistula

tached without hardening materials. Calibrated-leak balloon catheters were used for the treatment of cerebral AVM. This type of catheter was designed by Kerber [4], who describes the technique. Once the catheter enters the feeding artery by the transfemoral approach, a fluid embolus is injected.

The material for the embolus was carefully chosen to suit the purpose of the embolization [5]. Gelfoam or Ivalon sponge was used for embolization of the external carotid artery. Cyanoacrylate was chosen for the fluid embolus.

Before permanent occlusion of the internal carotid artery, intravascular occlusion tests were performed by interrupting the carotid flow while monitoring the patient's neurologic signs and electroencephalographic (EEG) readings.

Representative Case Reports

Traumatic Carotid-Cavernous Fistula

A 26-year-old man had suffered a minor head injury. Immediately after the injury the patient had vomited several times and noted a pulsatile intracranial sound. Physical examination on hospital admission revealed episcleral and conjunctival injection with moderate

TABLE 2: **Dural Carotid-Cavernous Fistula: Summary of Cases**

Case No. (age, gender)	Duration of Symptoms	Clinical Features on Admission				Afferent Supply	Treatment	Time Elapsed after Treatment	Outcome
		Injected Eye	Proptosis	6th Nerve Involvement	Bruit				
1 (63, F)	1.5 yr	++ (B)	±	±	+	B ECA + ICA	B E (S)	2.5 yr	M
2 (69, F)	2 mo	+ (L)	−	+	+	L ECA	L E (S) + ligation	2 yr	M
3 (54, M)	8 mo	+ (R)	+ (R)	+ (R)	−	B ECA	B E (S)	2 yr	R
4 (33, M)	3 mo	+ (R)	+ (R)	+ (R)	−	B ECA + ICA	R E (S)	2 yr	M
5 (44, F)	4 mo	++ (L)	+ (L)	+ (L)	+	B ECA + ICA	L E (S)	1.5 yr	R
6 (56, M)	4 yr	++ (L)	−	+ (L)	−	B ECA	B E (S)	1.5 yr	R
7 (53, F)	2 yr	++ (B)	++ (R)	+ (R)	+	B ECA	B E (S + I)	1 yr	R
8 (57, F)	7 mo	+	+	+	−	B ECA + ICA	R E (S + I)	1 yr	M
9 (53, M)	9 mo	++	+	+	+	B ECA	B E (S + I)	4 mo	M
10 (43, M)	6 mo	++	+	+	−	B ICA	None	4 mo	M

Note.—Yr = year(s); mo = months; + = present (++ = feature pronounced); ± = intermittent; − = absent; B = bilateral; L = left; R = right; ECA = external carotid artery; ICA = internal carotid artery; E = embolization; S = Spongstan; I = Ivalon; M = moderate to successful; R = recurrence of fistula.

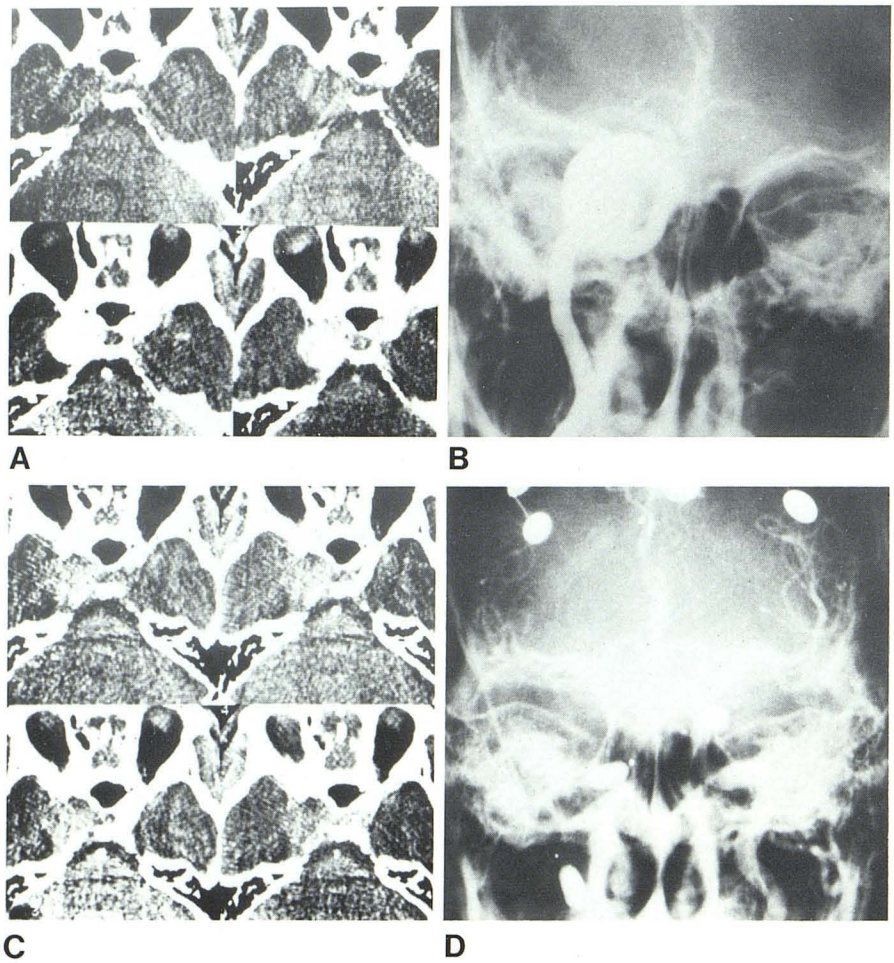

Fig. 3.—Giant intracavernous aneurysm. **A**, Dynamic CT scan before treatment. High-density enhancing mass in right parasellar region. **B**, Right internal carotid angiogram. Huge aneurysm in cavernous part of artery. **C**, CT after transcarotid balloon catheterization and occlusion of right internal carotid artery. Only faint rim around mass. **D**, Left internal carotid angiogram. Good left-right cross-flow. (Disks are EEG electrodes for intravascular occlusion test.)

proptosis on the left. A bruit was heard over both eyes. Cerebral angiography demonstrated a left carotid-cavernous fistula with drainage to the superior and inferior ophthalmic veins and to the pterygoid venous plexus (fig. 1A).

A 7 French introducer sheath was inserted in the left common carotid artery by percutaneous placement. The guiding catheter was selectively introduced into the left internal carotid artery. Through it, the detachable balloon catheter was carefully guided to

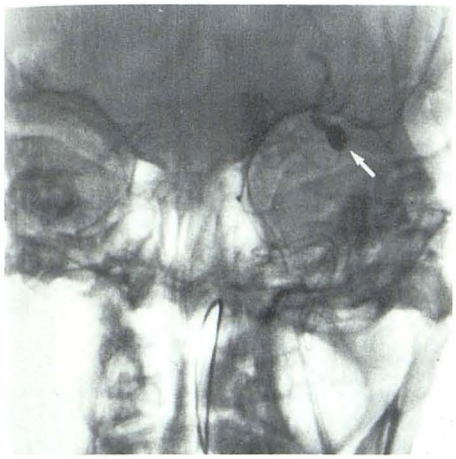

Fig. 4.—Severe cerebral AVM in region of basal ganglia. Small calibrated-leak balloon catheter is inserted into one of feeding arteries before fluid embolization. (*Arrow* indicates balloon.)

the site of the fistula. After confirmation of occlusion of the fistula, the balloon was filled with metrizamide and detached (fig. 1B). During procedures the orbital bruit was constantly monitored. Once the fistula was occluded, the bruit could no longer be detected. The patient's postoperative course was uneventful and symptoms disappeared within 1 month.

Eight of nine patients with traumatic carotid-cavernous fistula were successfully treated (table 1). Internal carotid artery patency was preserved in six successful cases. In the one unsuccessful case, neither fistula occlusion nor internal carotid artery occlusion was accomplished because of the patient's intolerance to carotid occlusion and the difficulty of balloon navigation. Two patients experienced transient hemiparesis with subsequent full recovery.

Dural Carotid-Cavernous Fistula

A 44-year-old woman had a 5-month history of proptosis and episcleral injection of the left eye. On examination, a bruit was detected over the left eye and a left sixth-nerve palsy was present. External carotid angiography demonstrated a dural carotid-cavernous fistula that drained into the superior ophthalmic and superficial cortical veins (fig. 2A).

Transfemoral catheterization was performed in the left external carotid artery. Multiple fragments of gelatin sponge were injected until complete occlusion of the fistula occurred (fig. 2B). Postoperatively the patient complained of moderate jaw pain, but her symptoms disappeared within 2 weeks. Two months later, she began experiencing mild episcleral injection of both eyes. Cerebral angiography confirmed the recurrence of dural carotid-cavernous fistula (fig. 2C).

Nine of 10 patients with dural carotid-cavernous fistula were treated by external carotid artery embolization (table 2). Four patients had definite recurrence of the fistula. However, their symptoms remained very mild.

Giant Intracavernous Aneurysm

A 26-year-old man complained of double vision. On admission, the patient had right sixth-nerve palsy. Computed tomography (CT) demonstrated a high-density parasellar mass with eroded anterior clinoid process on the right (fig. 3A). Cerebral angiography revealed a giant aneurysm of the right internal carotid artery (fig. 3B).

An intravascular occlusion test was performed by interrupting the carotid flow at 30 min after transcarotid balloon catheterization. Neither neurologic nor EEG changes were observed. Thereafter, the right internal carotid artery was permanently occluded with detachable ballons (figs. 3C and 3D). The patient had a satisfactory postoperative recovery and developed no additional neurologic symptoms, but sixth-nerve palsy persisted.

Two of four patients with giant aneurysm were treated by internal carotid artery occlusion. One patient developed moderate hemiparesis after experiencing a sudden drop in blood pressure.

Cerebral AVM

Three cases of cerebral AVM were treated by embolization. All three patients were catheterized with calibrated-leak balloons, and the feeding artery in each case was occluded with a fluid embolus (fig. 4). Postoperative angiography showed a definite decrease in shunt flow, but partial filling remained in all cases. No neurologic improvement was noted after the procedures.

Discussion

The detachable balloon catheterization technique proved very valuable in treating traumatic carotid-cavernous fistula by the intraarterial route. Despite the risk of cerebral ischemia, the advantages of this method exceed the disadvantages. We expect to develop a new catheter system to further improve this technique.

Before transcatheter embolization, the embolic material should be carefully prepared and selected to suit the specific problem in each case. Nonabsorbent material such as Ivalon sponge has a significant advantage over gelatin sponge because of its low rate of recanalization.

The efficacy of embolization in treating severe cerebral AVM is open to question. More research is necessary before complete evaluation can be made.

REFERENCES

1. Serbinenko FA. Balloon catheterization and occlusion of major cerebral vessels. *J Neurosurg* **1974**;41:125–145
2. Berenstein A, Kricheff II. Catheter and material selection for transarterial embolization. 1. Catheters. *Radiology* **1979**; 132:619–630
3. Debrun G, Lacour P, Caron JP, Hurth M, Comoy J, Keravel Y. Detachable balloon and calibrated leak balloon technique in the treatment of cerebral vascular lesions. *J Neurosurg* **1978**;49:635–649
4. Kerber CW. Balloon catheter with a calibrated leak. *Radiology* **1976**;120:547–550
5. Berenstein A, Kricheff II. Catheter and material selection for transarterial embolization. 2. Materials. *Radiology* **1979**; 132:631–639