

Are your MRI contrast agents cost-effective?
Learn more about generic Gadolinium-Based Contrast Agents.



AJNR

Ischemic chiasma syndrome.

K F Lee

AJNR Am J Neuroradiol 1983, 4 (3) 777-780
<http://www.ajnr.org/content/4/3/777>

This information is current as
of April 19, 2024.

Ischemic Chiasma Syndrome

K. Francis Lee¹

Thirty patients with chiasma syndrome attributed to ischemic processes of various origins are described. The initial diagnosis was made after an investigation based on polytome pneumoencephalography and angiography. This diagnosis was confirmed later with the use of high-resolution computed tomography (CT) and refined angiographic techniques. The ischemic chiasma syndrome may be classified into five pathogenetic categories: (1) mechanical compression of the chiasm secondary to ectatic tortuous arteries; (2) vascular occlusion secondary to atheromatous plaque formation; (3) arachnoiditis with fibrosis; (4) arteritis of various origins; and (5) postpartum necrosis. Sophisticated neurologic procedures including magnification angiography and high-resolution CT are essential in ruling out a mass lesion and correlating the clinical and radiologic findings of this syndrome.

Chiasma syndrome is most commonly caused by a neoplastic lesion near the sella turcica that affects the optic chiasm. However, identical chiasmatic visual defects may likewise be produced by a variety of nonneoplastic processes involving the chiasm. Arteriosclerosis is accepted as one of these [1, 2]. We have also reported the chiasma syndrome attributable to several ischemic processes [3].

More recently, we evaluated ischemic chiasma syndrome (ICS) using high-resolution computed tomography (CT) with high-dose contrast medium enhancement and magnification angiography. In order to correlate clinical and radiologic features of ICS, it is essential to demonstrate the precise anatomic relations among the optic nerve, chiasm, pituitary gland, and adjacent vasculature. The anatomic relation of the neurovascular structures in and around the sella turcica has been studied by many investigators [4-7]. We have also studied the vasculature of the optic nerve, chiasm, hypothalamus, pituitary gland, and diaphragma sellae in cadavers, showing multiple common blood supplies in the area [8].

Materials and Methods

Over a 16 year period, more than 300 patients with chiasmatic visual field defects were evaluated at Thomas Jefferson University Hospital, Willis Eye Hospital, and the University of Texas Health Science Center at Houston. Extensive neuroophthalmologic, neuroradiologic, and endocrinologic investigations were carried out in these patients to determine the cause of chiasma syndrome. In most cases, the syndrome was caused by primary or secondary neoplasms.

Before the advent of CT, our protocol for neuroradiologic evaluation of chiasma syndrome comprised: (1) plain skull films, (2) optic foramen views, (3) magnification angiography with subtraction, and

(4) polytome encephalography (continuous insufflation technique with 50-80 ml of nitrous oxide). In recent years, polytome gas encephalography has been replaced almost completely by high-resolution CT.

We now use a GE 8800 CT scanner with a high-dose contrast medium enhancement. Excellent opacification of the circle of Willis, cavernous sinus, and the pituitary gland is obtained with a rapid bolus injection and drip infusion (up to 82 g of iodine). Axial CT sections of the sella turcica and suprasellar region including the orbits are obtained with 1.5 mm contiguous sections (25-30 slices). Coronal and sagittal reformatted images are then obtained. When the sella turcica is not grossly enlarged, we perform direct coronal CT scanning by the 1.5 mm contiguous imaging method. The 5 mm with 3 mm increments technique is suitable for the evaluation of patients with enlarged sella in axial and coronal planes.

With these methods, the hypothalamic part of the third ventricle including the optic and infundibular recesses is clearly delineated, as are the chiasm, optic nerves, pituitary gland, infundibulum, and adjacent vessels. We still occasionally perform polytome gas encephalography with N₂O for evaluation of optochiasmatic arachnoiditis when CT findings are equivocal.

Results

Thirty patients in five etiologic categories of ICS were identified on the basis of clinical and neuroradiologic evaluations (table 1).

Type 1 consisted of ICS caused by mechanical compression of the optic nerve and chiasm due to redundant ectatic anterior cerebral and/or carotid arteries. Eight patients (four men and four women) made up this group. Low-lying ectatic anterior cerebral arteries were readily demonstrated to compress the chiasm or optic nerve against the sella as seen on polytome gas encephalogram [3] or on CT (fig. 1). Seven of the eight cases showed an empty sella.

Type 2 consisted of ICS caused by atheromatous narrowing or occlusion of the carotid arteries and their branches. Five patients (three men and two women) were in this category. Angiograms with subtraction technique demonstrated atheromatous narrowing or occlusion of the carotid arteries, with the carotid siphon and/or the origin of the internal carotid artery often being involved bilaterally (fig. 2). Empty sella was noted in four of the five cases. One patient showed a focal infarct in the right parietal region.

Type 3 ICS was caused by vascular encasement and occlusion secondary to diffuse arachnoidal adhesion and thickening. This group consisted of nine patients (six women and three men). Distortion and/or obliteration of the suprasellar cistern and recesses of the third ventricle could be demonstrated clearly on polytome gas encephalography and CT (figs. 3 and 4). Seven of the nine patients showed an empty sella.

Type 4 ICS was caused by arteritis of various origins. There were

¹ Department of Radiology, University of Texas Health Science Center at Houston, 6431 Fannin St., Houston, TX 77030.

TABLE 1: Summary of Findings in Ischemic Chiasma Syndrome

Type of ICS (Age Range)	No. Cases		Visual Impairment	Pituitary Function
	Total	With Empty Sella		
1: Low-lying ectatic anterior cerebral and carotid, pericallosal, or carotid arteries (60–80)	8	7	Slowly progressive	Low normal
2: Atherosclerotic plaque formation (50–70)	5	4	Gradual or acute onset	Usually low
3: Optochiasmatic arachnoiditis and fibrosis (20–60)	9	7	Gradual and progressive	Usually low
4: Arteritis with stenosis and dilatation of vessels (50–70)	3	2	Acute onset	Low
5: Postpartum pituitary necrosis and ischemia (20–30)	5	5	Acute onset, slow recovery	Depressed
	30	25		

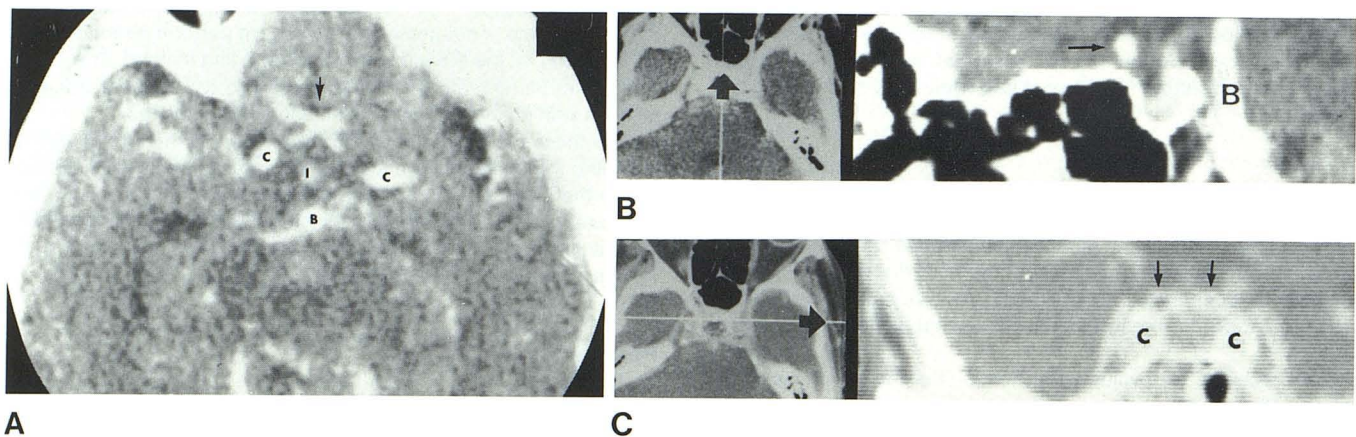


Fig. 1.—79-year-old woman with progressive bitemporal hemianopia due to low-lying arteriosclerotic anterior cerebral arteries (ICS type 1). A, High-resolution CT scan demonstrates excellent opacification of circle of Willis. Figures include carotid artery (C), basilar artery (B), infundibulum of pituitary (I), and low-lying anterior cerebral arteries (arrow). B, Reformatted sagittal image of axial CT shows low-lying anterior cerebral artery (arrow) compress-

ing optic chiasm. Pituitary stalk runs diagonally in front of dolichoectatic basilar artery (B). Note partly empty sella. C, Coronal reformatted image with high window level shows ectatic cavernous carotid (C) and anterior cerebral arteries (arrows) with sclerotic margin due to calcified vascular walls. Anterior cerebral arteries are situated so low that optic chiasm is compressed and flattened beneath low-lying vessels. Part of pituitary stalk is seen in center.

three patients (two women and one man) who showed angiographic evidence of arteritis, associated with pituitary insufficiency and bitemporal hemianopia. Two of the three patients demonstrated an empty sella. Angiography with subtraction showed evidence of arteritis with vascular stenosis (fig. 5).

Type 5 consisted of postpartum chiasma syndrome associated with pituitary necrosis. The five women in this group had an empty sella on polytome gas encephalogram [3, 9] or CT scan (fig. 6). Only one patient showed a slightly enlarged sella turcica.

Discussion

The chiasma syndrome is usually produced by compression of the chiasm. A variety of parasellar mass lesions, including neoplasms, granulomas, aneurysms, foreign bodies, and hematomas, may be responsible [1]. Nontumorous lesions such as demyelinating disease and trauma are rarer but definite causes.

Ischemic chiasma syndrome is believed to be secondary to various ischemic processes without evidence of mass lesion. Therefore, a mass lesion should be categorically excluded by neuroradiologic procedure before the diagnosis of ICS is considered [2, 3, 10].

Tubular or fusiform dilatation of arteries may compress the adjacent structures, producing neurologic symptoms [9, 10]. Similarly, ICS may develop secondary to mechanical compression of the optic chiasm, optic nerve junction, or both by a tortuous ectatic anterior cerebral artery [2, 3, 10]. In the case of a pituitary tumor growing upward, the anterior cerebral artery may act as a restrictive cord on the dorsal surface of the prechiasmatic optic nerve, with the resultant notching or grooving accounting for chiasmatic visual field defect [1, 4]. Infarction of the chiasm may develop as a result of focal ischemia produced by an intrinsic or extrinsic tumor [1, 11].

In order to establish the diagnosis of type 1 ICS, the anatomic relation of the anterior and/or carotid arteries to the chiasm and

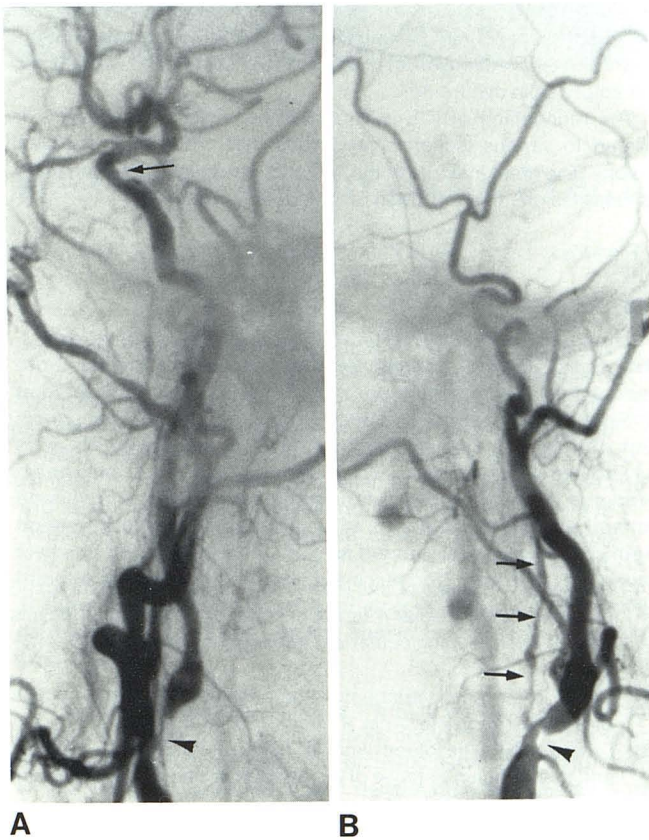
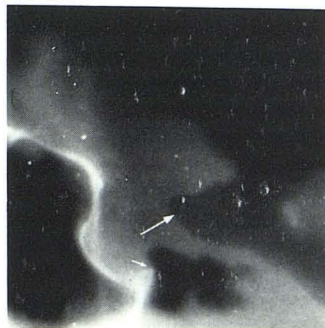

Fig. 2.—57-year-old man with progressive bitemporal hemianopia with small right nasal field defect due to severe atheromatous disease of carotid arteries (ICS type 2). **A**, Right carotid arteriogram shows marked atheromatous stenosis of internal carotid artery at its origin (*arrowhead*). Segmental narrowing of carotid siphon is also seen (*arrow*). **B**, Left carotid arteriogram shows irregular threadlike narrowing with distal occlusion of internal carotid artery (*arrows*). Marked atheromatous narrowing of left external carotid at origin (*arrowhead*).

Fig. 3.—32-year-old man with progressive visual loss with bitemporal hemianopia due to optochiasmatic arachnoiditis with fibrosis (ICS type 3). Polytome pneumoencephalogram shows obliteration of optic and infundibular recesses (*large arrow*), with nonfilling of suprasellar cistern and cisterna lamina terminalis. Trapped air in interpeduncular fossa and shortening of dorsum sellae (*small arrow*) also present. At surgery, diffuse thickening with adhesion of arachnoid around optic chiasm and nerves was found.



optic nerves should be precisely delineated by means of polytome pneumoencephalography or high-resolution CT. Although direct coronal CT provided useful information about the anatomic arrangement of the chiasm and arteries, axial CT with coronal and sagittal reformatted images is generally far superior in delineating the neurovascular anatomy. This is presumably due to relatively artifact-free images on axial scans (fig. 1). In our experience, presellar chiasm seems to be more readily compressed by a low-lying tor-

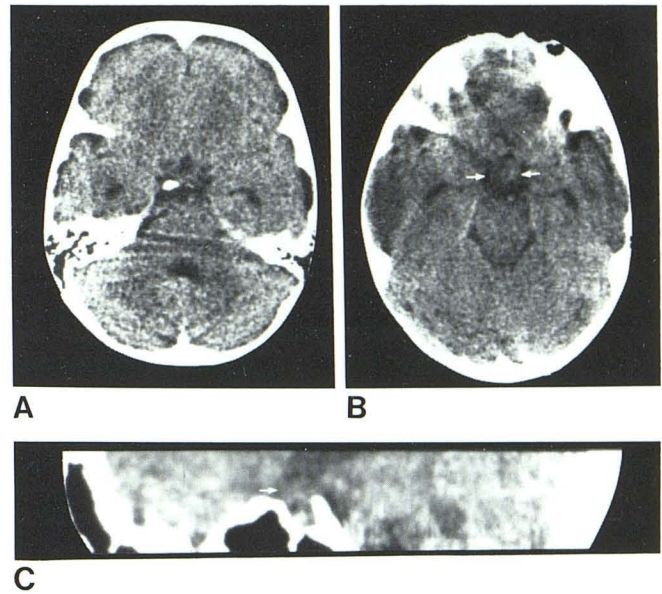


Fig. 4.—25-year-old woman with progressive bitemporal hemianopia due to optochiasmatic arachnoiditis (ICS type 3). **A**, Axial CT with 1.5 mm section shows partial obliteration of suprasellar cistern. **B**, Optic chiasm appears prominent with indistinct margin (*arrows*). **C**, Sagittal reformatted image shows partial effacement of recesses of third ventricle with matted chiasm and optic nerve complex (*arrow*). Sella is partly empty.

tuos anterior cerebral artery against the chiasmatic sulcus or planum sphenoidale.

Ischemia of the optic nerve and chiasm may be produced by atheromatous plaque in the circle of Willis (especially) and in the cavernous portions of the carotid arteries, with partial or complete occlusion of the arterial twigs supplying the optic structure, as observed in type 2. Advanced atheromatous carotid disease may produce pituitary insufficiency in addition to visual symptoms because of the common blood supply to the pituitary and chiasm [6, 8]. Magnification angiography with subtraction technique is important in demonstrating the atheromatous changes.

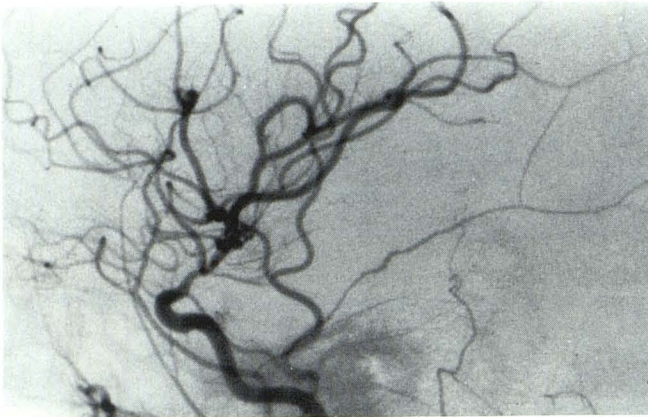
Type 3 ICS was due to diffuse arachnoiditis with dense fibrosis encasing the optic structures. Five of the nine cases were related to the previous radiation therapy for pituitary tumors with resultant fibrosis, while the other four cases were secondary to sarcoidosis (three cases) and a nonspecific granuloma (one case). Polytome pneumoencephalography with continuous insufflation of N_2O provided the best result in delineating the obliterated recesses of the third ventricle as well as trapping of gas in the interpeduncular cistern, with poor or no filling of the suprasellar cistern or cisterna lamina terminalis (fig. 3). CT scanning with diluted metrizamide is helpful also in demonstrating a distorted chiasm or optic nerve, but we consider polytome pneumoencephalography to be superior in assessing the degree of arachnoidal adhesions.

Type 4 ICS was produced by arteritis of various origins. Giant-cell arteritis, systemic lupus erythematosus, and periarteritis nodosa, respectively, were responsible for arteritis with resultant ICS in three cases investigated. Again, subtraction angiography was essential in establishing the diagnosis in this group.

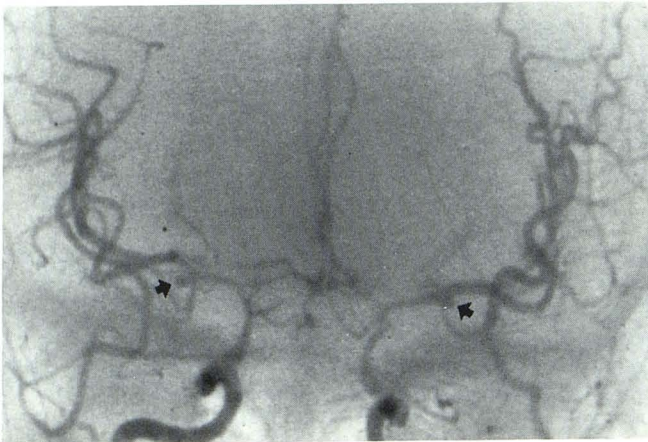
Type 5 ICS was secondary to postpartum pituitary necrosis or Sheehan syndrome. According to Sheehan [12], postpartum necrosis of the anterior lobe of the pituitary is not uncommon, and acute necrotic lesions are mostly related to postpartum necrosis. How-

ever, diabetes, cranial arteritis, and cavernous sinus thrombosis are also etiologic factors.

We noted a very high incidence (25 of 30: 83%) of empty sella with ICS. Incompetent diaphragma sellae may be purely develop-



A



B

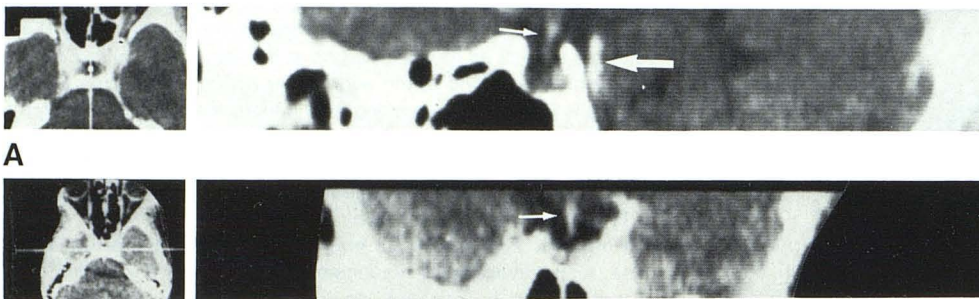
Fig. 5.—55-year-old woman with acute onset of blurred vision with bitemporal hemianopia secondary to systemic lupus erythematosus (ICS type 4). **A**, Diffuse attenuation of carotid siphon just above level of anterior clinoid bilaterally. **B**, Small incidental aneurysm at trifurcation of middle cerebral artery bilaterally (arrow). No evidence of recent subarachnoid hemorrhage.

mental in some cases [8]. It is probable, however, that deficient diaphragma sellae may be caused by ischemic necrosis with resultant intrasellar extension of subarachnoid space, thus producing the empty sella syndrome.

The recognition of ICS is important because this syndrome is related to various ischemic processes that produce nonsurgical lesions. The great majority of the chiasma syndromes are secondary to mass lesions that are often amenable to surgery.

REFERENCES

1. Walsh FB, Hoyt WF. *Clinical neuro-ophthalmology*. Baltimore: Williams & Wilkins, 1975:1778, 1883, 2100
2. Lee KF, Schatz NJ, Hodes PJ. Arteriosclerotic chiasmal syndrome. Presented at the annual meeting of the American Society of Neuroradiology, New Orleans, September 1968
3. Lee KF, Schatz NJ. Ischemic chiasmal syndrome. Presented at the X Symposium Neuroradiologicum, Punta del Este, Uruguay, March 1974. *Acta Radiol [Suppl]* (Stockh) 1975;347:131-148
4. Schaeffer JP. Some points in the regional anatomy of the optic pathways with special reference to tumors of the hypophysis cerebri and resulting ocular changes. *Anat Rec* 1924;28:243-279
5. Bull J. The normal variations in the position of the optic recess of the third ventricle. *Acta Radiol* 1956;46:72-80
6. Dawson BH. The blood vessels of the human optic chiasma and their relation to those of the hypophysis and hypothalamus. *Brain* 1958;81:207-217
7. Parkinson D. Collateral circulation of cavernous carotid artery; anatomy. *Can J Surg* 1964;7:251-267
8. Lee KF, Parke W, Lin SR, Choi HY, Schatz NJ. The vasculature of the diaphragma sellae. A postmortem injection study. *Neuroradiology* 1978;26:281-283
9. Lee KF, Lin SR. *Neuroradiology of sellar and juxtasellar lesions*. Springfield, IL: Thomas, 1979:352, 403
10. Hilton GF, Hoyt WF. An arteriosclerotic chiasmal syndrome; bitemporal hemianopia associated with fusiform dilatation of the anterior cerebral arteries. *JAMA* 1966;196:200-202
11. Schneider RC, Kriss FC, Falls HF. Prechiasmal infarction associated with intrachiasmal and suprasellar tumors. *J Neurosurg* 1970;2:197-208
12. Sheehan HL, Summers VK. The syndrome of hypopituitarism. *Q J Med* 1949;18:319-378



A

B

Fig. 6.—25-year-old woman with chiasmatic visual defect due to Sheehan syndrome (ICS type 5). Sagittal (A) and coronal (B) reformatted images show evidence of empty sella. Pituitary stalk (small arrows) enters sella with intrasellar herniation of suprasellar cistern. Sella is normal in size with slightly rounded contour. Basilar artery (large arrow).