

Are your MRI contrast agents cost-effective?

Learn more about generic Gadolinium-Based Contrast Agents.



FRESENIUS  
KABI

caring for life

# AJNR

**Celebrating 35 Years of the AJNR: January  
1987 edition**

*AJNR Am J Neuroradiol* 2022, 43 (1) 157

doi: <https://doi.org/10.3174/ajnr.P6840>

<http://www.ajnr.org/content/43/1/157.citation>

This information is current as  
of April 20, 2024.

# Celebrating 35 Years of the AJNR

January 1987 edition

## Chemoneucleation and Changes Observed on Lumbar MR Scan: Preliminary Report

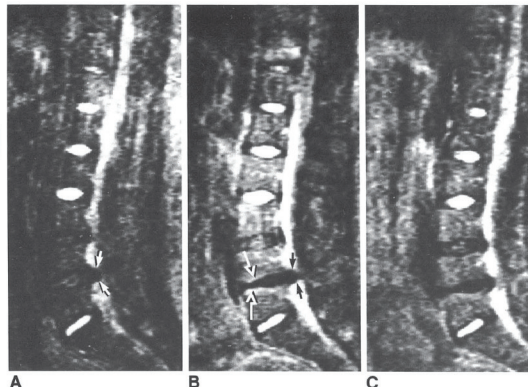
Michael S. Huckman<sup>1</sup>  
John W. Clark<sup>1</sup>  
Thomas W. McNeill<sup>1</sup>  
Walter W. Whisler<sup>2</sup>  
William F. Hejna<sup>3</sup>  
Eric J. Russell<sup>4</sup>  
Ruth G. Ramsay<sup>1</sup>  
David Turner<sup>1</sup>

This study examines the relation between the postchemoneucleation clinical outcome and changes observed on the lumbar MR scan. Eight of 12 chemoneucleated disks showed clinical improvement at the last follow-up, while the other four showed no improvement. In the cases that showed improvement there was a decrease in one or both dimensions of the defect in the thecal sac. Seven of eight showed an increase in the peridisk signal. Where there was no clinical improvement there were fewer decreases in the size of the defect, and three of four showed no increase in the peridisk signal.

Chemoneucleation of the lumbar intervertebral disk was introduced by Smith [1] as an alternative to laminectomy for the treatment of herniated lumbar nucleus pulposus. As more recent studies have attested to the efficacy of this technique [2-8], its use has increased dramatically. With the development of sophisticated CT scanning equipment have come several studies that correlated the clinical outcome of this procedure with the radiographic changes it produces [9-11]. A description of the MR changes caused by chemoneucleation has also been reported [12]. Our current study was undertaken to determine the correlation between changes in the lumbar MR examination before and after chemoneucleation, and the clinical outcome.

### Subjects and Methods

Eleven patients with signs and symptoms of herniated lumbar nucleus pulposus at L4-L5 or L5-S1 were entered into the study after confirmation of the diagnosis by both lumbar CT



Received May 14, 1986; accepted July 22, 1986.  
Presented in part at the annual meeting of the American Society of Neuroradiology, January 1986.  
This work was supported by a grant Laboratories, Northbrook, IL.  
<sup>1</sup>Department of Diagnostic Radiology, Presbyterian-St. Luke's Medical Center, IL 60612. Address reprint requests to this author.  
<sup>2</sup>Department of Orthopedic Surgery, Presbyterian-St. Luke's Medical Center, IL 60612.  
<sup>3</sup>Department of Neurological Surgery, Presbyterian-St. Luke's Medical Center, IL 60612.  
AJNR 8:1-4, January/February 1987  
0195-6108/87/0801-0001  
© American Society of Neuroradiology

## MR Imaging of the Cervical Spine: Neurovascular Anatomy

Bonnie D. Flannigan<sup>1,2</sup>  
Robert B. Lufkin<sup>1</sup>  
Charles McClade<sup>1</sup>  
James Winters<sup>1</sup>  
Ulrich Batzdorf<sup>3</sup>  
Gabriel Wilson<sup>4</sup>  
Wolfgang Rauschnig<sup>5</sup>  
William G. Bradley, Jr.<sup>5</sup>

High-resolution surface-coil MR imaging reveals intricate anatomic detail of the cervical spinal canal and its neurovascular contents. Appreciation of the normal neurovascular anatomy provides a scientific foundation for the detection of disease. Sagittal, axial, and oblique MR images of normal subjects were correlated with comparable anatomic sections obtained with a cryomicrotome whole-organ sectioning technique. The anterior epidural venous plexus is a prominent structure in the cervical spinal canal and was consistently identified both with cryomicrotomy and with MR in sagittal and axial planes. Epidural veins can be displaced and distorted in patients with cervical disk disease. Nerve roots including dorsal and ventral rootlets were consistently identified on axial images coursing through the subarachnoid space. Oblique-plane imaging showed nerve roots "en face" in their respective foramina; this may be a useful imaging technique in the diagnosis of nerve root impingement.

This study was undertaken to define normal anatomic structures within the cervical spinal canal using MRI, with particular attention to the cervical epidural veins and the cervical nerve roots. Abnormal anatomy can only be detected in comparison to normal anatomy. High-resolution MR images obtained in sagittal, axial, and oblique planes were correlated with corresponding anatomic sections obtained with a cryomicrotome whole-organ sectioning technique. The anterior epidural cervical venous plexus is a prominent structure previously well-identified with bolus intravenous contrast CT studies. It was consistently identified on parasagittal images and also on axial images in the anterolateral recesses of the spinal canal on T1-weighted MR images. Its normal appearance should be appreciated, since distortion of this extensive venous network can occur in patients with cervical disk disease.

Axial imaging allows identification of both the ventral and dorsal nerve roots individually as they course through the subarachnoid space. Significant neural foraminal disease may be difficult to identify in the axial and sagittal plane, making MR somewhat controversial as an imaging technique in the patient with an isolated radiculopathy. Electronically activated oblique-plane imaging was used to show the nerve roots in their respective neural foramina. This may be a useful method for evaluating patients with radiculopathy.

### Materials and Methods

Cervical spine examinations were performed on 30 volunteers using a flexible neck coil and a 0.3 T permanent magnet imaging system (Fonar B-3000, Melville, NY). The vertical orientation of the axis of the main magnetic field allowed the use of a solenoidal (circumferential) neck coil. Multislice imaging was performed in the axial, sagittal, and oblique planes using a spin-echo, multislice pulse sequence. Electronically activated oblique-plane imaging was performed by using an axial scout image and placing line cursors perpendicular to one neural foramen and parallel to the opposite foramen (see Fig. 5A). This enabled us to obtain images of the nerve roots on one side "en face" comparable to a 45° oblique plain radiograph.

This article appears in the January/February 1987 issue of AJNR and the April 1987 issue of AJNR.  
Received December 19, 1985; accepted after revision July 10, 1986.  
<sup>1</sup>Department of Radiological Sciences, UCLA Medical Center, Los Angeles, CA 90024. Address reprint requests to B. D. Flannigan.  
<sup>2</sup>Present address: Valley Presbyterian Hospital, 15107 Vanowen St., Van Nuys, CA 91405.  
<sup>3</sup>Department of Neurosurgery, UCLA Medical Center, Los Angeles, CA 90024.  
<sup>4</sup>Department of Orthopedics, University Hospital, Uppsala, Sweden.  
<sup>5</sup>MRI Imaging of the Laboratory, Huntington Medical Research Institutes, Pasadena, CA 91109.  
AJNR 8:27-32, January/February 1987  
0195-6108/87/0801-0027  
© American Society of Neuroradiology

