

Are your **MRI contrast agents** cost-effective?

Learn more about generic **Gadolinium-Based Contrast Agents**.



**FRESENIUS
KABI**

caring for life

AJNR

The Cochlea in Branchio-Oto-Renal Syndrome: An Objective Method for the Diagnosis of Offset Cochlear Turns

A.F. Juliano, F. D'Arco, J. Pao, S. Picariello, E. Clement, G. Moonis and C.D. Robson








This information is current as of April 19, 2024.

AJNR Am J Neuroradiol 2022, 43 (11) 1646-1652

doi: <https://doi.org/10.3174/ajnr.A7653>

<http://www.ajnr.org/content/43/11/1646>

The Cochlea in Branchio-Oto-Renal Syndrome: An Objective Method for the Diagnosis of Offset Cochlear Turns

 A.F. Juliano,  F. D'Arco,  J. Pao,  S. Picariello,  E. Clement,  G. Moonis, and  C.D. Robson

ABSTRACT

BACKGROUND AND PURPOSE: An “unwound” or “offset” cochlea has been described as a characteristic imaging feature in patients with branchio-oto-renal syndrome, and recently recognized to be associated in particular to those with *EYAI* gene mutations. Determination of this feature has traditionally relied on subjective visual assessment. Our aim was to establish an objective assessment method for cochlear offset (the cochlear turn alignment ratio) and determine an optimal cutoff turn alignment ratio value that separates individuals with *EYAI*-branchio-oto-renal syndrome from those with *SIX1*-branchio-oto-renal syndrome and healthy controls.

MATERIALS AND METHODS: Temporal bone CT or MR imaging from 40 individuals with branchio-oto-renal syndrome and 40 controls was retrospectively reviewed. Cochlear offset was determined visually by 2 independent blinded readers and then quantitatively via a standardized technique yielding the cochlear turn alignment ratio. The turn alignment ratio values were compared between cochleae qualitatively assessed as “not offset” and “offset.” Receiver operating characteristic analysis was used to determine the ability of the turn alignment ratio to differentiate between these populations and an optimal cutoff turn alignment ratio value. Cochlear offset and turn alignment ratio values were analyzed for each branchio-oto-renal syndrome genotype subpopulation and for controls.

RESULTS: The turn alignment ratio can accurately differentiate between cochleae with and without an offset ($P < .001$). The optimal cutoff value separating these populations was 0.476 (sensitivity = 1, specificity = 0.986, $J = 0.986$). All except 1 cochlea among the *EYAI*-branchio-oto-renal syndrome subset and all with unknown genotype branchio-oto-renal syndrome had a cochlear offset and a turn alignment ratio of <0.476 . All except 1 cochlea among the *SIX1*-branchio-oto-renal syndrome subset and all controls had no offset and a turn alignment ratio of >0.476 .

CONCLUSIONS: There is a statistically significant difference in turn alignment ratios between offset and nonoffset cochleae, with an optimal cutoff of 0.476. This cutoff value allows excellent separation of *EYAI*-branchio-oto-renal syndrome from *SIX1*-branchio-oto-renal syndrome and from individuals without branchio-oto-renal syndrome or sensorineural hearing loss. The turn alignment ratio is a reliable and objective metric that can aid in the imaging evaluation of branchio-oto-renal syndrome.

ABBREVIATIONS: BOR = branchio-oto-renal syndrome; ROC = receiver operating characteristic; TAR = turn alignment ratio

Branchio-oto-renal syndrome (BOR) is a cause of hearing loss with autosomal dominant inheritance, first described in 1975 in a family with hearing loss, cup-shaped anteverted pinnae, preauricular pits, branchial fistulas, and renal dysplasia.¹ Cochlear

hypoplasia was later noted on tomography.² Since then, with the advent of CT and MR imaging, much more has been described in the literature of characteristic features of the temporal bone among patients with BOR, most notably an “unwound” or “offset” appearance of the cochlea,^{3,4} in which small middle and apical turns are anteriorly offset and appear separated from the basal turn. Most recently, it was shown that the offset appearance of cochlear middle and apical turns is indeed a distinctive finding among patients with BOR, but only among those with *EYAI* gene mutations having the *EYAI* genotype-phenotype; patients with *SIX1* mutations have different phenotypes without cochlear offset,

Received May 2, 2022; accepted after revision August 19.

From the Department of Radiology (A.F.J.), Massachusetts Eye and Ear, Harvard Medical School, Boston, Massachusetts; Department of Radiology (F.D.), Great Ormond Street Hospital for Children, London, UK; Department of Radiology (J.P.), Orlando Health, Orlando Regional Medical Center, Orlando, Florida; Department of General and Specialized Surgery for Women and Children (S.P.), University of Campania “Luigi Vanvitelli,” Naples, Italy; Neuro-Oncology Unit (S.P.), Department of Paediatric Oncology, Santobono-Pausilipon Children’s Hospital, Naples, Italy; Department of Clinical Genetics (E.C.), Great Ormond Street Hospital for Children National Health Service Foundation Trust, London, UK; Department of Radiology (G.M.), NYU Langone Medical Center, New York, New York; and Department of Radiology (C.D.R.), Boston Children’s Hospital, Harvard Medical School, Boston, Massachusetts.

A.F. Juliano and F. D’Arco are co-first authors.

Please address correspondence to Amy F. Juliano, MD, Department of Radiology, Massachusetts Eye and Ear, 243 Charles St, Boston, MA 02114; e-mail: amy_juliano@meei.harvard.edu; @amyfjuliano

<http://dx.doi.org/10.3174/ajnr.A7653>

but the apical turns have a protuberant “thorny” appearance.⁵ The differing genotype-phenotype correlation could be related to different functions of the *SIX1* and *EYAI* genes, and the different sites of expression and roles of the resultant proteins in the cochlea during the embryologic development of the inner ear. Recognition of these distinct phenotypes on imaging and knowledge of the respective genotype-phenotype correlation offers a powerful tool to radiologists, who can then suggest a genetic diagnosis in the context of a potential syndromic presentation compatible with BOR.⁵

With regard to the offset cochleae seen among patients with *EYAI*-BOR, prior description and determination of this feature in the literature has been based on visual assessment.^{3,4,6} This presumes familiarity with normal cochlear morphology, in order to recognize when the middle and upper turns of the cochleae are anteromedially displaced by a degree that is more than expected for the typical normal cochlea. However, this recognition may be challenging for radiologists who do not regularly interpret temporal bone imaging, and there may be other conditions in which the cochlear turns are not aligned normally or where the turns may not be sufficiently offset to raise the suspicion for *EYAI*-BOR syndrome or another anomaly.

The aim of this study was to define and quantify the cochlear turn alignment ratio (TAR), to analyze the TAR among both cochleae with offset and cochleae without offset as visually assessed by expert head and neck radiologists (the traditional/usual method of assessment), and to determine whether there is a distinct TAR cutoff value that distinguishes the 2 groups. We then examined the cochleae of patients with *EYAI*-BOR, those with *SIX1*-BOR, patients with BOR of unknown genetic association, and controls without evidence of sensorineural hearing loss to determine whether there are quantitative TAR cutoff values that can distinguish patients with BOR from healthy controls and patients with *EYAI*-BOR from those with *SIX1*-BOR. The goal was to establish objective metrics that can separate these populations from each other. The resultant TAR measurement method and criteria can aid any radiologist in the determination of “how offset is too offset” with objectivity and establish normative TAR values for the normal cochlea.

MATERIALS AND METHODS

Participants

This was a multicenter retrospective review of temporal bone imaging studies among individuals with clinically diagnosed BOR (from the same database we previously used for qualitative comparison of BOR cochlear phenotypes) and controls without BOR or sensorineural hearing loss. For the BOR group, 40 individuals from 4 participating institutions were included; inclusion criteria were a clinical diagnosis of BOR syndrome⁷ and diagnostic temporal bone CT and/or MR imaging available for review. Among these 40 patients, 16 had known underlying causative *EYAI* genetic mutations, 4 had known *SIX1* genetic mutations, and 20 had not undergone genetic testing. For the control group, consecutive multidetector row CT scans of 40 patients without clinical or audiometric evidence of sensorineural hearing loss who underwent temporal bone CT for symptoms unrelated to hearing loss (eg, otalgia, otitis media, dizziness, facial palsy) were included. Imaging among the BOR group occurred between April 2001 and April

2021. Imaging among the control group occurred between January 2019 and December 2020. This study was approved by the institutional review board/ethics committee of each institution.

Image Acquisition

BOR Group. Of the 40 patients, 33 had undergone CT, 6 had undergone MR imaging, and 1 had undergone both CT and MR imaging. All CT scanners across the participating institutions were helical multidetector row scanners (Discovery 750 HD, LightSpeed Pro 16 SYS, HiSpeed CT/i SYS, or HiSpeed RP SYS; GE Healthcare; SOMATOM Sensation 40 or SOMATOM Force SYS; Siemens) with parameters ranging as follows: 120 kV (peak), 100–200 mA, section thickness = 0.6–0.625 mm, some with an overlap of 0.2 mm. All MR imaging scanners across the participating institutions were 3T units, with assessment conducted on the heavily T2-weighted sequence such as 3D driven equilibrium radiofrequency reset pulse (DRIVE; Philips Healthcare), constructive interference in steady state (CISS; Siemens), and T2 sampling perfection with application-optimized contrasts by using different flip angle evolution (T2 SPACE; Siemens). All temporal bone images were uploaded onto the PACS, with axial reformats created in a plane parallel to the plane of the lateral semicircular canal (or estimated to be so in cases when the lateral semicircular canal was anomalous), and coronals perpendicular to these reformatted axials, before image analyses.

Control Group. Multidetector row CT scanning (Discovery 750 HD) of the temporal bone was performed with 120 kV(p), 240 mA, 0.6-mm section thickness, and 0.2-mm overlap. Axial reformats of the temporal bones were created in a plane parallel to the lateral semicircular canal, and coronals perpendicular to these reformatted axials before image analyses.

Image Review

Two neuroradiologists with 5 (J.P.) and 15 (A.F.J.) years of experience with subspecialty head and neck expertise reviewed all cases and controls. The reviewers were blinded to the original reports, patient demographics, clinical diagnoses including whether there was BOR syndrome, underlying genetic abnormality, and the other reviewer’s findings.

Qualitative Assessment. The cochleae of all enrolled individuals (patients with BOR and controls) were assessed qualitatively on standardized reformatted axial images in the plane of the lateral semicircular canal. Each cochlea was designated as “with offset” or “without offset” by consensus. Any thorny appearance of the apical turn of the cochlea was also noted as present or absent.⁵

Quantitative Assessment. For each ear, the TAR of the cochlea was assessed quantitatively on standardized reformatted axial images in the plane of the lateral semicircular canal, with the following methodology (Fig 1):

- A line was drawn parallel to the long axis of the basal turn, extending from the round window to the medial bend (line *a*).
- The midpoint of the last complete uppermost turn/apex was identified (point *b*).

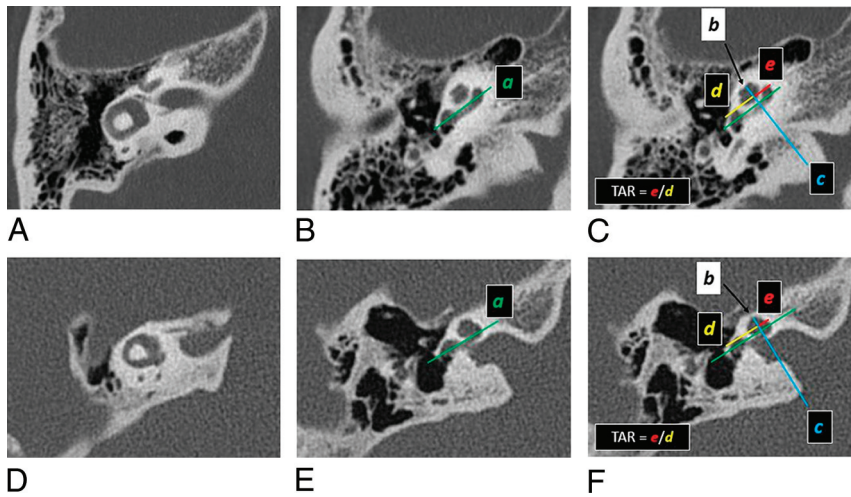


FIG 1. Assessment of TAR of the cochlea on a patient without BOR (A–C) and a patient with *EYAI*-BOR (D–F). Standardized reformatted axial images are utilized, in which the planes are parallel to the plane of the lateral semicircular canal (A and D). Line *a* (green) is drawn parallel to the long axis of the basal turn (B and E), which is propagated across all axial images, including those where the apical or uppermost developed turn is visible (C and F). The midpoint of the uppermost turn is identified on the image that best displays it (black arrows in C and F); this point (point *b*) can also be propagated across all axial images. Line *c* (blue) is then drawn through point *b* (black arrow), perpendicular to line *a* (green). Distance *d* (between the anterior round window and the point of intersection, in yellow) and distance *e* (between medial bend of basal turn and the point of intersection, in red) are measured. TAR is e/d . As can be seen on these images, TAR in the patient with *EYAI*-BOR (F) is smaller than in the patient without BOR (C).

- A perpendicular line was drawn from point *b* to intersect line *a* at a right angle (line *c*), using the “angle” function on PACS to ensure that the angle of intersection measured 90° .
- The distance from the anterior border of the round window to the point of intersection was recorded (distance *d*).
- The distance from the point of intersection to the medial bend of the basal turn was recorded (distance *e*).
- TAR is defined as e/d .

These lines and points were usually not all appreciated on 1 single axial plane; thus, care was taken to scroll through consecutive images while keeping the electronic caliper fixed at 1 point from the initial index image before reaching the end point on another image, or lines were propagated across images with identical orientation. When there was need for confirmation, minimum-intensity projections were made to view structures in a stack.

To accurately and reproducibly quantify the cochlear offset, we carefully determined cochlear turns by considering the cochlea in fifths as mentioned by Fitch et al⁸ and Chen et al.⁹ The basal turn constitutes the first and second fifths (from the round window to the medial bend, then the medial bend back to the lateral edge), the middle turn constitutes the third and fourth fifths (from the lateral edge to the medial bend, then the medial bend back to the lateral edge), and the apical turn is the last fifth (from the lateral edge at the end of the middle turn going medially toward the end of the tip) (Fig 2). The very short segment of the cochlea that is relatively linear, extending from the round window to the point when the cochlea begins to coil, has been referred to as the “hook region” of the cochlea.^{10,11} For this study, we followed the methodology of a previously published article,⁵ in which the hook region of the cochlea is

grouped with the spiraling main portion of the basal turn to be collectively considered as the first fifth, ensuring a standardized lateral boundary of the basal turn at the round window membrane and thus ensuring measurement consistency.

Statistical Analysis

On the basis of qualitative assessment, the cochleae of all enrolled individuals were divided into 2 groups: with offset and without offset. The number of individuals with *EYAI*-BOR, *SIX1*-BOR and unknown-mutation BOR and healthy controls (non-BOR and without hearing loss) in each group was noted.

On the basis of quantitative assessment that yielded TAR numeric values, interrater reliability was evaluated by the intraclass correlation coefficient. Due to excellent agreement, the average of the 2 readers was used for further analysis.^{12,13}

Continuous parametric variables are presented as mean (SD), whereas categorical data are presented as number and percentage. Normal distribution was determined using the Shapiro-Wilk test ($P > .05$) and histogram plots. A

Student *t* test was performed to explore whether the offset ratio was different between cochleae qualitatively deemed to be with and without offset. Receiver operating characteristic (ROC) curve analysis was used to determine the diagnostic accuracy of the offset ratio. The optimal cutoff point was determined by the Youden index *J*. *P* values $< .05$ were considered statistically significant.

SPSS Statistics 22 software (IBM) was used to perform the analyses. GraphPad Prism 7 (GraphPad Software) was used for graphing.

RESULTS

Eighty participants with a total of 160 cochleae were included in this study: 16 participants (32 cochleae) with *EYAI* mutations, 4 (8 cochleae) with *SIX1* mutations, 20 (40 cochleae) with BOR of unknown genotype, and 40 (80 cochleae) controls (Table 1).

There was excellent interrater reliability in the TAR measurements obtained by the 2 independent reviewers, with an intraclass correlation coefficient of 0.976. The values within each of the 2 groups (offset and not offset) followed normal distributions.

The cochleae deemed “not offset” by visual assessment had TAR values ranging from 0.492 to 0.741; the cochleae deemed “offset” by visual assessment had TAR values ranging from 0.189 to 0.460 with 1 outlier at 0.556 (Fig 3). The mean TAR value was significantly lower in cochleae with offset (0.338 [SD, 0.063]) compared with those without offset (0.599 [SD, 0.050]) ($P < .001$).

ROC curve analysis showed that TAR can accurately distinguish between cochleae with anterior offset and those without, with an area under the curve (AUC) value of 0.997 (95% CI, 0.992–1) ($P < .001$) (Fig 4). Based on Youden index *J*, the optimal cutoff value was 0.476 (sensitivity = 1, specificity = 0.986, $J = 0.986$). TAR

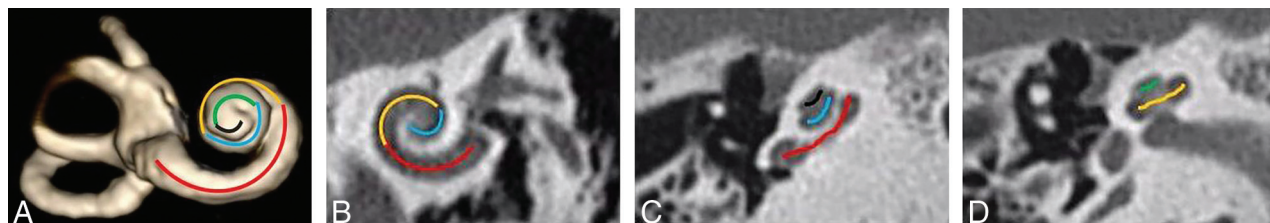


FIG 2. A, Fifths of a cochlea, as demonstrated on a 3D reconstruction of the inner ear from a heavily T2-weighted sequence (3D DRIVE). The first fifth is in red (including the hook region), the second fifth in orange, the third fifth in blue, the fourth fifth in green, and the fifth fifth in black. (B, C, and D). CT of the temporal bone in a bone algorithm in the Stenvers view (B) and axial (C and D) planes shows the fifths of the cochlea in the same color scheme as depicted on the 3D model in A.

Table 1: Qualitative (columns 3 and 4) and quantitative assessment (TAR, column 5) of cochlear offset

	Total No. of Cochleae	No. of Cochleae with Offset	No. of Cochleae without Offset	Mean TAR
<i>EYAI</i> -BOR	32	32	0	0.338 (SD, 0.071)
<i>SIX1</i> -BOR	8	1	7	0.577 (SD, 0.107)
Unknown genotype BOR	40	40	0	0.339 (SD, 0.057)
Controls	80	0	80	0.598 (SD, 0.051)

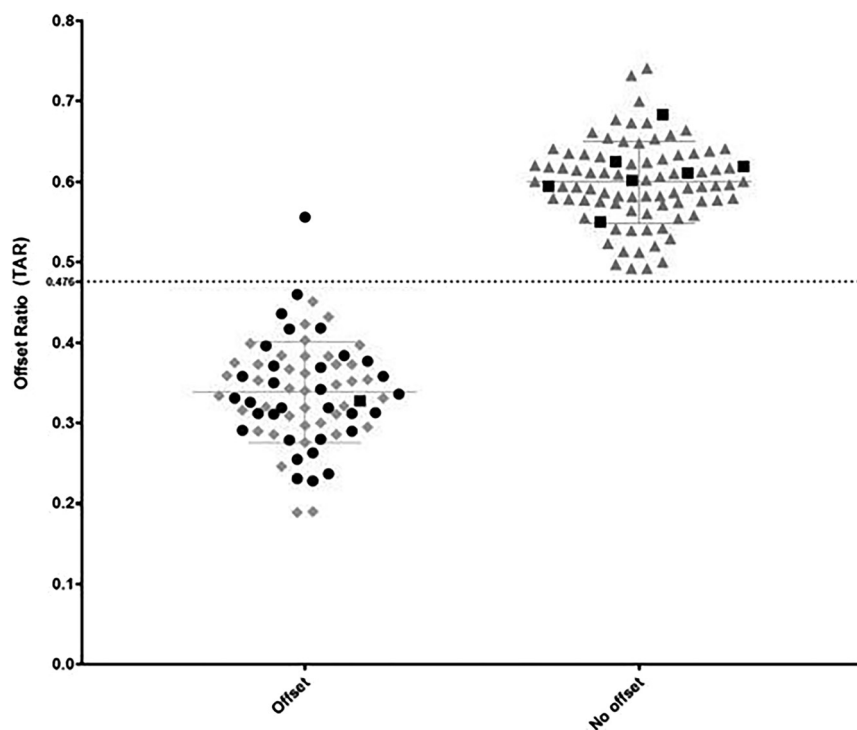


FIG 3. Cochlear TAR among cochleae-deemed offset and not offset on visual assessment. *EYAI*-BOR: black round dots; *SIX1*-BOR: black square dots; unknown genotype: gray rhomboid dots; controls: gray triangle dots. The dashed line indicates the TAR cutoff (0.476) as determined by ROC curve analysis.

values above the cutoff were predictive of a lack of cochlear offset, whereas values below 0.476 were associated with cochlear offset.

Seventy-three cochleae showed anterior offset. Of these, 32 were among patients with *EYAI*-BOR, 1 was among patients with

SIX1-BOR, and 40 were among patients with BOR of unknown genotype. Eighty-seven cochleae showed no offset. Of these, 7 were among patients with *SIX1*-BOR, and the remaining 80 were controls. Of note, all 80 controls showed no offset.

The mean TAR among patients with *SIX1*-BOR (0.577 [SD, 0.107]) was similar to that among controls (0.598 [SD, 0.051]), with none <0.476. The mean TAR among patients with *EYAI*-BOR (0.338 [SD, 0.071]) was much lower. The mean TAR among patients with BOR of unknown genotype (0.339 [SD, 0.057]) was similar to that among patients with *EYAI*-BOR, and all were <0.476. These are listed in Table 1 and depicted in Fig 5.

On qualitative assessment, all individuals with *EYAI*-BOR (32 cochleae of a total of 32) and BOR of unknown genotype (40 cochleae of a total of 40) had bilateral offset cochleae (Fig 6). None had a thorny apical turn (Table 2). On the contrary, cochlear offset was not seen in individuals with *SIX1*-BOR except in 1 cochlea; that cochlea appeared different from the typical unwound, offset cochlea but instead fit the description of cochlear hypoplasia type 4 (Fig 7)^{14,15} and lacked a thorny apical turn. The remainder of the *SIX1*-BOR cochleae had thorny tips (7 cochleae of 8). None of the controls had cochlear offset or a thorny apical turn.

DISCUSSION

The presence of a cochlear offset associated with *EYAI*-BOR has traditionally been determined qualitatively, whereby the radiologist visually estimates whether the alignment of the cochlear turns appears to be anomalous, with the upper turns anteriorly displaced and slightly tipped away relative to the basilar turn, outside the range of normal.

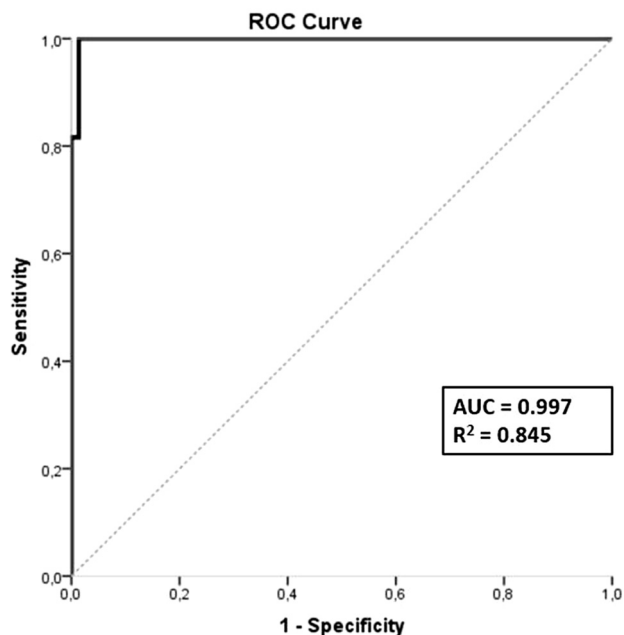


FIG 4. ROC curve.

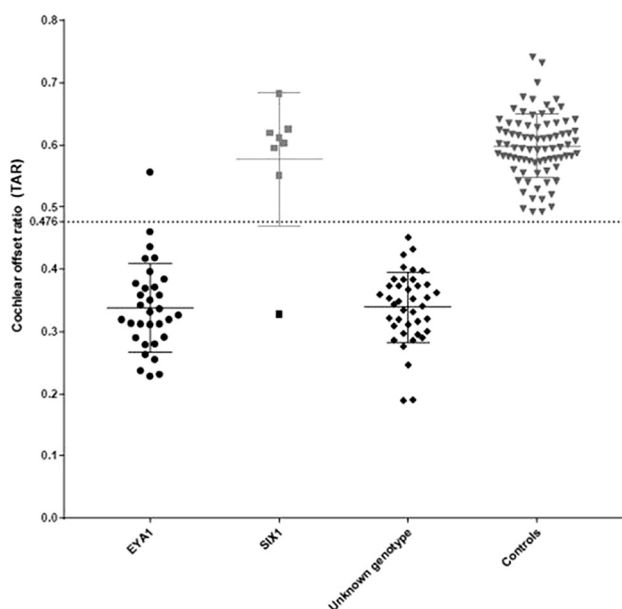


FIG 5. Cochlear TAR among individuals with *EYA1*-BOR, *SIX1*-BOR, BOR of unknown genotype, and controls without BOR or sensorineural hearing loss. The TAR cutoff of 0.476 was determined by ROC curve analysis. All except one of the *EYA1*-BOR cochleae have TAR below the cutoff value. All except one of the *SIX1*-BOR cochleae have TAR above the cutoff value. All individuals with BOR of unknown genotype have TAR below the cutoff value. None of the controls have TAR below the cutoff value.

However, this estimation may be challenging for radiologists who do not routinely interpret temporal bone imaging studies. In this study, we explored an objective method to evaluate and quantify the presence of an anteriorly offset or unwound cochlea in patients with *EYA1*-BOR, to provide a reproducible and reliable diagnostic tool for all radiologists.

All of our patients with a clinical diagnosis of BOR and confirmed *EYA1* mutations (16 patients, 32 cochleae) had anteriorly offset cochleae on subjective visual analysis. We found that there was a statistically significant difference in TAR between individuals with *EYA1*-BOR and controls without a diagnosis of BOR or sensorineural hearing loss. The optimal cutoff value for the upper limit of TAR that produced the greatest sensitivity and specificity for the detection of cochlear offset suggestive of *EYA1*-BOR was 0.476. This implies that this TAR measurement method and cutoff value can be used to suggest *EYA1* mutations in patients with a clinical diagnosis of BOR.

Furthermore, except for 1 outlier, all cochleae among the patients with *SIX1*-BOR in our cohort did not have anterior offset, with a TAR of >0.476 . In the 1 outlier that did demonstrate misaligned cochlear turns, it appeared to be due to an underlying cochlear hypoplasia (type 4) (Figs 7), distinct in morphology from the typical *EYA1*-BOR offset cochlea (Fig 1E, -F). Thus, there is a good degree of quantitative difference in cochlear turn alignment between individuals with *EYA1*-BOR and those with *SIX1*-BOR. This is in addition to morphologic differences in the apical turn of the cochlea previously demonstrated, whereby the *EYA1*-BOR cochlea appears unwound with an anterior offset, while the *SIX1*-BOR cochlea has a thorny apical turn without the characteristic anterior offset (Fig 8).⁵

Notably, in our cohort, all the individuals with BOR of an unknown underlying causative genotype had offset cochleae, with a TAR of <0.476 . In addition, they did not have thorny apical turns. On the basis of the strong phenotype-genotype correlation in patients with BOR and our current results, we speculate that all the patients with BOR in our cohort of an unknown genetic diagnosis may have *EYA1* mutations, given their anteriorly offset cochleae and lack of a thorny apical turn. This finding would be in keeping with the estimated substantially higher prevalence of *EYA1* compared with *SIX1* mutations among patients with BOR reported in the literature.¹⁶⁻¹⁹

Interestingly, all our patients with *EYA1*-BOR (TAR <0.476) had moderate-to-severe conductive hearing loss and mild-to-moderate sensorineural hearing loss. All our patients with *SIX1*-BOR without obvious cochlear dysmorphology (TAR >0.476) had mild conductive hearing loss (35–40 dB) and mild sensorineural hearing loss (25–35 dB). The 1 patient with *SIX1*-BOR with a hypoplastic cochlea had severe

conductive hearing loss and profound sensorineural hearing loss. All except one of the patients with BOR of unknown genotype had moderate-to-severe conductive hearing loss and mild-to-moderate sensorineural hearing loss, showing that most of them had hearing ability similar to that of those with the *EYA1* mutation rather than the *SIX1* mutation; this finding would be in

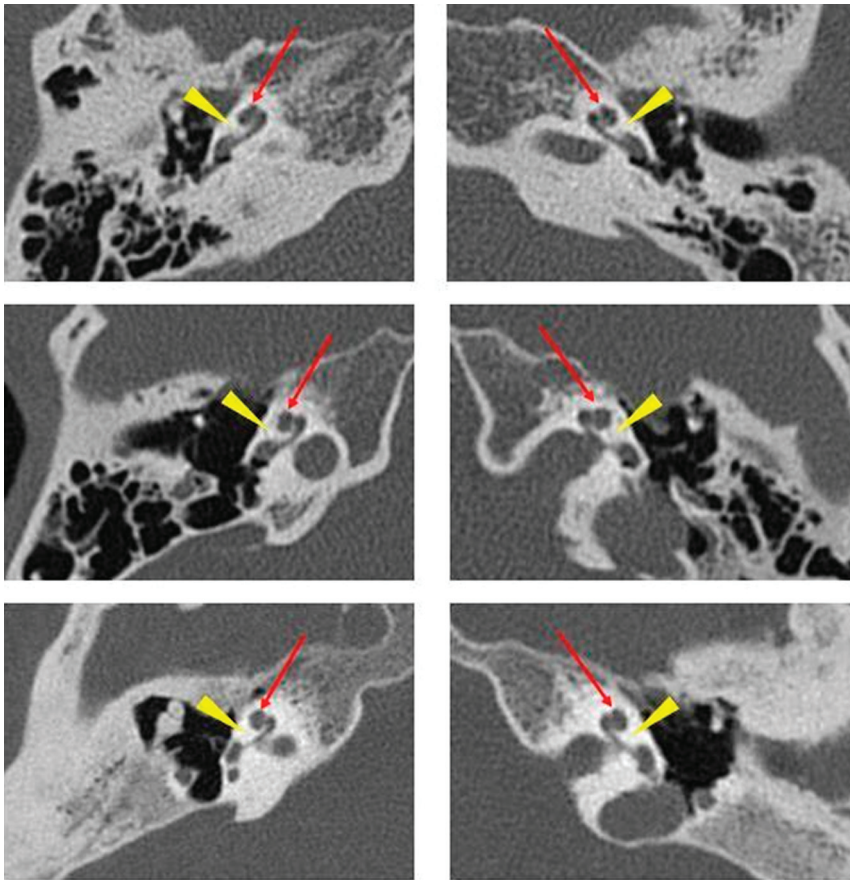


FIG 6. Axial CT images of 3 different patients with *EYA1*-BOR showing the anteriorly offset unwound cochlea, an imaging feature characteristic of *EYA1*-BOR. Notice that the middle and apical turns are anteriorly located relative to the basal turn (red arrows) and slightly tilted away and separated from the basal turn (yellow arrowheads).

Table 2: The presence/absence of thorny tips among the 3 BOR populations and in controls

	Total No. of Cochleae	No. of Cochleae with Thorny Tips
<i>EYA1</i> -BOR	32	0
<i>SIX1</i> -BOR	8	7
Unknown genotype BOR	40	0
Controls	80	0

keeping with the known estimated prevalence of these 2 genotypes among the overall BOR population.

The interactions between *SIX1* and *EYA1* protein expression during cochlear development are complex; however, we know from murine models that while *SIX1* expression is dependent on *EYA1*, *EYA1* expression is not impacted by *SIX1*. Moreover, *SIX1* is mainly expressed in the apical part of the cochlea.²⁰ This location may explain the milder alteration in cochlear phenotype associated with *SIX1* mutations compared with *EYA1* mutations. It is unclear why one of our patients with a *SIX1* mutation had the characteristic thorny cochlea on only 1 side and an anterior offset and hypoplastic cochlea on the other; it is possible that this feature is due to the particular locus of the mutated base pairs in the gene leading to different resultant disturbances in the complex *SIX1/EYA1*

interactions.²¹ Furthermore, the *SIX1* variant in this case (Cys16Tyr) is located closer toward the N-terminal (SD domain) within an α -helix critical for *EYA* interaction. More studies with larger cohorts of patients with *SIX1*-mutated BOR would be helpful to clarify whether specific mutations within the same gene can create varying and potentially characteristic phenotypes.

As expected, none of the control patients had anteriorly offset cochleae, corroborating the high sensitivity of this radiologic sign. However, there are other genetic causes of malformed cochleae with hypoplastic middle and apical turns reported in literature, such as Walker-Warburg syndrome, where the “hook” of the basal turn is the only well-preserved portion of the cochlea and the upper parts are anteriorly placed and markedly hypoplastic, resembling an extreme anteriorly offset cochlea.²² This appearance may relate to an arrest in embryonic development before the end of the seventh week of gestation, when only the first half of the basal turn is formed and the second half of the basal turn and the middle/upper turns have yet to develop and fold on themselves to create the final cochlear structure. To the best of our knowledge, at the current time, the anterior offset unwound cochlea fitting the original radiologic description^{3,5} has

been described only in *EYA1*-BOR and Walker-Warburg syndrome. However, as knowledge in genetics increases with time, it might be discovered that this offset appearance of the cochlea may be a part of the phenotypic constellation in other, rare causes and genotypes related to cochlear dysplasia.²³

Some limitations of this study are its retrospective design, different CT and MR imaging protocols among the participating institutions, and its relatively small sample size. In the future, we would benefit by prospective enrollment of patients with BOR to achieve a larger population size, preferably with known underlying genotypes, and to perform qualitative and quantitative TAR assessment in a large BOR population.

CONCLUSIONS

This study shows that there is a statistically significant difference in TAR between offset and nonoffset cochleae, with an optimal cutoff at 0.476. This is also the optimal TAR threshold value that allows excellent separation of the *EYA1*-BOR population from the *SIX1*-BOR population, and separation of patients with *EYA1*-BOR from individuals without sensorineural hearing loss. The proposed TAR measurement method and threshold value can aid any radiologist in the determination of “how offset is too

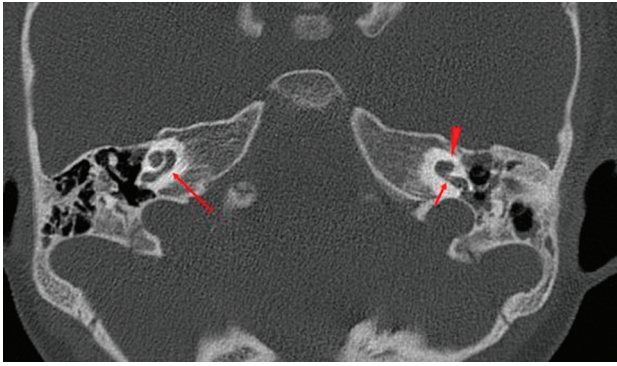


FIG 7. CT image of the patient with *SIX1*-BOR in whom the right cochlea does not demonstrate any offset (*long arrow*), while the left cochlea has an offset but with an appearance akin to cochlear hypoplasia type 4 rather than the typical unwound and offset cochlea of *EYA1*-BOR. Notice the normal size and morphology of the basal turn first half (*short arrow*), while the distal basal, middle, and apical turns are hypoplastic (*arrowhead*).

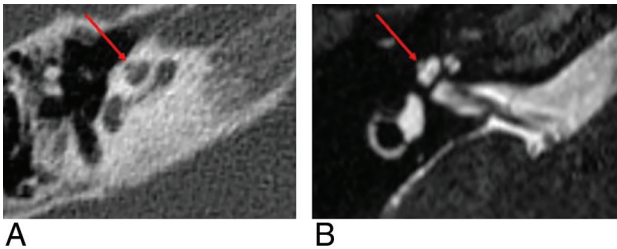


FIG 8. A thorny apical turn in a patient with *SIX1*-BOR. The apical turn of the cochlea appears as a short, protuberant, thorny tip, as seen on CT (A) and MR imaging (B).

offset”, to decide objectively whether there are anomalous offset cochleae compatible with the *EYA1*-BOR genotype-phenotype.

Disclosure forms provided by the authors are available with the full text and PDF of this article at www.ajnr.org.

REFERENCES

- Melnick M, Bixler D, Nance WE, et al. **Familial branchio-oto-renal dysplasia: a new addition to the branchial arch syndromes.** *Clin Genet* 1976;9:25–34 [CrossRef Medline](#)
- Ostri B, Johnsen T, Bergmann I. **Temporal bone findings in a family with branchio-oto-renal syndrome (BOR).** *Clin Otolaryngol Allied Sci* 1991;16:163–67 [CrossRef Medline](#)
- Robson CD. **Congenital hearing impairment.** *Pediatr Radiol* 2006;36:309–24 [CrossRef Medline](#)
- Hsu A, Desai N, Paldino MJ. **The unwound cochlea: a specific imaging marker of branchio-oto-renal syndrome.** *AJNR Am J Neuroradiol* 2018;39:2345–49 [CrossRef Medline](#)
- Pao J, D’Arco F, Clement E, et al. **Re-examining the cochlea in branchio-oto-renal syndrome: genotype-phenotype correlation.** *AJNR Am J Neuroradiol* 2022;43:309–14 [CrossRef Medline](#)
- Propst EJ, Blaser S, Gordon KA, et al. **Temporal bone findings on computed tomography imaging in branchio-oto-renal syndrome.** *Laryngoscope* 2005;115:10:1855–62 [CrossRef Medline](#)
- Smith RJ. Branchiootorenal spectrum disorder. In: Adam MP, Ardinger HH, Pagon RA eds. *GeneReviews*. University of Washington, Seattle; 1993
- Fitch N, Lindsay JR, Srolovitz H. **The temporal bone in the preauricular pit, cervical fistula, hearing loss syndrome.** *Ann Otol Rhinol Laryngol* 1976;85:268–75 [CrossRef Medline](#)
- Chen A, Francis M, Ni L, et al. **Phenotypic manifestations of branchio-oto-renal syndrome.** *Am J Med Genet* 1995;58:365–70 [CrossRef Medline](#)
- Kim N, Steele CR, Puria S. **The importance of the hook region of the cochlea for bone-conduction hearing.** *Biophys J* 2014;107:233–41 [CrossRef Medline](#)
- Atturo F, Barbara M, Rask-Andersen H. **On the anatomy of the “hook” region of the human cochlea and how it relates to cochlear implantation.** *Audiol Neurootol* 2014;19:378–85 [CrossRef Medline](#)
- Lange RT. Inter-rater reliability. In: Kreutzer JS, DeLuca J, Caplan B, eds. *Encyclopedia of Clinical Neuropsychology*. Springer; 2011:1348
- Kreutzer JS, DeLuca J, Caplan B, eds. Inter-rater agreement. In: Kreutzer JS, DeLuca J, Caplan B, eds. *Encyclopedia of Clinical Neuropsychology*. Springer; 2011:1348
- Sennaroglu L. **Histopathology of inner ear malformations: do we have enough evidence to explain pathophysiology?** *Cochlear Implants Int* 2016;17:1:3–20 [CrossRef Medline](#)
- Talenti G, Manara R, Brotto D, et al. **High-resolution 3 T magnetic resonance findings in cochlear hypoplasias and incomplete partition anomalies: a pictorial essay.** *Br J Radiol* 2018;91:20180120 [CrossRef Medline](#)
- Kochhar A, Orten DJ, Sorensen JL, et al. ***SIX1* mutation screening in 247 branchio-oto-renal syndrome families: a recurrent missense mutation associated with BOR.** *Hum Mutat* 2008;29:4:565 [CrossRef Medline](#)
- Sanggaard KM, Rendtorff ND, Kjaer KW, et al. **Branchio-oto-renal syndrome: detection of *EYA1* and *SIX1* mutations in five out of six Danish families by combining linkage, MLPA and sequencing analyses.** *Eur J Hum Genet* 2007;15:1121–31 [CrossRef Medline](#)
- Krug P, Morinière V, Marlin S, et al. **Mutation screening of the *EYA1*, *SIX1*, and *SIX5* genes in a large cohort of patients harboring branchio-oto-renal syndrome calls into question the pathogenic role of *SIX5* mutations.** *Hum Mutat* 2011;32:183–90 [CrossRef Medline](#)
- Unzaki A, Morisada N, Nozu K, et al. **Clinically diverse phenotypes and genotypes of patients with branchio-oto-renal syndrome.** *J Hum Genet* 2018;63:647–56 [CrossRef Medline](#)
- Zheng W, Huang L, Wei Z-B, et al. **The role of *SIX1* in mammalian auditory system development.** *Development* 2003;130:3989–4000 [CrossRef Medline](#)
- Chatterjee S, Kraus P, Lufkin T. **A symphony of inner ear developmental control genes.** *BMC Genet* 2010;11:68 [CrossRef Medline](#)
- Talenti G, Robson C, Severino MS, et al. **Characteristic cochlear hypoplasia in patients with Walker-Warburg syndrome: a radiologic study of the inner ear in α -Dystroglycan-related muscular disorders.** *AJNR Am J Neuroradiol* 2021;42:167–72 [CrossRef Medline](#)
- Som PM, Curtin HD, Liu K, et al. **Current embryology of the temporal bone, part I: the inner ear.** *Neurographic* 2016;6:250–65 [CrossRef](#)