

Are your **MRI contrast agents** cost-effective?

Learn more about generic **Gadolinium-Based Contrast Agents**.



**FRESENIUS
KABI**

caring for life

AJNR

**Re-Examining the Cochlea in
Branchio-Oto-Renal Syndrome:
Genotype-Phenotype Correlation**

J. Pao, F. D'Arco, E. Clement, S. Picariello, G. Moonis, C.D.
Robson and A.F. Juliano

This information is current as
of April 17, 2024.

AJNR Am J Neuroradiol 2022, 43 (2) 309-314

doi: <https://doi.org/10.3174/ajnr.A7396>

<http://www.ajnr.org/content/43/2/309>

Re-Examining the Cochlea in Branchio-Oto-Renal Syndrome: Genotype-Phenotype Correlation

J. Pao, F. D'Arco, E. Clement, S. Picariello, G. Moonis, C.D. Robson, and A.F. Juliano



ABSTRACT

BACKGROUND AND PURPOSE: Temporal bone imaging plays an important role in the work-up of branchio-oto-renal syndrome. Previous reports have suggested that the unwound or offset cochlea is a highly characteristic marker for branchio-oto-renal syndrome. Our goals were to examine the prevalence of this finding in a branchio-oto-renal syndrome cohort and analyze genetic-phenotypic associations not previously established.

MATERIALS AND METHODS: This multicenter retrospective study included 38 ears in 19 unrelated individuals with clinically diagnosed branchio-oto-renal syndrome and confirmed mutations in the *EYA1* or *SIX1* genes. Two blinded neuroradiologists independently reviewed and documented temporal bone imaging findings in 13 categories for each ear. Imaging phenotypes were correlated with genotypes.

RESULTS: There was excellent interrater agreement for all 13 phenotypic categories ($\kappa \geq 0.80$). Of these, 9 categories showed statistically significant differences between patients with *EYA1*-branchio-oto-renal syndrome and *SIX1*-branchio-oto-renal syndrome. Cochlear offset was present in 100% of patients with *EYA1*-branchio-oto-renal syndrome, but in only 1 ear (12.5%) among patients with *SIX1*-branchio-oto-renal syndrome. A short thorny appearance of the cochlear apical turn was observed in most patients with *SIX1*-branchio-oto-renal syndrome.

CONCLUSIONS: An offset cochlea is associated with the *EYA1*-branchio-oto-renal syndrome genotype. The *SIX1*-branchio-oto-renal syndrome genotype is associated with a different cochlear phenotype that almost always is without offset and has a short thorny tip as the apical turn. Therefore, cochlear offset is not a characteristic marker for all patients with branchio-oto-renal syndrome. The lack of a cochlear offset in a patient with clinically suspected branchio-oto-renal syndrome does not exclude the diagnosis and, in fact, may be predictive of the *SIX1* genotype.

ABBREVIATIONS: BOR = branchio-oto-renal syndrome; ET = Eustachian tube; IAC = internal auditory canal; LSCC = lateral semicircular canal; PSCC = posterior semicircular canal; VA = vestibular aqueduct

Branchio-oto-renal syndrome (BOR) is a common cause of congenital hearing loss, occurring in about 2% of profoundly deaf children,^{1,2} with a prevalence estimated at 1 in 40,000.¹

Melnick et al³ first described autosomally inherited familial branchio-oto-renal dysplasia in a family with hearing loss, cochlear malformation, malformed pinnae, prehelical pits, branchial

cleft fistulas, and renal dysplasia. Subsequent authors found families having similar features but variability in renal abnormalities (branchio-oto or branchio-oto-ureteral syndrome);^{1,2,4} these were attributed to variable gene penetrance.^{2,5} In 1980, Fraser et al¹ observed that not all patients with BOR had hearing loss. Anatomic studies described abnormal ossicles, hypoplastic cochlea, dysplastic semicircular canals, enlarged vestibular aqueducts (VAs), abnormal facial nerves, and bulbous internal auditory canals (IACs).⁶⁻⁸ Current diagnostic criteria are clinically based and dependent on the presence of major and minor criteria

Received August 1, 2021; accepted after revision November 2.

From the Department of Radiology (J.P.), Brigham and Women's Hospital, Harvard Medical School, Boston, Massachusetts; Department of Radiology (F.D.) and Department of Clinical Genetics (E.C.), Great Ormond Street Hospital for Children, London, UK; Department of Women, Child and General and Specialized Surgery (S.P.), University of Campania "Luigi Vanvitelli," Naples, Italy; Department of Paediatric Oncology (S.P.), Neuro-Oncology Unit, Santobono-Pausilipon Children's Hospital, Naples, Italy; Department of Radiology (G.M.), Columbia University Irving Medical Center, New York, New York; Department of Radiology (C.D.R.), Boston Children's Hospital, Harvard Medical School, Boston, Massachusetts; and Department of Radiology (A.F.J.), Massachusetts Eye and Ear, Harvard Medical School, Boston, Massachusetts.

J. Pao and F. D'Arco are co-first authors.

Please address correspondence to Amy F. Juliano, MD, Department of Radiology, Massachusetts Eye and Ear, 243 Charles St, Boston, MA 02114; e-mail: amy_juliano@meei.harvard.edu; @amyjuliano

Indicates article with online supplemental data.

<http://dx.doi.org/10.3174/ajnr.A7396>

Diagnostic criteria for BOR syndrome (Chang et al⁹)^a

Major Criteria	Minor Criteria
Branchial anomalies	External ear anomalies
Deafness	Middle ear anomalies
Preauricular pits	Inner ear anomalies
Renal anomalies	Preauricular tags
	Other: facial asymmetry, palate abnormalities

^aTo meet the criteria for BOR, an individual must meet 3 major criteria, 2 major and at least 2 minor criteria, or 1 major criterion with an affected first-degree relative who meets criteria for BOR.

(Table),⁹ including deafness and anatomic malformations of the ear, neck, and kidney as previously described.

Mutations in *EYA1* were first reported in 1997 as a genetic cause of BOR.¹⁰ Subsequently, mutations in *SIX1* were also identified in individuals with BOR. Approximately 40% of patients with BOR have mutations in the *EYA1* gene⁹ and <4% have mutations in the *SIX1* gene.¹¹ *EYA1* and *SIX1* are critical to mammalian organogenesis, including the otic vesicle. *SIX1* is a transcription factor and is reliant on the binding of EYA-family proteins at the conserved N-terminal (SIX domain) for transcription activation.^{12,13}

Large cohort studies have shown causative genetic mutations identified in only 36%–72% of clinically diagnosed individuals with BOR;^{14–16} therefore, evaluating the phenotype remains essential for diagnosis, even as genetic testing plays an increasingly important role.^{9,14,17–20}

Various temporal bone abnormalities have been described in BOR affecting the ossicles, inner ear, facial nerve course, and IAC. Cochlear malformation is common and is described as anteromedial offset of hypoplastic middle/apical turns away from a tapered basal turn.^{5,21–23} This morphologic appearance has been termed “unwound” or “offset” and has been reported to be a highly specific marker for BOR.^{23,24}

In this study, we focused on BOR genotype-phenotype associations on imaging that have not been previously established. Specifically, we examined the prevalence of the offset cochlea among patients with BOR with a known causative genotype, determined whether there are other temporal bone differences between patients with *EYA1*-BOR and *SIX1*-BOR, and described a new morphologic feature of the *SIX1*-BOR cochlea.

MATERIALS AND METHODS

Patients

This was a multicenter, retrospective review of cases of genetically confirmed BOR syndrome. Patients from 4 institutions were recruited; inclusion criteria were the following: clinical diagnosis of BOR syndrome referred from specialties including Otolaryngology and General/Pediatric Otorhinolaryngology; known causative genetic mutation associated with BOR; and diagnostic temporal bone CT and/or MR imaging available for review. This study was approved by the institutional review board/ethics committee of each institution.

Imaging Methods

All CT scanners across the participating institutions were helical multidetector CT scanners with parameters as follows: 120 kV

(peak), 100–200 mA, section thickness = 0.6–0.625 mm. All MR imaging scanners across the participating institutions were 3T, with the sequence assessed being heavily T2-weighted (driven equilibrium radiofrequency reset pulse [DRIVE; Philips], constructive interference in steady state [CISS; Siemens], or T2 sampling perfection with application-optimized contrasts by using different flip angle evolution [SPACE sequence; Siemens] depending on the vendor). Axial reformats of the temporal bones were created for both CT and MR imaging studies in a plane parallel to the lateral semicircular canal (LSCC) (or estimated as such in cases of anomalous LSCC) and coronal planes perpendicular to the true axial planes before image analyses.

Image Review

Two neuroradiologists with 5 (J.P.) and 15 (A.F.J.) years of experience reviewed all 19 cases. The reviewers were blinded to the original reports, demographics, genetic diagnosis, and the other reviewer’s findings. For each case, the following 13 parameters were assessed on the basis of existing definitions and/or descriptions in the literature:^{22,24–33}

- Cochlear offset: yes/no
- Cochlear hypoplasia: yes/no (hypoplasia defined as ≤ 4.3 mm in height in the coronal plane^{26,27})
- Apical hypoplasia: yes/no; morphology if present
- Modiolus: normal/abnormal/absent
- Cochlear fessette stenosis: <1.4 mm/ 1.4 – 1.8 mm/ >1.8 mm (fessette width measured in the axial plane spanning the inner margins of the bony edges across the base of the modiolus; stenosis was defined as <1.4 mm [in accordance with lower limits in the literature to avoid false-positives]; borderline as 1.4 – 1.8 mm; and not stenotic as >1.8 mm^{30–33})
- LSCC bone island small: yes/no (normal defined as >3 mm²⁷)
- Posterior semicircular canal (PSCC) anomalous configuration: yes/no
- VA enlargement: yes/no (when equivocal, Pöschl views were generated, and >0.9 mm at midpoint was considered enlarged²⁹)
- Facial nerve canal course medially deviated: yes/no
- Facial nerve canal widened: yes/no (widened defined as >1.42 mm²²)
- IAC widened (bulbous- or funnel-shaped): yes/no
- Eustachian tube (ET) dilated: yes/no
- Ossicular anomalies: yes/no

To accurately assess cochlear morphology, including whether there was apical hypoplasia, we took care to count the turns of the cochlea correctly. Fitch et al⁷ and Chen et al⁵ mentioned “fifths” of a cochlea, with an absent apical turn resulting in four-fifths of the cochlea remaining, designating each half turn as one-fifth of a cochlea, for a total of 2.5 turns. By means of this method, the basal turn spans the length from the round window to the medial bend (the first fifth) and then from the medial bend back laterally (second fifth), completing the basal turn. The middle turn then starts from lateral to medial (the third fifth) and then from medial back to lateral (fourth fifth). Finally, the apical turn extends from lateral to medial (last fifth) (Online Supplemental Data). The portion of the cochlea close to the round window has

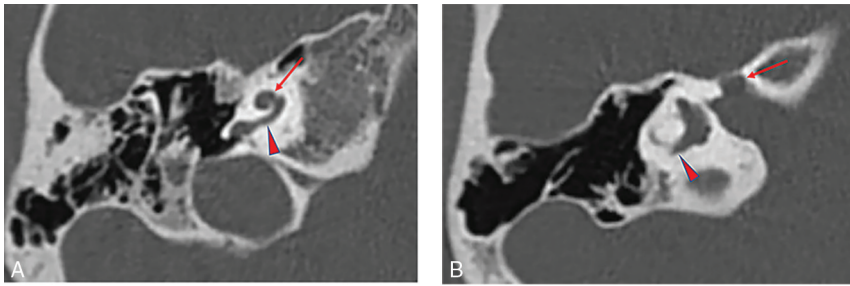


FIG 1. Temporal bone imaging appearance in a patient with *EYA1*-BOR. *A*, Axial CT image in bone algorithm shows an offset cochlea; the middle turn (arrow) is aligned more anteromedially than usual relative to the basal turn (arrowhead). The cochlea is, overall, small with a hypoplastic apical turn. *B*, Axial CT image in bone algorithm at a more superior level shows a medialized and widened labyrinthine facial nerve canal (arrow). The PSCC is anomalous, appearing as a blind-ending tubular structure (arrowhead).

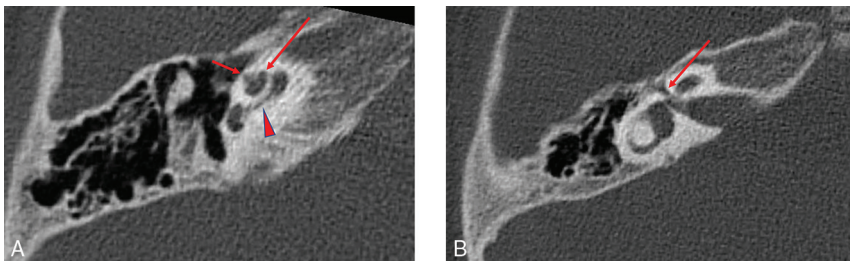


FIG 2. Temporal bone imaging appearance in a patient with *SIX1*-BOR. *A*, Axial CT image in bone algorithm shows absence of the cochlear offset; the middle turn (long arrow) is normally aligned relative to the basal turn (arrowhead) without anteromedial displacement. The thorny apical turn can also be appreciated (short arrow). *B*, Axial CT image in bone algorithm at a more superior level shows a normal course of the labyrinthine facial nerve canal (arrow) without medialization or widening.

a bulbous configuration that contributes to the outward convex shape of the cochlear promontory. It contains the most basal part of the cochlear duct and the cul-de-sac of the endolymphatic space where the osseous spiral lamina, spiral ligament, and basilar membrane merge. This portion of the cochlea forms a “three-dimensional (3D) ‘fish-hook’-like shape”^{34–36} and has been referred to as the “hook region” (Online Supplemental Data).^{37,38} The hook region extends from the edge of the vestibule and round window to the point where the cochlea begins to coil. For consistency during image assessment, we considered the hook region of the cochlea as part of the basal turn and thus part of the first fifth.

When there was a disagreement between the 2 reviewers, consensus reading (blinded to genotype) was performed.

Statistical Analysis

Comparison among group demographics was made with the Mann-Whitney *U* test for continuous nonparametric variables. A Cohen weighted κ statistic was calculated to assess interrater reliability for each phenotypic parameter and categorized as poor (<0.2), fair (0.20–0.39), moderate (0.40–0.59), good (0.60–0.79), or excellent (≥ 0.80). Differences between the *EYA1*-BOR and *SIX1*-BOR groups for each parameter were assessed using the Fisher exact test. $P = .05$ was set as the threshold of significance.

Statistical analyses were performed using SAS Studio, Version 3.8 (SAS Institute).

RESULTS

Nineteen unrelated individuals (38 ears) met the inclusion criteria; 15 individuals (30 ears) had mutations in the *EYA1* gene, and 4 individuals (8 ears) had mutations in the *SIX1* gene.

Of the 19 patients, 14 underwent CT and 5 underwent MR imaging. Among the *EYA1* genotype population, there were 11 males and 4 females, with a median age of 4.5 years (range, 2 months to 26 years). Among the *SIX1* genotype population, there were 3 males and 1 female, with a median age of 4 years (range, 3 months to 13 years). There were no statistically significant differences in age and sex among the groups.

Thirteen phenotypic parameters were examined for each ear. Results recorded by the 2 raters showed excellent interrater reliability ($\kappa \geq 0.80$). A few discrepancies were limited to qualitative assessments, including determination of modiolar structure, VA enlargement, facial nerve canal course, IAC width, and ET dilation. Notably, perfect observer agreement was seen for the quantifiable phenotypes, including assessment of the cochlear offset.

Differences in temporal bone features between patients with *EYA1*-BOR and *SIX1*-BOR reached statistical significance ($P < .05$) in 9 of 13 structures evaluated: cochlear offset, cochlear hypoplasia, apical turn hypoplasia, modiolar abnormality, VA enlargement, labyrinthine facial nerve canal medialization, IAC widening, ET dilation, and ossicular abnormalities (Online Supplemental Data). Of these, the structural feature that was most divergent between the 2 patient populations was cochlear offset, which was present in 100% of patients with *EYA1*-BOR and in only 1 ear among the patients with *SIX1*-BOR. This *SIX1*-BOR ear had an offset cochlea that did not resemble the offset cochleae seen among the *EYA1*-BOR population, including absence of basal turn tapering. The *EYA1*-BOR phenotype in our sample population was characterized by having cochlear offset, cochlear hypoplasia, apical turn hypoplasia, abnormal modiolus, VA enlargement, medialization of the facial nerve course, widening of the IAC, ET dilation, and ossicular anomalies (Fig 1). Individuals with *SIX1* mutations were significantly less likely to have these phenotypic anomalies (Fig 2). Cochlear fossate stenosis, a small LSCC bone island, PSCC anomaly, and facial nerve canal widening were less prevalent in the *SIX1*-BOR group but did not reach a statistically significant difference compared with the *EYA1*-BOR group ($P > .05$). The Online Supplemental Data summarize the findings.

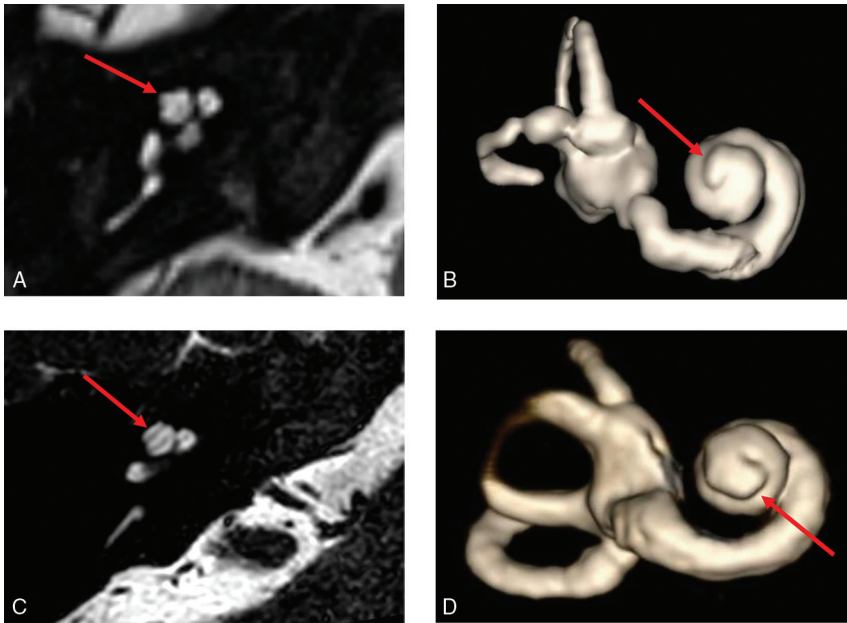


FIG 3. Thorny apical turn of the *SIX1*-BOR cochlea. Axial heavily T2-weighted MR image (A) and 3D reconstruction of the cochlea (B) show a short, thin, protuberant projection forming the apical turn, imparting upon it a thorny morphology (arrows in A and B). Contrast it with the normal apical turn morphology in a patient with normal hearing and no history of BOR or sensorineural hearing loss (C and D), which is longer with a smooth flat appearance and rounded end (arrows in C and D).

Among the *SIX1*-BOR group, the 1 ear with cochlear offset did not have an apical turn, and 2 ears (in 1 patient) did not allow detailed apical turn morphology assessment due to the spatial resolution of MR imaging in that study. In the remaining 5 ears, all had a distinct short protuberant appearance to the cochlear apical turn reminiscent of a poking thorn, which we termed a “thorny” apical turn (Fig 3).

DISCUSSION

In our assessment of 19 patients with BOR, the classic unwound or offset cochlea was seen among all those with the *EYA1* mutation but in only 1 ear among those with the *SIX1* mutation. Notably, however, this cochlea did not have the typical appearance of the *EYA1*-BOR offset cochlea with a tapered basal turn but rather had features more closely resembling a cochlear hypoplasia type 4 (CH4) anomaly.³⁹ In addition, the *SIX1* genotype did not demonstrate most of the other previously described cochlear anomalies nor additional temporal bone findings such as VA enlargement, medially displaced labyrinthine facial nerve, widened IAC, ET dilation, and ossicular anomalies.^{5,21,22,40} Furthermore, most with the *SIX1*-BOR genotype had a characteristic short protuberant thorny apical turn, a feature not seen among the *EYA1*-BOR genotype population. This finding suggests distinct genotype-phenotype differences within BOR syndrome with regard to the temporal bone.

EYA1 was the first gene identified to cause BOR syndrome.⁴¹⁻⁴⁴ It plays a role in the development of the inner ear and surrounding mesenchyme, as well as metanephric cells surrounding ureteric

branches in renal development.⁴⁵ In 2004, Chang et al⁹ analyzed phenotypic data from families with *EYA1* mutations and proposed criteria for clinical diagnosis, ushering in the modern diagnostic criteria for BOR (Table). In 2005, Propst et al²² described temporal bone CT findings in 13 families with BOR syndrome diagnosed on the basis of the criteria of Chang et al. In 2006, the term “offset” was coined by Robson²³ to describe “tapering of the basal turn of the cochlea,” and “small middle and apical turns that are offset anteriorly and appear separated from the basal turn” and deemed “characteristic of BOR syndrome.” Of note, many of these descriptions were made when *EYA1* was the sole known gene for BOR syndrome.

However, in 2003 and 2004, Ruf et al^{17,18} identified a second gene locus that mapped to human chromosome 14q23.1, where the *SIX1*, *SIX4*, and *SIX6* genes reside. Three different *SIX1* mutations were identified in 4 BOR/branchio-oto (BO) kindreds. Thus, *SIX1* became a second known gene that can be associated with BOR syndrome. Sanggaard et al¹⁹ discovered a low frequency (25%) of branchial arch malformation and the absence of renal pathology among patients with BOR with *SIX1* mutations, and there was one patient with no temporal bone malformation. They suggested that there may be clinical differences in patients with BOR with *EYA1* and *SIX1* mutations. Genotype-phenotype correlation studies are, therefore, of much interest.

We discovered different temporal bone phenotypes: The *SIX1* genotype did not show the classic temporal bone anomalies described in the radiology literature for BOR syndrome. In particular, the unwound or offset cochlea was observed in all individuals in our cohort with the *EYA1* genotype but in almost none with the *SIX1* genotype, showing instead a short, protuberant, thorny apical turn.

Mammalian inner ear development is a complex process dependent on the interaction of many genes. Studies in mouse models showed that during embryologic development, *EYA1* and *SIX1* are both expressed in the ventral part of the otic vesicle from which the cochlear structures are derived.⁴⁶ Most important, expression of *SIX1* in the otic vesicle is dependent on *EYA1*, whereas the expression of *EYA1* is unaffected in *SIX1* murine knockout models.⁴⁷ This finding may explain why the cochlear phenotype in patients with *EYA1*-BOR is more severe than in patients with *SIX1*-BOR. It is of interest that the expression of *SIX1* in the mammalian inner ear is more prominent in the apex of the cochlea than in the base.⁴⁷ This feature may have relevance to the finding of a thorny apical turn in our cohort with the *SIX1* genotype, but further work is needed to understand this issue.

Regarding the 1 case with a unilateral cochlear abnormality with features of CH4, it is unclear whether these features are within the wider spectrum of the *SIX1* phenotype or if there is a secondary explanation. The *SIX1* variant in this case (Cys16Tyr) is notable for its location toward the N-terminal (SIX domain) within an α helix critical for EYA interaction. Although this variant has not been reported before in the literature, a variant at the adjacent amino acid residue (V17E/Val17Glu) has been the subject of functional work. Patrick et al^{12,48} studied the effect of a number of *SIX1* variants on the EYA-SIX1-DNA complex and concluded that *SIX1*-BOR mutations contributed to the disease pathology through at least 2 different mechanisms: In most cases (all C-terminal to this mutation and not in the α helix), the mechanism appeared to be related to diminished ability of SIX1 to bind DNA; another mechanism was seen in a case of the V17E mutation, in which formation of the SIX1-EYA complex was completely abolished and nuclear localization of the complex was not observed. This mechanism was not seen in any of the other *SIX1*-BOR mutations modeled.

Therefore, one theory to account for the unilateral cochlear abnormality in our *SIX1* Cys16Tyr variant is that mutations in the α helical domain are functionally distinct and may lead to a different *SIX1* inner ear phenotype. Of note, an unaffected sibling (*SIX1* genetic analysis normal) of this proband had several ear tags, so it may be that there are secondary genetic modifying factors impacting the clinical presentation; *EYA1* was also fully sequenced, and multiplex ligation-dependent probe amplification was undertaken in the proband with negative findings. Unfortunately, clinical data reported for the V17E case were limited and did not include imaging,¹¹ and the number of reported *SIX1*-BOR cases in the literature overall remains small. It is difficult to draw any firm conclusions from this specific case, but functional studies of the Cys16Tyr *SIX1* variant and further imaging in *SIX1* cases, particularly those involving the α helix, may help resolve this issue.

Some limitations of this study include its retrospective nature, different CT/MR imaging protocols, and its relatively small sample size. In the future, we would benefit from a prospective clinico-radiologic study involving all organ systems involved in BOR syndrome for precise genotype-phenotype correlation.

CONCLUSIONS

We found a significant difference between the BOR *EYA1* and *SIX1* genotype-phenotypes in the temporal bone. The *SIX1* phenotype is associated with a lack of cochlear offset, a thorny apical turn, as well as a relative absence of many other previously reported temporal bone anomalies. This shows that cochlear offset is not a characteristic feature nor a reliable indicator for all BOR cases; specifically, it is seen with the BOR *EYA1* genotype but is not sensitive nor specific for the detection of the BOR *SIX1* genotype. Thus, the lack of cochlear offset on imaging does not exclude the diagnosis of BOR and, in fact, may be predictive of the *SIX1* genotype in an individual with clinically suspected BOR. Careful radiologic delineation of the temporal bone and inner ear structures has the potential to help establish specific and sensitive features to aid in multidisciplinary genomic variant interpretation in suspected cases of BOR.

ACKNOWLEDGMENTS

We would like to thank Julia Wei, MPH, for statistical consultation, and Stephen Kovach, RT, for assistance with 3D modeling and construction.

Disclosure forms provided by the authors are available with the full text and PDF of this article at www.ajnr.org.

REFERENCES

1. Fraser FC, Sproule JR, Halal F. Frequency of the branchio-oto-renal (BOR) syndrome in children with profound hearing loss. *Am J Med Genet* 1980;7:341–49 [CrossRef Medline](#)
2. Heimler A, Lieber E. Branchio-oto-renal syndrome: reduced penetrance and variable expressivity in four generations of a large kindred. *Am J Med Genet* 1986;25:15–27 [CrossRef Medline](#)
3. Melnick M, Bixler D, Silk K, et al. Autosomal dominant branchio-otorenal dysplasia. *Birth Defects Orig Artic Ser* 1975;115:121–28 [Medline](#)
4. Melnick M, Bixler D, Nance WE, et al. Familial branchio-oto-renal dysplasia: a new addition to the branchial arch syndromes. *Clin Genet* 1976;9:25–34 [CrossRef Medline](#)
5. Chen A, Francis M, Ni L, et al. Phenotypic manifestations of branchio-oto-renal syndrome. *Am J Med Genet* 1995;58:365–70 [CrossRef Medline](#)
6. Fraser FC, Ling D, Clogg D, et al. Genetic aspects of the BOR syndrome—branchial fistulas, ear pits, hearing loss, and renal anomalies. *Am J Med Genet* 1978;2:241–52 [CrossRef Medline](#)
7. Fitch N, Lindsay JR, Srolovitz H. The temporal bone in the preauricular pit, cervical fistula, hearing loss syndrome. *Ann Otol Rhinol Laryngol* 1976;85(2 Pt1):268–75 [CrossRef Medline](#)
8. Ng YY, Bellman S, Phelps PD. Computed tomography of earpits-deafness syndrome. *Br J Radiol* 1989;62:947–49 [CrossRef Medline](#)
9. Chang EH, Menezes M, Meyer NC, et al. Branchio-oto-renal syndrome: the mutation spectrum in *EYA1* and its phenotypic consequences. *Hum Mutat* 2004;23:582–89 [CrossRef Medline](#)
10. Abdelhak S, Kalatzis V, Heilig R, et al. A human homologue of the *Drosophila* eyes absent gene underlies branchio-oto-renal (BOR) syndrome and identifies a novel gene family. *Nat Genet* 1997;15:157–64 [CrossRef Medline](#)
11. Kochhar A, Orten DJ, Sorensen JL, et al. *SIX1* mutation screening in 247 branchio-oto-renal syndrome families: a recurrent missense mutation associated with BOR. *Hum Mutat* 2008;29:565 [CrossRef Medline](#)
12. Patrick AN, Cabrera JH, Smith AL, et al. Structure-function analyses of the human *SIX1*-*EYA2* complex reveal insights into metastasis and BOR syndrome. *Nat Struct Mol Biol* 2013;20:447–53 [CrossRef Medline](#)
13. Li X, Oghi KA, Zhang J, et al. Eya protein phosphatase activity regulates Six1-Dach-Eya transcriptional effects in mammalian organogenesis. *Nature* 2003;426:247–54 [CrossRef Medline](#)
14. Krug P, Morinière V, Marlin S, et al. Mutation screening of the *EYA1*, *SIX1*, and *SIX5* genes in a large cohort of patients harboring branchio-oto-renal syndrome calls into question the pathogenic role of *SIX5* mutations. *Hum Mutat* 2011;32:183–90 [CrossRef Medline](#)
15. Morisada N, Nozu K, Iijima K. Branchio-oto-renal syndrome: comprehensive review based on nationwide surveillance in Japan. *Pediatr Int* 2014;56:309–14 [CrossRef Medline](#)
16. Unzaki A, Morisada N, Nozu K, et al. Clinically diverse phenotypes and genotypes of patients with branchio-oto-renal syndrome. *J Hum Genet* 2018;63:647–56 [CrossRef Medline](#)
17. Ruf RG, Berkman J, Wolf MT, et al. A gene locus for branchio-otic syndrome maps to chromosome 14q21.3-q24.3. *J Med Genet* 2003;40:515–19 [CrossRef Medline](#)

18. Ruf RG, Xu PX, Silvius D, et al. **SIX1 mutations cause branchio-oto-renal syndrome by disruption of EYA1-SIX1-DNA complexes.** *Proc Natl Acad Sci U S A* 2004;101:8090–95 [CrossRef Medline](#)
19. Sanggaard KM, Rendtorff ND, Kjaer KW, et al. **Branchio-oto-renal syndrome: detection of EYA1 and SIX1 mutations in five out of six Danish families by combining linkage, MLPA and sequencing analyses.** *Eur J Hum Genet* 2007;15:1121–31 [CrossRef Medline](#)
20. Hoskins BE, Cramer CH, Silvius D, et al. **Transcription factor SIX5 is mutated in patients with branchio-oto-renal syndrome.** *Am J Hum Genet* 2007;80:800–04 [CrossRef Medline](#)
21. Ceruti S, Stinckens C, Cremers CW, et al. **Temporal bone anomalies in the branchio-oto-renal syndrome: detailed computed tomographic and magnetic resonance imaging findings.** *Otol Neurotol* 2002;23:200–07 [CrossRef Medline](#)
22. Propst EJ, Blaser S, Gordon KA, et al. **Temporal bone findings on computed tomography imaging in branchio-oto-renal syndrome.** *Laryngoscope* 2005;115:1855–62 [CrossRef Medline](#)
23. Robson CD. **Congenital hearing impairment.** *Pediatr Radiol* 2006;36:309–24 [CrossRef Medline](#)
24. Hsu A, Desai N, Paldino MJ. **The unwound cochlea: a specific imaging marker of branchio-oto-renal syndrome.** *AJNR Am J Neuroradiol* 2018;39:2345–49 [CrossRef Medline](#)
25. Purcell D, Johnson J, Fischbein N, et al. **Establishment of normative cochlear and vestibular measurements to aid in the diagnosis of inner ear malformations.** *Otolaryngol Head Neck Surg* 2003;128:78–87 [CrossRef Medline](#)
26. Shim HJ, Shin JE, Chung JW, et al. **Inner ear anomalies in cochlear implantees: importance of radiologic measurements in the classification.** *Otol Neurotol* 2006;27:831–37 [CrossRef Medline](#)
27. D'Arco F, Talenti G, Lakshmanan R, et al. **Do measurements of inner ear structures help in the diagnosis of inner ear malformations? A review of literature.** *Oto Neurotol* 2017;38:e384–92 [CrossRef Medline](#)
28. Naganawa S, Koshikawa T, Iwayama E, et al. **MR imaging of the enlarged endolymphatic duct and sac syndrome by use of a 3D fast asymmetric spin-echo sequence: volume and signal-intensity measurement of the endolymphatic duct and sac and area measurement of the cochlear modiolum.** *AJNR Am J Neuroradiol* 2000;219:1664–69 [Medline](#)
29. Juliano AF, Ting EY, Mingkwansook V, et al. **Vestibular aqueduct measurements in the 45° oblique (Pöschl) plane.** *AJNR Am J Neuroradiol* 2016;37:1331–37 [CrossRef Medline](#)
30. Adunka OF, Jewells V, Buchman CA. **Value of computed tomography in the evaluation of children with cochlear nerve deficiency.** *Otol Neurotol* 2007;28:597–604 [CrossRef Medline](#)
31. Wilkins A, Prabhu SP, Huang L, et al. **Frequent association of cochlear nerve canal stenosis with pediatric sensorineural hearing loss.** *Arch Otolaryngol Head Neck Surg* 2012;138:383–88 [CrossRef Medline](#)
32. Stjernholm C, Muren C. **Dimensions of the cochlear nerve canal: a radioanatomic investigation.** *Acta Otolaryngol* 2002;122:43–48 [CrossRef Medline](#)
33. Henderson E, Wilkins A, Huang L, et al. **Histopathologic investigation of the dimensions of the cochlear nerve canal in normal temporal bones.** *Int J Pediatr Otorhinolaryngol* 2011;75:464–67 [CrossRef Medline](#)
34. Stidham KR, Roberson JB Jr. **Cochlear hook anatomy: evaluation of the spatial relationship of the basal cochlear duct to middle ear landmarks.** *Acta Otolaryngol* 1999;119:773–77 [CrossRef Medline](#)
35. Li PM, Wang H, Northrop C, et al. **Anatomy of the round window and hook region of the cochlea with implications for cochlear implantation and other endocochlear surgical procedures.** *Otol Neurotol* 2007;28:641–48 [CrossRef Medline](#)
36. Schart-Morén N, Agrawal SK, Ladak HM, et al. **Effects of various trajectories on tissue preservation in cochlear implant surgery: a micro-computed tomography and synchrotron radiation phase-contrast imaging study.** *Ear Hear* 2019;40:393–400 [CrossRef Medline](#)
37. Kim N, Steele CR, Puria S. **The importance of the hook region of the cochlea for bone-conduction hearing.** *Biophys J* 2014;107:233–41 [CrossRef Medline](#)
38. Atturo F, Barbara M, Rask-Andersen H. **On the anatomy of the “hook” region of the human cochlea and how it relates to cochlear implantation.** *Audiol Neurootol* 2014;19:378–85 [CrossRef Medline](#)
39. Talenti G, Manara R, Brotto D, et al. **High-resolution 3 T magnetic resonance findings in cochlear hypoplasias and incomplete partition anomalies: a pictorial essay.** *Br J Radiol* 2018;91:20180120 [CrossRef Medline](#)
40. Hsu TR, Niu DM. **Fabry disease: review and experience during newborn screening.** *Trends Cardiovasc Med* 2018;28:274–81 [CrossRef Medline](#)
41. Smith RJ, Coppage KB, Ankerstjerne JK, et al. **Localization of the gene for branchiootorenal syndrome to chromosome 8q.** *Genomics* 1992;14:841–44 [CrossRef Medline](#)
42. König R, Fuchs S, Dukiet C. **Branchio-oto-renal (BOR) syndrome: variable expressivity in a five-generation pedigree.** *Eur J Pediatr* 1994;153:446–50 [CrossRef Medline](#)
43. Ni L, Wagner MJ, Kimberling WJ, et al. **Refined localization of the branchiootorenal syndrome gene by linkage and haplotype analysis.** *Am J Med Genet* 1994;51:176–84 [CrossRef Medline](#)
44. Wang Y, Treat K, Schroer RJ, et al. **Localization of branchio-oto-renal (BOR) syndrome to a 3 Mb region of chromosome 8q.** *Am J Med Genet* 1994;51:169–75 [CrossRef Medline](#)
45. Mackowetzky K, Yoon KH, Mackowetzky EJ, et al. **Development and evolution of the vestibular apparatuses of the inner ear.** *J Anat* 2021;239:801–28 [CrossRef Medline](#)
46. Chatterjee S, Kraus P, Lufkin T. **A symphony of inner ear developmental control genes.** *BMC Genet* 2010;11:68 [CrossRef Medline](#)
47. Zheng W, Huang L, Wei Z-B, et al. **The role of Six1 in mammalian auditory system development.** *Development* 2003;130:3989–4000 [CrossRef Medline](#)
48. Patrick AN, Schiemann BJ, Yang K, et al. **Biochemical and functional characterization of six SIX1 branchio-oto-renal syndrome mutations.** *J Biol Chem* 2009;284:20781–90 [CrossRef Medline](#)